

Two cases of Kawasaki disease following pneumonia

Hyun Jung Kim, M.D. and Soo Jin Lee, M.D.

Departments of Pediatrics, College of Medicine, Eulji University, Daejeon, Korea

= Abstract =

Kawasaki disease (KD) causes multisystemic vasculitis but rarely manifests with pulmonary symptoms. As its etiology is still unknown, there are no specific diagnostic tools available, and KD can be diagnosed only by the symptom pattern. The presence of unusual clinical manifestations often leads to delayed diagnosis. Here, we report two cases of KD with an initial presentation of pneumonia. KD should be considered when there is a prolonged inflammatory reaction and progressive pneumonia unresponsive to antibiotics. (*Korean J Pediatr* 2009;52:615-618)

Key Words : Mucocutaneous Lymph Node Syndrome, Pneumonia

Introduction

Kawasaki disease (KD) causes severe vasculitis of all blood vessels but predominantly affects the medium-sized arteries, with a striking predilection for the coronary arteries. There are a few English reports on KD with pneumonia since 2002 by Uziel et al¹⁾. There has been one Korean report published concerning retrospective findings of abnormal chest radiograph in KD²⁾. However, these pulmonary symptoms are rarely present in KD. Therefore when present with those symptoms, it is more difficult to diagnose KD, and usually the diagnosis is delayed. Since the diagnosis of KD is based mainly on clinical findings, the pediatrician treating a child with prolonged fever without typical signs of KD needs an increased degree of suspicion for this diagnosis.

Here, we present two cases of young children with lobar consolidation as the main presenting symptom of KD. The patients were initially diagnosed as having pneumonia but were later identified to have KD.

Case report

Case 1

A previously healthy girl of 18 months old suffered from intermittent fever up to 39.5–40°C for about 5 days and a conjunctival injection 1 day prior to admission. There were no respiratory symptoms or signs. A physical examination upon admission revealed bilateral conjunctival injection and several slightly enlarged cervical nodes. The largest node, measuring 2×2 cm, was in the right posterior triangle of neck. Breath sounds were coarse without crackles, and no cardiac murmur was audible. Initial laboratory results were as follows : erythrocyte sedimentation rate (ESR) 25 mm/h, haemoglobin 10.6 g/dL, white blood cell (WBC) count 13,410/μL (segment 62%, lymphocytes 27%, monocytes 5%), platelet count 332×10³/μL, C-reactive protein (CRP) 14.96 mg/dL. Chest roentgenogram (CXR) (Fig. 1A) revealed patchy consolidation on the right upper lobe and perihilar area. She was treated with antibiotics, including amoxicillin clavulanate and clarithromycin, but the fever persisted.

On hospital day 2, she developed cough. On hospital day 3, laboratory results were as follows : ESR 125 mm/h, haemoglobin 9.8 g/dL, WBC count 12,770/μL with a polymorphonuclear cell predominance, platelets 325×10³/μL, CRP 17.52 mg/dL, and urine sediment revealed 12–29 WBCs in a high powered field. CXR revealed more increased extent of dense consolidation on the right lower lobe (Fig. 1B). Echocardiography showed mild dilation of left main coronary arteries with trivial mitral regurgitation. A diagnosis of KD

Received : 3 December 2008, Revised : 18 February 2009

Accepted : 13 March 2009

Address for correspondence : Soo Jin Lee, M.D.

Departments of Pediatrics, Eulji University Hospital, 1306, Dunsan-dong, Seo-gu, Daejeon 302-799, Korea

Tel : +82.42-611-3356, Fax : +82.42-611-3353

E-mail : sjlee@eulji.ac.kr

was then established. She was treated with intravenous immunoglobulin (IVIG) (2 g/kg) and aspirin (80 mg/kg/day). The fever eventually subsided and a follow up CXR was improved.

Case 2

A previously healthy girl of 4 years old was hospitalized due to a 3-day history of fever and cough. Breath sounds were clear without crackles, and no cardiac murmur was audible. There were no other abnormal findings on physical examination. Initial laboratory results were as follows : ESR 22 mm/h, haemoglobin 12.5 g/dL, WBC count 23,510/ μ L (segment 85%, lymphocytes 9%, monocytes 4%), platelet count 311×10^3 / μ L, CRP 29.64 mg/dL. CXR (Fig. 2A) revealed increased lung markings on the right perihilar area. She was treated with antibiotics, including amoxicillin clavulanate and clarithromycin, but the fever persisted. On hospital day

4, CXR revealed more increased extent of pneumonic consolidation on the right upper lobe and perihilar area. We changed antibiotics to ceftriaxone. On hospital day 7, she suffered sustained high grade fever and developed conjunctival injection without discharge, strawberry tongue, red swollen palms of the hands and the soles of the feet and swollen lymph nodes in the neck area. laboratory results were as follows : ESR 116 mm/h, haemoglobin 9.7 g/L, WBC count 12,050/ μ L with a polymorphonuclear cell predominance, platelets 438×10^3 / μ L, and CRP 12.97 mg/dL. CXR (Fig. 2B) revealed more increased extent of dense consolidation on the right upper lobe. Echocardiography performed on the 10th day of disease revealed dilation of left ventricle with mitral regurgitation. Additionally a dilated left anterior descending artery (maximum diameter, 3.3 mm) was observed. A diagnosis of KD was then established. She was treated with IVIG (2 g/kg) and aspirin (80 mg/kg/day). The fever eventually

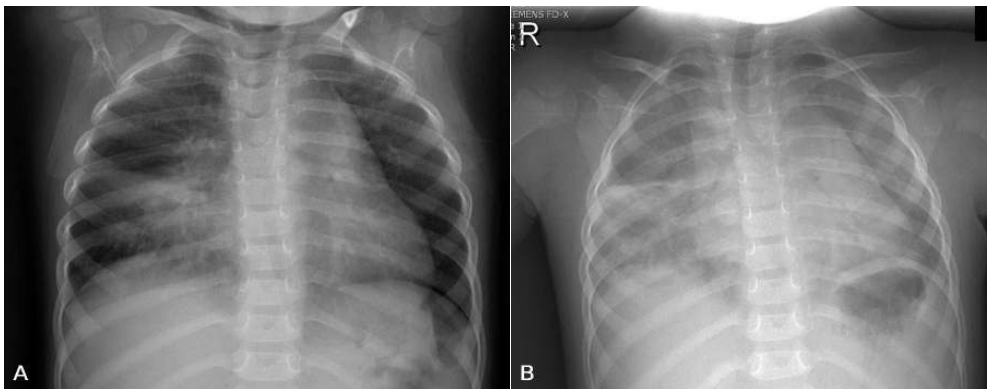


Fig. 1. (A) Chest roentgenogram (CXR) on the day of admission showed patchy consolidation on the right upper lobe and perihilar area. (B) CXR on hospital day 3 showed more increased extent of dense consolidation on the right lower lobe.

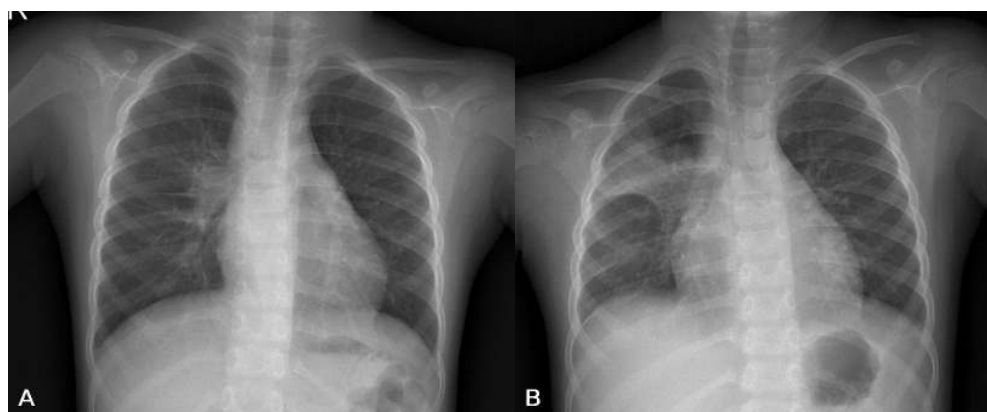


Fig. 2. (A) Chest roentgenogram (CXR) on the day of admission showed increased lung markings on the right perihilar area. (B) CXR on hospital day 7 showed more increased extent of dense consolidation on the right upper lobe.

subsided and a follow up CXR was improved.

Discussion

We have described two cases of KD manifested as persistent lung consolidation, prolonged fever, and active inflammatory laboratory markers unresponsive to antibiotic treatment. Retrospectively the girl of case 1 fulfilled all criteria of typical KD in the course of the illness and second case was compatible with incomplete KD. It is remarkable that the pulmonary diseases were most prominent and the CRP level was moderately elevated, with a normal white blood cell count in our cases.

Atypical KD is associated with an increased risk of coronary artery abnormalities (CAA)³. Early diagnosis and initiation of IVIG therapy is essential in significantly reducing the risk. Two children developed coronary artery dilatation during acute stage of disease but follow-up echocardiograms were normal.

Our cases indicate that prominent pulmonary signs and symptoms may be misinterpreted as pneumonia in children with KD. Lung involvement in KD is uncommon but on autopsy, interstitial pneumonia was recognized in 30 to 90% of all cases with KD⁴. The prevalence of respiratory signs such as tachypnea, dyspnea, cough or coryza in the context of KD is described to be higher in infants younger than 6 months of age⁵, however, our two patients are not included in extreme age. Sengler et al⁶ reported an 8-week-old girl presented with fever, increasing cough and tachypnea, interstitial pneumonia on radiograph. The infant was treated with antibiotics but readmitted to the hospital on day 36 and echocardiography showed a dilated aortic root and multiple aneurysms of the left coronary artery. In a series of 129 patients with KD, 14.7% had abnormal CXR findings⁷. Reticulogranular pattern was the most frequent abnormality (89.5%), while peribronchial cuffing (21.1%), pleural effusion (15.8%), atelectasis (10.5%) and air trapping (5.3%) were also seen. This feature was correlated with a more severe course of the disease, measured by clinical and laboratory findings. However, a recent Korean report described that peribronchial cuffing was the most frequent abnormalities (22.4%) and the abnormal CXR findings in KD patients did not mean severe inflammation². Further study on the relationship between CXR findings and severity of inflammation of KD or the degree of coronary artery dilatation is needed.

The pulmonary involvement in KD may be due to in-

creased vascular permeability as occurs in other vasculitis. Yasukawa and other colleagues⁸ recently reported that vascular endothelial growth factor (VEGF) and its receptors were increased in the blood vessels of KD patients, and led to perivascular edematous changes. VEGF, heparin-binding glycoprotein is also mitogenic and angiogenic for endothelial cells. This systemic effect probably happened in the patients' lungs. Recently Managoli et al⁹ have reported an 18-month-old girl with interstitial pneumonia in addition to coronary artery aneurysms. A recent report described a 6-year-old girl with interstitial lung disease and pleural effusion associated with complete KD, in that case, a mild transient dilatation of the right coronary artery was seen¹⁰. Voynow and other colleagues¹¹ described a 6-year-old girl who developed dyspnea with lowered O₂ saturation, bibasilar interstitial lung disease and pleural effusion on radiograph during course of KD. Above-mentioned cases were associated with interstitial lung disease in CXR. In this study, the first case, 18 months old girl presented with lobar pneumonia initially. Misdiagnosis can be made if unusual complications of KD precede the classic signs.

The etiology of KD is unclear, but superantigen may play a part¹²⁻¹⁴. They postulate that the development KD after mycoplasma infection may have been due to the production of superantigen by the mycoplasma organism¹⁴. However, the titer of *Mycoplasma pneumoniae* antibody in an agglutination test was negative in our two patients. Epidemiologic case-control studies on KD outbreaks in Rochester, NY, Massachusetts and Hawaii revealed an association of KD with a history of antecedent respiratory tract infection¹⁵⁻¹⁷. Recent report has suggested that KD is caused by a previously unidentified respiratory infectious agent, which infects ciliated bronchial epithelium and macrophages¹⁸. In our cases, whether KD follows pneumonia or pulmonary complications occurs during illness cannot be confirmed. However, taken together, epidemiologic and clinical findings suggest a respiratory portal of entry of the etiologic agent of KD. The relationship between KD and a respiratory virus is supported epidemiologically by a consistent seasonal pattern with sharp peaks and falls of incidence, although virologic and immunologic data are lacking¹⁹. A recent study reporting increased IgA plasma cell infiltration of upper respiratory tract and coronary arteries of KD patients supports the respiratory route as potential portal of entry for the agent causing KD²⁰. In addition, further study on the relationship between etiology of pneumonia and KD is needed.

In the 2 cases described here, the pulmonary symptoms were misleading because of their predominance in the course of the disease; additionally the abnormalities of chest radiographs were compatible with pneumonia as the cause of illness.

In conclusion, KD may be initially misdiagnosed as pneumonia. When there is a prolonged inflammatory reaction and no infectious agent identified or remittent fever unresponsive to antibiotics, KD should be taken into consideration.

한 글 요약

폐렴에 속발한 가와사키병 2예

을지대학교 의과대학 소아과학교실

김현정 · 이수진

가와사키병은 전신성 혈관염을 일으키며 드물게 폐렴 등 호흡기 질환의 임상 양상으로 발현될 수 있다. 가와사키병은 아직 원인이 밝혀지지 않아 진단을 위한 검사 소견이 없고 전형적인 임상 양상에 의해 진단되어지므로 비전형적 임상 양상으로 나타날 경우 그 진단이 늦어질 수 있다. 항생제 치료에도 불구하고 폐렴이 악화되며 염증 반응이 증가되는 경우 가와사키병을 의심하는 것이 중요하다. 저자들은 폐렴으로 발현된 가와사키병 2예를 경험하였기에 보고하는 바이다.

References

- 1) Uziel Y, Hashkes PJ, Kassem E, Gottesman G, Wolach B. "Unresolving pneumonia" as the main manifestation of atypical Kawasaki disease. Arch Dis Child 2003;88:940-2.
- 2) Kim JY, Kwon JH, Kim KH, Yu JH, Hong YM. Chest X-ray findings and serum tumor necrosis factor- α levels in patients with Kawasaki disease. Korean J Pediatr 2005;48:534-8.
- 3) Rowley AH. Incomplete (atypical) Kawasaki disease. Pediatr Infect Dis J 2002;21:563-5.
- 4) Amano S, Hazama F, Kubagawa H, Tasaka K, Haebara H, Hamashima Y. General pathology of Kawasaki disease on the morphological alterations corresponding to the clinical manifestation. Acta Pathol Jpn 1980;30:681-94.
- 5) Burns JC, Wiggins JW Jr, Toews WH, Newburger JW, Leung DY, Wilson H, et al. Clinical spectrum of Kawasaki disease in infants younger than 6 months of age. J Pediatr

- 1986;109:759-63.
- 6) Sengler C, Gaedicke G, Wahn U, Keitzer R. Pulmonary symptoms in Kawasaki disease. Pediatr Infect Dis J 2004;23:782-4.
- 7) Umezawa T, Saji T, Mtsuo N, Odagiri K. Chest X-ray findings in the acute phase of Kawasaki disease. Pediatr Radiol 1989;20:48-51.
- 8) Yasukawa K, Terai M, Shulman ST, Toyozaki T, Yajima S, Kohno Y, et al. Systemic production of vascular endothelial growth factor and fms-like growth tyrosine kinase-1 receptor in acute Kawasaki disease. Circulation 2002;105:766-9.
- 9) Managoli S, Chaturvedi P. Kawasaki disease with coronary artery aneurysms and symptomatic pneumonia. Indian Pediatr 2003;40:1106-7.
- 10) Yavuz T, Nisli K, Yilmaz C, Dindar A. Large pleural effusion necessitates chest tube drainage in a patient with Kawasaki disease. J Paediatr Child Health 2007;43:191-2.
- 11) Voynow JA, Schanberg L, Sporn T, Kredich D. Pulmonary complications associated with Kawasaki disease. J Pediatr 2002;140:786-7.
- 12) Abe J, Kotzin BL, Jujo K, Melish ME, Glode MP, Kohsaka T, et al. Selective expansion of T cells expressing T-cell receptor variable regions V β 2 and V β 8 in Kawasaki disease. Proc Natl Acad Sci USA 1992;89:4066-70.
- 13) Curtis N, Zheng R, Lamb JR, Levin M. Evidence for a superantigen mediated process in Kawasaki disease. Arch Dis Child 1995;72:308-11.
- 14) Leen C, Ling S. Mycoplasma infection and Kawasaki disease. Arch Dis Child 1996;75:266-7.
- 15) Treadwell TA, Maddox RA, Holman RC. Investigation of Kawasaki syndrome risk factors in Colorado. Pediatr Infect Dis J 2002;21:976-8.
- 16) Bell DM, Brink EW, Nitzkin JL, Hall CB, Wulff H, Berkowitz ID, et al. Kawasaki syndrome: description of two outbreaks in the United States. N Eng J Med 1981;304:1568-75.
- 17) Dean AG, Melish ME, Hicks R, Palumbo NE. An epidemic of Kawasaki syndrome in Hawaii. J Pediatr 1982;100:552-7.
- 18) Rowley AH, Baker SC, Shulman ST, Garcia FL, Guzman-Cottrill JA, Chou P, et al. Detection of antigen in bronchial epithelium and macrophages in acute Kawasaki disease by use of synthetic antibody. J Infect Dis 2004;190:856-65.
- 19) Shike H, Shimizu C, Kanegaye JT, Foley JL, Schnurr DP, Wold LJ, et al. Adenovirus, adenovirus-associated virus and Kawasaki disease. Pediatr Infect Dis J 2005;24:1011-4.
- 20) Rowley AH, Shulman ST, Mask CA. IgA plasma cell infiltration of proximal respiratory tract, pancreas, kidney, and coronary artery in acute Kawasaki disease. J Infect Dis 2000;182:1183-91.