

Two adolescent cases of Fitz-Hugh-Curtis syndrome

Ji Hye Kim, M.D. and Sung Hee Oh, M.D.

Department of Pediatrics, Hanyang University School of Medicine, Seoul, Korea

= Abstract =

Two adolescent cases of Fitz-Hugh-Curtis syndrome, which has not been previously reported in Korean girls, presenting with right upper-quadrant abdominal pain, nausea, vomiting, and fever are reported here. A careful and thorough inquiry into the sexual history of the first patient, which was not done upon admission, led to a careful reassessment of the dynamic abdominal computed tomography scan revealing hepatic capsular enhancement without evidence of gallbladder or liver disease. Both cases were diagnosed noninvasively and were treated successfully by medical intervention. A high index of suspicion of Fitz-Hugh-Curtis syndrome should be implemented in the differential diagnosis of right upper quadrant pain, particularly in sexually active girls, for a prompt diagnosis and rapid cure. (*Korean J Pediatr* 2009;52:1038-1043)

Key Words : Fitz-Hugh-Curtis syndrome, Perihepatitis, Pelvic inflammatory disease, Capsule, Enhancement, Female adolescent

Introduction

Fitz-Hugh-Curtis syndrome (FHCS), first described by Curtis and Fitz-Hugh in the 1930s, is a syndrome characterized by right-sided abdominal pain and perihepatitis associated with pelvic inflammatory disease (PID)^{1, 2)}. The incidence of FHCS has been reported to be up to 12% in patients with PID using only the clinical criteria³⁾, and a similar rate (13.8%) was reported in another study using laparoscopic criteria⁴⁾. The rate of FHCS was reported to be higher (27%) in a study involving adolescents with salpingitis⁵⁾. Almost all the published studies, however, involved adult women, and studies documenting adolescents or young adults are rare. The frequency of FHCS in Korean adolescents has thus been poorly documented, even with the current undesirable social circumstances of earlier sexual debut. Two adolescent cases of FHCS are reported herein, in which multidetector dynamic computed tomography (CT) showed an abnormal hepatic capsular or pericapsular enhancement in the arterial-phase images.

Case report

1. Case 1

A 14-year-old middle school girl who complained of fever, nausea, headache, and constant epigastric pain for six days, which had progressed to right lower quadrant pain, was admitted to the surgical service via a local clinic for suspicion of acute appendicitis. Her epigastric pain was sharp in nature, but the lower abdominal pain was mild and had no relation to the ingestion of food. She also complained of dysuria and frequency which began five to six days prior to admission.

Upon physical examination, her body temperature was found to be 38.3°C, her respiratory rate 24/min, her heart rate 92/min, her systolic blood pressure 100 mmHg, and her diastolic blood pressure 70 mmHg. She demonstrated right upper abdominal tenderness, which was greater than the lower abdominal tenderness without rebound. Costovertebral-angle (CVA) tenderness was observed on both sides, but more on the left. The patient did not have any history of abdominal or pelvic surgery. The liver and spleen were not palpable. The white blood cell (WBC) count was 8,400/mm³ (polymorphonuclear leukocytes, 63%; lymphocytes, 31%; monocytes, 5%). Normal electrolytes and liver function test results were noted. The urinalysis showed the presence of many leukocytes and bacteria. The chest and

Received : 22 April 2009, Revised : 8 June 2009, Accepted : 5 August 2009
Address for correspondence : Sung Hee Oh, M.D.

Division of Infectious Diseases, Department of Pediatrics, College of Medicine, Hanyang University, #17, Haengdang-dong, Seongdong-gu, Seoul, 133-791, Korea

Tel : 82-2-2290-8388, Fax : 82-2-2297-2380

E-mail : sungheeo@hanyang.ac.kr

abdominal radiographs were unremarkable. The abdominal sonogram showed a normal-diameter appendix and unremarkable findings for the hepatobiliary system. Intravenous cefotaxime was administered for the presumed urinary tract infection. The patient became afebrile, but continued to have abdominal pain. Abdominal dynamic CT was performed, which revealed pyelonephritis of the left kidney, mild hepatomegaly with parenchymal enhancement and periportal edema.

The patient was transferred to Department of Pediatrics for further management. She persistently complained of right upper-quadrant abdominal pain associated with right-flank pain, nausea and dysuria. Her menstruation had been unremarkable with her menarche occurring about a year ago. Her last menstrual period had started two weeks prior to her admission. In the more detailed history taking, she admitted having had increased vaginal discharge in the week prior to her admission. The findings of her abdominal examination showed tenderness in the right upper-quadrant abdomen and diffuse tenderness in the lower abdomen. Mild CVA tenderness was also observed on both sides.

The laboratory investigations yielded a WBC count of $6,200/\text{mm}^3$ (polymorphonuclear leukocytes, 68%; lymphocytes, 29%; monocytes, 2%). The erythrocyte sedimentation rate (ESR) was 17 mm/hr and the C-reactive protein (CRP) was 1.0 mg/dL. The urinalysis showed many leukocytes, 2+ erythrocytes, and many bacteria, and the administration of intravenous cefotaxime was continued. Urine culture was obtained, which later grew *Escherichia coli* $>100,000$ CFU/mL. While the patient was being treated

for urinary tract infection, further investigation and thorough history taking were done, which revealed that the patient had sexual activity with no use of any form of contraception. The patient denied having had any previous sexually transmitted disease. Pelvic examination was performed, with unremarkable results. The pelvic ultrasonogram suggested the possibility of pelvic inflammatory disease. The results of the β -hCG and VDRL tests were within normal limits. The results of the serologic tests for *Chlamydia trachomatis* were negative. The cervical bacteria culture revealed the absence of organisms.

The patient's symptoms of nausea and right upper abdominal pain seemed to have been resolved by the intravenous cefotaxime, which was continued to be administered for 14 days. The repeated urine culture was negative, and the DMSA (dimercaptosuccinic acid) renal scan showed no significant cortical defect of the kidneys. The repeated computerized tomography of the abdomen demonstrated a normal nephrogram with no evidence of hydronephrosis on either kidney, mild hepatomegaly and arterial-phase hepatic capsular enhancement (Fig. 1A, B). With a diagnosis of Fitz-Hugh-Curtis syndrome, the patient was discharged on a regimen of amoxicillin and doxycycline.

The patient was readmitted five days later, however, due to recurrent one-day-long episodes of abdominal pain, vomiting, diarrhea, and fever. Abdominal ultrasonogram was performed, which yielded normal results. In the pelvic examination, the patient was found not to have cervical-motion tenderness, but a small amount of fluid was found in the cul-de-sac. Laparoscopy of the abdomen was recom-

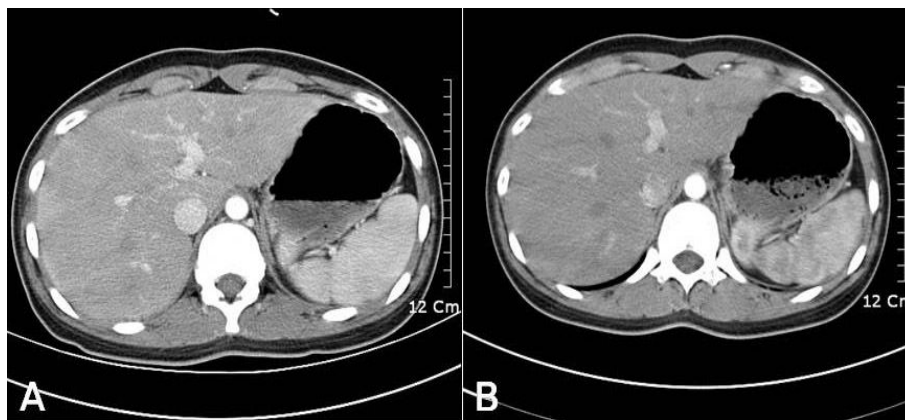


Fig. 1. (A) Arterial-phase axial computed tomography (CT) scan shows an enhanced hepatic capsule along the right hepatic surface. (B) Portal-phase CT scan of an equal level shows normal enhancement patterns.

mended, but it was not done, because the patient's symptoms were resolved with the administration of intravenous cefotaxime, oral doxycycline, and oral metronidazole. The patient was discharged with cefdinir, doxycycline, and metronidazole to complete a ten-day course. She has returned to school with no other complications.

2. Case 2

A 17-year-old girl was admitted to the Department of Pediatrics with the complaints of right-sided abdominal pain, fever for three days, and three times of projectile, bilious vomiting for one day. Her abdominal pain was sharp, and radiated to the right flank. It was exacerbated by the inspiration and movement of the thorax, but it did not make the patient dyspneic. The patient's past medical history was relevant with treatment for gastro-esophageal reflux and gastritis one year previously. Her menarche occurred at 13 years of age, and her menstruation had been regular until one month prior to her hospitalization, when she began to have a moderate amount of whitish vaginal discharge.

Upon admission, the patient's body temperature was 39.5°C, her respiratory rate was 24/min, her heart rate 96/min, her systolic blood pressure 100 mmHg, and her diastolic blood pressure 60 mmHg. No abnormalities of the chest were found via auscultation. There was right upper-quadrant tenderness and moderate bilateral lower-quadrant tenderness with rebound and guarding. The bowel sound was normal, with no hepatosplenomegaly or detectable masses. CVA tenderness on the right side was also found, and it was not completely distinguishable with the right upper-quadrant abdominal tenderness. Several diagnoses were entertained, such as cholelithiasis, cholecystitis, pyelonephritis, and appendicitis.

The patient's laboratory tests revealed 11.3 g/dL hemoglobin, 34.7% hematocrit, and 173,000/mm³ platelet count. The WBC count was 10,200/mm³ (polymorphonuclear leukocytes, 86%; lymphocytes, 9%; monocytes, 5%), the ESR 35 mm/hr, and the CRP 7.4 mg/dL. The urinalysis demonstrated 10–19 leukocytes/high-power field, and the other laboratory values were as follows: aspartate aminotransferase, 16 U/L; alanine aminotransferase, 7 U/L; blood urea nitrogen, 14 mg/dL; creatinine, 0.7 mg/dL; sodium, 135 mEq/L; potassium, 3.6 mEq/L; chloride, 99 mEq/L; amylase, 36 U/L; and total bilirubin, 0.5 mg/dL. The urine culture revealed no bacteria growth. The pregnancy test was negative. The serum IgM and IgG antibodies to *Chlamydia*

trachomatis were both negative. The cervical specimens of the culture and Gram stain for *Neisseria gonorrhoea* and the culture for *C. trachomatis*, were also negative. The results of the HIV and VDRL tests were negative. The simple abdominal and chest X-rays, intravenous pyelogram (IVP), and abdominal ultrasonography all yielded normal findings. Intravenous ceftriaxone was given for suspected urinary tract infection until a negative urine culture result was obtained. Due to the patient's persistent right-sided abdominal pain, abdominal computed tomography was done, which showed right perihepatic capsular enhancement and a small amount of fluid collection in the pelvic cavity. No abnormalities were found in the liver parenchyme, gallbladder, bile ducts, and pancreas. In the through history taking, she admitted having had sexual activity with her boyfriend a few months prior to her admission.

The treatment for the patient's Fitz-Hugh-Curtis syndrome, included bed rest and administration of antibiotics, oral doxycycline and intravenous ceftriaxone. The repeated cervical culture did not produce any *C. trachomatis* or gonococcus. The patient's symptoms subsided after a four-day therapy, and she was discharged on a regimen of doxycycline for 14 days. After four weeks, however, in the follow-up examination, it was found that the patient's mild right upper-quadrant pain and tenderness persisted. Her regimen was changed to metronidazole and cephalexin. In the patient's follow-up visit seven days later, she was found to be symptom-free. After one month, the follow-up pelvic examination yielded normal results, and the follow-up abdominal dynamic CT showed no abnormal finding. The patient remains well without any complication.

Discussion

When FHCS was first described by Curtis in the 1930s, it was characterized by "violin-string" adhesion between the anterior surface of the liver and the parietal peritoneum in patients with coexistent gonococcal pelvic disease¹⁾. This syndrome has been described as perihepatitis accompanied by pelvic inflammatory disease (PID), which occurs in 5–15% of the cases^{6, 7)}. The age distribution is not well described, but adolescents are reported to have higher rates of affliction with the disease⁵⁾. The initial symptom is excruciating, sharp abdominal pain, mostly intense at the right lower-rib margin over the area of the

gallbladder. It is pleuritic, exaggerated by deep breathing, coughing, or laughing, and by the movement of the trunk⁸⁾. The pain may also radiate to the right shoulder or to the inside of the arm. It is often accompanied by guarding and positive Murphy's sign⁹⁾. Chills, fever, sweating, nausea, vomiting, hiccupping, malaise and headache are also commonly associated with it.

The pathologic findings of perihepatitis in FHCS vary according to the clinical phase. In the acute phase, mild exudative inflammation of the hepatic capsule is the main characteristic. Capsular congestion, punctate hemorrhage, and fibrinous exudation may also be seen⁶⁾. In the chronic phase, a violin-string appearance that reflects adhesion between the anterior surface of the liver and the abdominal wall develops.

In the physical examination, tenderness is usually found at the anterior portion of the right upper abdominal wall, with some guarding. Both patients demonstrated the typical right upper-quadrant abdominal pain at the lower-rib margin, which caused diagnostic confusion with CVA tenderness. A friction rub may be heard at the right anterior costal margin. Vaginal discharge, cervical motion tenderness, or adnexal tenderness previously unnoticed by the patient may be detected in the bimanual pelvic examination¹⁰⁾. Although no cervical-motion tenderness or adnexal tenderness was found in the pelvic examination, the careful history taking with the patients revealed sexual activity associated with a recent increase of vaginal discharge. The absence of abnormalities in the pelvic exam may be explained by the time delay of a few days between the beginning of the antibiotic therapy and the consultation with the gynecologic department.

Laboratory tests, except for cervical culture and a few serologic tests for antibodies, have limited value in the diagnosis of FHCS. The liver enzyme levels are usually normal or only slightly elevated, which can help rule out hepatitis^{11, 12)}. The WBC count is elevated, but seldom above 15,000/mm³. The ESR has been shown to be elevated in some small series and case reports^{7, 13, 14)}, but other studies have found lesser association^{5, 11)}. To identify the pathogen, cervical culture is most commonly obtained. Serologic tests for *C. trachomatis* or a nucleic acid amplification test for both *N. gonorrhoeae* and *C. trachomatis* are also helpful. *N. gonorrhoea* was thought to be the sole causative agent of the syndrome for many years^{2, 5)}. *C. trachomatis* has also been cultured from the

cervix, the fallopian tubes, and in a few cases from the liver capsule in patients with perihepatitis^{15, 16)}. The pathogenesis is still poorly understood, and several mechanisms, such as direct infection via the fallopian tubes¹⁷⁾, hematogenous spread¹³⁾, lymphatic spread⁶⁾, and "hyper-immune" response to *C. trachomatis*¹¹⁾ have been suggested.

Chest and abdominal radiographs are useful to in ruling out the other possible causes of the symptoms in the cases presented herein, such as pneumonia or perforated ulcer, shown as free air under the diaphragm¹⁰⁾. Ultrasonography may also help rule out diseases of the gallbladder and liver. As shown in the cases reported herein, multidetector-CT can be used as a highly sensitive imaging modality for the early detection of FHCS. Marked hepatic capsular enhancement at the arterial phase, which immediately disappears in the later phase is characteristic¹⁸⁾.

A differential diagnosis involves pyelonephritis, cholecystitis, cholelithiasis, rib fracture, pancreatitis, appendicitis, hepatitis, peptic ulcer disease, pneumonia, pleurisy, pulmonary embolus, and subphrenic abscess. FHCS is most often mistaken for acute cholecystitis, especially in cases in which the right upper quadrant pain is more pronounced than the pelvic symptoms, or when perihepatitis is found to be present long before or after the appearance of the symptoms of PID¹⁹⁾. Wood et al indicated that FHCS accounted for 5–10% of all admissions with clinically diagnosed acute cholecystitis²⁰⁾. Considering that gallstones are uncommon in young women, especially when they are not obese, but PIDs are common, FHCS should be included in the differential diagnosis of right-upper quadrant abdominal pain whether the symptoms and signs of PID are present or not.

The confirmation of FHCS requires open surgery or the laparoscopic approach⁵⁾. The diagnosis, however, is usually confirmed clinically by excluding the other possible causes of the right upper-quadrant pain, performing positive cultures, and inducing rapid improvement with the use of appropriate antibiotics⁷⁾. In the cases reported herein, confirmative invasive diagnostic procedures like laparoscopy or laparotomy were not carried out. The findings of dynamic CT imaging which revealed characteristic hepatic capsular enhancement in both patients were helpful in the diagnosis. The CT findings of capsular enhancement in the early-phase images of FHCS reflect increased blood flow at the inflamed hepatic capsule, whereas enhancement in

the delayed phase may reflect early capsular fibrosis^{18, 21)}.

A possible radiologic differential diagnosis of hepatic capsular enhancement is a subcapsular spared area in a fatty liver²²⁾ and early subcapsular enhancement caused by superior vena cava obstruction²³⁾. As the syndrome became better known, it began to be diagnosed more frequently during surgical exploration for other problems such as infertility or presumed cholecystitis¹⁰⁾. Considering that the syndrome is a benign condition that can be cured by the oral administration of appropriate antibiotics, laparoscopy should be performed when the medical evaluation has ruled out other organic diseases and when antibiotic therapy proves not beneficial⁸⁾. The coagulated violin-string adhesion can be easily broken down with the use of laparoscopic scissors. The pelvic area, as well as the remainder of the abdominal cavity, should be completely explored.

The treatment involves antibiotic therapy similar to that in the treatment of pelvic inflammatory disease. The antibiotics should be directed at the most likely pathogens, especially *N. gonorrhoeae*, *C. trachomatis*, facultative gram-negative rods, and anaerobes¹⁰⁾. The administration of appropriate antibiotics such as tetracycline, doxycycline, erythromycin, ofloxacin, and azithromycin, should be started as soon as the FHCS is suspected. The pain usually subsides with antibiotic therapy. The conventional treatment period of 10–14 days for pelvic inflammatory disease may have to be extended. The long-term complications of FHCS are rare.

In the cases presented herein, the cervical culture or immunoserological tests did not show either *N. gonorrhoeae* or *C. trachomatis* infection. This may be explained by the antibiotic administration before sampling the specimen for cervical culture in the first case. In these circumstances, the negative result of the cultures may not completely exclude the possibility of infection by *N. gonorrhoeae*, *C. trachomatis*, or other bacterial organisms, but suggests the possibility by infection of uncommon bacterial organisms, reflecting diverse microorganisms causing PID compared with the past²⁴⁾.

In conclusion, the proper recognition of FHCS requires a high index of suspicion and is based both on its clinical manifestations and the exclusion of other causes of right upper-quadrant pain. It may not be associated with the signs and symptoms of pelvic inflammatory disease, and can be encountered in pre-adolescents as well as adolescents¹⁵⁾. This may allow clinicians to avoid further

unnecessary invasive diagnostic tests. As sexual debut is becoming earlier nowadays in Korea, a detailed and thorough history taking of sexual activity among adolescents is crucial in the diagnosis of FHCS.

To the best of our knowledge, we are the first to report FHCS in Korean adolescents. The changes in the Koreans' socioeconomic conditions have rendered an increased proportion of Korean adolescents with earlier sexual debut and activity, which means that a greater proportion of them would be susceptible to pelvic inflammatory diseases, and therefore more reports on FHCS in this age group are expected. In conclusion, Fitz-Hugh-Curtis syndrome, in addition to pyelonephritis, pancreatitis, appendicitis, hepatitis, peptic ulcer disease, pneumonia, pleurisy, and subphrenic abscess, should be included in the differential diagnosis when a female adolescent complains of right upper quadrant abdominal pain.

한글 요약

청소년에서의 Fitz-Hugh-Curtis Syndrome 2례

한양대학교 의과대학 소아과학교실

김지혜·오성희

Fitz-Hugh-Curtis syndrome (FHCS)은 골반 내 염증과 동반된 간조직 주위염으로, 담도계 질환과 혼돈되는 우측 상복부 통증이 특징이다. 최근 한국에서도 청소년의 성적 접촉 시작 연령이 빨라짐에 따라 이와 같은 증후군의 발생률 또한 증가할 것으로 예측된다. 저자들은 역동적 복부 전산화 단층 촬영을 이용하여 동맥기의 비정상적인 간주위 피막의 조영 증강 양상으로 진단한 Fitz-Hugh-Curtis Syndrome 2례를 보고하고자 한다.

References

- 1) Curtis AH. Causes of adhesions in the right upper quadrant. JAMA 1930;94:1221-2.
- 2) Fitz-Hugh T Jr. Acute gonococcal peritonitis of the right upper quadrant in women. JAMA 1934;102:2094-6.
- 3) Semchyshyn S. Fitz-Hugh and Curtis syndrome. J Reprod Med 1979;22:45-8.
- 4) Onsrud M. Perihepatitis in pelvic inflammatory disease-association with intrauterine contraception. Acta Obstet Gynecol Scand 1980;59:69-71.
- 5) Litt IF, Cohen MI. Perihepatitis associated with salpingitis in adolescents. JAMA 1978;240:1253-4.
- 6) Lopez-Zeno JA, Keith LG, Berger GS. The Fitz-Hugh-Curtis syndrome revisited. Changing perspectives after half a century. J Reprod Med 1985;30:567-82.
- 7) Katzman DK, Friedman IM, McDonald CA, Litt IF. Chlamy-

- dia trachomatis Fitz-Hugh-Curtis syndrome without salpingitis in female adolescents. *Am J Dis Child* 1988;12:996-8.
- 8) Reichert JA, Valle RF. Fitz-Hugh-Curtis syndrome. A laparoscopic approach. *JAMA* 1976;236:266-8.
 - 9) Bolton JP, Darougar S. Perihepatitis. *Br Med Bull* 1983;39:159-62.
 - 10) Nadja GP, Liana RC, Jeffrey RJ. Fitz-Hugh-Curtis syndrome: A diagnosis to consider in women with right upper quadrant pain. *Cleve Clin J Med* 2004;71:233-9.
 - 11) Money DM, Hawes SE, Eschenbach DA. Antibodies to the chlamydial 60 kd heat-shock protein are associated with laparoscopically confirmed perihepatitis. *Am J Obstet Gynecol* 1997;176:870-7.
 - 12) Kornfeld SJ, Worthington MG. Culture-proved Fitz-Hugh-Curtis syndrome. *Am J Obstet Gynecol* 1981;139:106-7.
 - 13) Banerjee B, Rennison A, Boyes BE. Sonographic features in a case of Fitz-Hugh-Curtis syndrome masquerading as malignancy. *Br J Radiol* 1992;65:342-4.
 - 14) Joo SH, Kim MJ, Lim JS, Kim JH, Kim KW. CT diagnosis of Fitz-Hugh and Curtis syndrome: value of the arterial phase scan. *Korean J Radiol* 2007;8:40-7.
 - 15) Fuld FL. Gonococcal peritonitis in a prepubertal child. *Am J Dis Child* 1971;121:536.
 - 16) Dalaker K, Gjonnaess H, Kvile G, Urnes A, Anestad G, Bergan T. Chlamydia trachomatis as a cause of acute perihepatitis associated with pelvic inflammatory disease. *Br J Vener Dis* 1981;57:41-3.
 - 17) Vickers F, Maloney P. Gonococcal perihepatitis. *Arch Intern Med* 1964;11:120-3.
 - 18) Nishie A, Yoshimitsu K, Irie H, Yoshitake T, Aibe H, Tajima T, et al. Fitz-Hugh-Curtis syndrome. Radiologic manifestation. *J Comput Assist Tomogr* 2003;27:786-91.
 - 19) Counselman FL. An unusual presentation of Fitz-Hugh-Curtis syndrome. *J Emerg Med* 1994;12:167-70.
 - 20) Wood JJ, Bolton JP, Cannon SR, Allan A, O'Connor BH, Darougar S. Biliary-type pain as a manifestation of genital tract infection: The Curtis-Fitz-Hugh syndrome. *Br J Surg* 1982;69:251-3.
 - 21) Keane JA, McKimm RJ, David CM. Perihepatitis associated with pelvic infection: the Fitz-Hugh-Curtis syndrome. *N Z Med J* 1982;95:725-8.
 - 22) Chen WP, Chen JH, Hwang JI, Tsai JW, Chen JS, Hung SW, et al. Spectrum of transient hepatic attenuation differences in biphasic helical CT. *AJR Am J Roentgenol* 1999;172:419-24.
 - 23) Yoshimitsu K, Honda H, Kuroiwa T, Irie H, Aibe H, Shinozaki K, et al. Unusual hemodynamics and pseudolesions of the noncirrhotic liver at CT. *Radiographics* 2001;21:S81-96.
 - 24) Cho HJ, Kim HK, Suh JH, Lee GJ, Shim JC, Kim YH. Fitz-Hugh-Curtis syndrome: CT findings of three cases. *Emerg Radiol* 2008;15:43-6.