

## 심장이식후에 발생한 외과적 합병증 — 단일 센터 경험 —

박국양\* · 박철현\* · 전양빈\* · 최창휴\* · 이재익\*

### Surgical Complications in Heart Transplant Recipients — A Single Center Experience —

Kook-Yang Park, M.D.\*, Chul-Hyun Park, M.D.\*, Yang-Bin Jeon, M.D.\*, Chang-Hyu Choi, M.D.\*, Jae-Ik Lee, M.D.\*

**Background:** As the patients who undergo heart transplantation have achieved better survival in recent years, a growing number of recipients are at a risk for experiencing surgical complications in addition to rejection and infection. In this paper, we report on our experience with the surgical complications that occurred in heart transplant recipients. **Material and Method:** From April 1994 to September 2003, 37 heart transplantations were performed at our center by a single surgeon. The indications for transplantation were dilated cardiomyopathy, ischemic cardiomyopathy, valvular cardiomyopathy and familial hypertrophic cardiomyopathy. **Result:** Twenty postoperative complications required surgeries in 15 patients (41%). The types of operations required were; redo-sternotomy for bleeding (5), pericardiostomy for effusion (4), implantation of a permanent pacemaker (1), right lower lobe lobectomy for aspergilloma (1), removal of urinary stone (1), cholecystectomy for gall bladder stone (1), drainage of a perianal abscess (1), paranasal sinus drainage (1), total hip replacement (1), partial gingivectomy due to gingival hypertrophy (1), urethroostomy (1), herniated intervertebral disc operation (1) and total hysterectomy for myoma uteri (1). The locations of the complications were mediastinal in 10 (27%) cases and extramediastinal in 10 (27%) cases. **Conclusion:** The relatively high incidence of extrathoracic complications associated with heart transplantation emphasizes the importance of a multidisciplinary approach to the improve long-term survival when managing those complex patients.

(Korean J Thorac Cardiovasc Surg 2009;42:719-724)

**Key words:** 1. Heart transplantation  
2. Complication

### INTRODUCTION

Orthotopic heart transplantation has been established as the most effective treatment for patients with end stage heart failure. However, many postoperative mediastinal[1-4] and extramediastinal complications have been reported in the literature[5-7]. General surgical complications have also been reported in a high proportion of patients with an incidence of 9% to 34%[8,9].

The difficulty of handling these complications arises from

preoperative chronic debilitating conditions and postoperative immunosuppression. Previous studies have addressed this issue and concluded that anesthesia and operations in heart transplantation patients with surgical complications are safe. These studies emphasize early diagnosis and aggressive treatment to reduce the morbidity and mortality associated with late diagnosis[10].

Although several case reports regarding postoperative complications have been published in Korean journals[11-14], this single center study is believed to be the first collective re-

\*가천의과대학교 길병원 심장센터 흉부외과

Department of Cardiothoracic Surgery, Gil Heart Center, Gachon University Gil Medical Center

논문접수일 : 2009년 5월 27일, 논문수정일 : 2009년 8월 26일, 심사통과일 : 2009년 8월 27일

책임저자 : 박국양 (405-760) 인천시 구월동 1198, 가천의과대학교 길병원 심장센터

(Tel) 1577-2299, (Fax) 032-232-0439, E-mail: kkyypark@gilhospital.com

본 논문의 저작권 및 전자매체의 지적소유권은 대한흉부외과학회에 있다.

view data of long-term followup related to extramediastinal complications after heart transplantation.

We retrospectively reviewed our experiences in the diagnosis and management of surgical problems occurring in 37 consecutive heart transplant recipients.

## MATERIAL AND METHOD

Thirty-seven consecutive orthotopic heart transplantations were performed between April 1994 and September 2002 at the Gil Heart Center, Incheon, Republic of Korea. There were 27 men and 10 women, and their ages ranged from 12 to 60 years (mean age  $40 \pm 2.20$  years) (Table 1). The indications for transplantation were dilated cardiomyopathy (n=28, 76%), ischemic cardiomyopathy (n=4, 11%), valvular cardiomyopathy (n=4, 11%), and familial hypertrophic cardiomyopathy (n=1, 3%).

All patients were given prophylactic antibiotics with vancomycin for 5 days postoperatively and an aminoglycoside either amikacin or gentamycin for 3 days.

Early postoperative immunosuppression was achieved with intravenous cyclosporine, methylprednisolone, and a 3-day course of rabbit anti-thymocyte globulin (RATG) therapy. Oral immunosuppression was based on cyclosporine, azathioprine, and steroids. The cyclosporine dose was adjusted to a target whole-blood trough level between 200 and 300 ng/ml (using the whole blood TDX method) for the first month and then slowly reduced to a maintenance level of 100~150 ng/ml. Prednisone was rapidly tapered to 20 mg/day within one month. It is our center's policy to withdraw steroids completely if there are any steroid-related complications. After mycophenolate mofetil (MMF, Cellcept) was introduced, azathioprine was replaced by MMF in all patients.

Rejections were monitored by regularly scheduled endomyocardial biopsies, and rejection episodes of grade 3A or higher[16] were treated with a pulsed dose of methylprednisolone. Endomyocardial biopsies were performed routinely once a week for the first month, twice a month until 3 months, once a month until 6 months and once a year thereafter. The jugular vein or femoral vein was used for catheter introduction. Rejection episodes were defined as any biopsy specimen with grade 3A or higher according to the classi-

Table 1. Patient demographics (n=37)

Donor age (yr)	29±9.9
Recipient age (yr)	40±2.2
Recipient gender(M/F)	27/10
Surgical technique	
Conventional method	13 (35%)
Bicaval anastomosis	24 (65%)
Graft ischemic time (min)	131±50.31
Indications for transplantation	
DCMP	28 (76%)
ICMP	4 (11%)
VCMP	4 (11%)
CCMP	1 (3%)

DCMP=Dilated cardiomyopathy; ICMP=Ischemic cardiomyopathy; VCMP=Valvular cardiomyopathy; CCMP=Congenital cardiomyopathy.

fication of the International Society of Heart Lung Transplantation[16]. These rejections were treated either using a pulsed dose of intravenous methyl prednisolone or with a variety of other agents (methotrexate, cytolytic therapy, or plasmapheresis) depending on their histologic grades and their hemodynamic consequences.

Long-term follow-up was completed in all patients. Mean patient follow-up was 49 months (range 1 to 115 months); 151 patient-years were recorded.

## RESULT

Twenty postoperative surgical problems developed in 15 of 37 patients (41%) (Table 2). The types of surgery performed postoperatively were redo-sternotomy for bleeding (5), pericardiostomy for effusion (4), implantation of a permanent pacemaker (1), removal of urinary stone (1), cholecystectomy for gall bladder stone (1), total hysterectomy due to myoma (1), drainage of a perianal abscess (1), right lower lobe lobectomy due to aspergilloma (1), paranasal sinus drainage (1), total hip replacement (1), partial gingivectomy due to gingival hypertrophy (1), herniated intervertebral disc operation (1), and urethroostomy (1).

Complication locations were mediastinal in 10 (50%) and extramediastinal in 10 (50%). The mean interval of onset between symptoms and operation was 33.5 months (range: 2~88 months) for extramediastinal complications. All patients

**Table 2.** Surgical complications after heart transplant recipients in 15 patients

Location and operation	Cases	Interval (d, m)*
Mediastinal		
Redo-sternotomy (bleeding)	5	1~3 d
Pericardiostomy (effusion)	4	2~6 m
Permanent pacemaker	1	1 m
Extramediastinal		
Paranasal sinus drainage	1	4 m
Perianal abscess drainage	1	8 m
Total hysterectomy (myoma)	1	9 m
Right lower lobectomy (aspergilloma)	1	10 m
Herniated intervertebral disk	1	11 m
Gingivectomy (gingival hypertrophy)	1	24 m
Total hip replacement (aseptic necrosis)	1	3 m
Cholecystectomy for gall bladder stone	1	6 m
Removal of urinary bladder stone	1	88 m
Urethroostomy	1	33 m
Total	20 (15 patients)	28.22 (4~88)

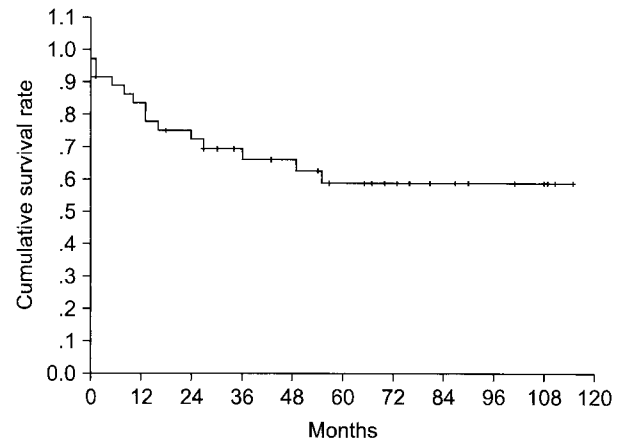
\*=Interval between cardiac transplantation and second operation (d=days, m=months).

survived the operation.

A grade III or more tricuspid regurgitation occurred in two cases with the conventional atrial cuff techniques, which were treated conservatively. We have not experienced any cases of mediastinitis or aortic aneurysm. All redo-sternotomy procedures were performed within 3 postoperative days.

Mediastinal complications occurred in 10 patients and the majority of these were due to acute bleeding or delayed effusion. A permanent pacemaker was implanted in a case in which the atrial cuff technique was applied with a graft ischemic time of 102 minutes.

Extramediastinal surgical diseases developed at a mean of 28.22 months after heart transplantation (range 4 to 88 months). A paranasal sinus was drained due to increased purulent discharge after transplantation in a male patient, and another patient showed an aggravated perianal abscess after immunosuppression, which was drained. A case with continuous men-

**Fig. 1.** Actuarial survival for heart transplants performed between 1994 and 2003.

orrhagia was found to have a hen-egg sized myoma and underwent hysterectomy, and a 39 year old male patient developed systemic aspergillosis 3 months after operation and was treated with intravenous amphotericin B. A right lower lobectomy was performed to eradicate a remained thumb-tip sized lesion in this patient. Steroid related lesions were noted in two patients; one as a herniated intervertebral disk, the other one as an avascular necrosis of both hip joints. In the latter case, a lateral ventricular resection of the left ventricle was performed 18 months before the heart transplantation. Total hip replacement was done on both hips in this case 32 months after the transplantation surgery. An ugly looking gingival hypertrophy was severe in one case and a partial resection was performed to relieve it. Stone lesions were noted in two cases. One of these patients had a stone in the gall bladder and cholecystectomy was done. In the other patient, stones were found in the urinary bladder, which were treated surgically.

No mortality was noted related to the surgical procedures adopted to treat these complications. Ten surgical complications were related with the transplantation procedure and the other ten were mainly related to the immunosuppression.

The Kaplan-Meier survival curve for entire transplant recipients is depicted in Fig. 1. Survivals at 1, 5, and 9 years were 92%, 70%, and 60% respectively. Deaths were caused by chronic graft dysfunction in seven, acute postoperative graft failure in two, lymphoma in one, accelerated graft athe-

rosclerosis in one, acute subarachnoidal hemorrhage in one, aspergillosis in one, and intractable humoral rejection in one.

## DISCUSSION

To briefly introduce the status of heart transplantation in Korea, the first successful heart transplantation was performed in 1992 in a 38-year-old woman with dilated cardiomyopathy by Dr. Song at the Asan Medical Center, Seoul[15], and 212 heart transplantations have been performed up to September 2003. Brain death legislation was passed in Korea in 1999 and became effective one year later, and since the introduction of this legislation all activities related to organ donation and distribution have been under the control of the Korean Network for Organ Sharing (KONOS), which functions like the UNOS in the United States.

We started our heart transplantation program in 1993 after one of our authors learned basic techniques from Dr. Copeland of the University of Arizona, Tucson, AZ and then returned to Korea. Our first case was successfully performed in 1994 and since then we have performed 37 heart, and 3 heart lung transplantations.

As reported elsewhere in the literature, we have also experienced various surgical complications in our heart transplant recipients during the early and chronic follow-up periods. Postoperatively these patients are at an increased risk of a variety of medical and surgical complications. The high rate of general surgical complications encountered is attributed to two main factors. One is the poor preoperative patient's condition and the other concerns postoperative immunosuppression.

The incidence of these general surgical complications has been reported to be between 9% and 34%. If we exclude immediate postoperative mediastinal complications, the rate of extramediastinal general surgical complications is 27% (10 of 37 cases) in our series, which is not higher than other groups [5-10].

Intrathoracic surgical complications occurred in 11 cases, one of which received a lobectomy for postoperative aspergilloma. This patient was on Amphotericin B treatment for 2 months, which was followed by surgical removal of the remained fungus ball. A patient who underwent heart trans-

plantation with the conventional atrial cuff technique showed a permanent sinus node dysfunction postoperatively and an atrial pacemaker (AAI type) was implanted. Most of the other intrathoracic complications were either redo-sternotomies for bleeding control or pericardiostomies due to effusion.

Extrathoracic surgical complications include a group of disease related mostly with immunosuppression. Two patients underwent orthopedic surgeries, probably related with long-term steroid use. In one of these patients, total hip replacement was performed due to avascular necrosis of both hips 2½ years after transplantation. This patient also received a left ventricular volume reduction surgery 18 month prior to heart transplantation, and postoperatively he had suffered from a chronic urethral stricture, which was relieved by urethroscopy. In the other patient, disk removal was performed because of an intractable low back pain due to a herniated intervertebral disk at L4-5. Other general surgical complications included endoscopic cholecystectomy in a case of gall stone cholecystitis (1), removal of bladder stone (1), drainage of abscesses in the perianal area (1), drainage of paranasal sinus (1), partial gingivectomy (1), and a total hysterectomy with myoma uteri and menorrhagia (1). Steroids were withdrawn as soon as possible in all patients with these complications. To our surprise, we have not experienced mediastinitis, aortic aneurysm, or malignancy in our series.

Mortality related to the general surgical complications has also decreased over the years. During the initial period of transplantations, the mortality rate due to complications was quite high. Dr. Steed and coworkers reported that 10 of 21 patients (48%) died of complications[5]. However, in recent reports, most authors agree that early and aggressive intervention can reduce mortality and morbidity. By adopting such a policy, Kirklin and associates reduced mortality from general surgical complications to 0% between January 1987 and December 1989[6]. It is also our policy to intervene as early as possible in cases showing any surgical complications. All patients in our series survived the general surgical operations, and this experience also supports the benefit of early intervention when any surgical complications are met. The survival statistics of patients with or without surgical disease are similar, suggesting that a surgical disease is not a risk factor of death in postoperative patients.

The high proportion of surgical disease potentially related to immunosuppressive therapy (10 of 20: 50%) or to the surgical procedure (10 of 20: 50%) shows that heart transplantation recipients constitute a new surgical population with unique characteristics and problems.

Although the number of cases we experienced is relatively small, we have experienced various complications related to both mediastinal and extramediastinal problems. The mediastinal complications were mainly observed in the early postoperative period and extramediastinal problems in the late postoperative period.

## CONCLUSION

It is our policy to withdraw steroids as early as possible to reduce immunosuppression-related complications. We also believe that correct diagnosis and early intervention of general surgical complications is needed to reduce mortality and morbidity even in heart transplant recipients.

## ACKNOWLEDGEMENTS

We'd like to express our gratitude to Kwangho (Kevin) Ahn (Glenelg Country School, Howard, Maryland) for helping us gathering patients' data and translation of this article into English.

## REFERENCES

1. Law Y, Belassario A, West L, Coles J, Taylor G, Benson L. *Supramitral valve obstruction from hypertrophied native atrial tissue as a complication of orthotopic heart transplantation*. J Heart Lung Transplant 1997;16:922-5.
2. Oaks TE, Rayburn BK, Brown ME, Kon ND. *Acquired cor triatriatum after orthotopic cardiac transplantation*. Ann Thorac Surg 1995;59:751-3.
3. Dreyfus G, Jebara VA, Couetil JP, Carpentier A. *Kinking of the pulmonary artery: a treatable cause of acute right ventricular failure after heart transplantation*. J Heart Transplant 1990;9:575-6.
4. Defraigne JO, Vadhat O, Lavigne JP, Demoulin JC, Limet R. *Aneurysm of the ascending aorta after cardiac transplantation*. Ann Thorac Surg 1992;54:983-4.
5. Steed DL, Brown B, Reilly JJ, et al. *General surgical complications in heart and heart-lung transplantation*. Surgery 1985;98:739-45.
6. Kirklin JK, Holm A, Aldrete JS, White C, Bourge RC. *Gastrointestinal complications after cardiac transplantation. Potential benefit of early diagnoses and prompt surgical intervention*. Ann Surg 1990;211:538-41.
7. Colon R, Frazier OH, Kahan BD, et al. *Complications in cardiac transplant patients requiring general surgery*. Surgery 1988;103:32-8.
8. Parascandola SA, Wisman CB, Burg JE, Davis PK. *Extracardiac surgical complications in heart transplant recipients*. J Heart Transplant 1989;8:400-6.
9. Augustine SM, Yeo CJ, Buchman TG, Achuff SC, Baumgartner WA. *Gastrointestinal complications in heart and heart-lung transplant patients*. J Heart Lung Transplant 1991;10:547-56.
10. Bhatia DS, Bowen JC, Money SR, et al. *The incidence, morbidity, and mortality of surgical procedures after orthotopic heart transplantation*. Ann Surg 1997;225:686-94.
11. Kwon JI, Kim YJ, Choi KL, et al. *Meningitis clue to *Listeria monocytogenes* following orthotopic heart transplantation*. Korean Circ J 1998;28:1616-9.
12. Kim YH, Son H, Song MG. *Cyclosporine-associated central nervous system toxicity after heart transplantation -1 case report-*. Korean J Thorac Cardiovasc Surg 1997;30:1136-8.
13. Lee CK, Song SY, Lee YC, et al. *A case of pneumatosis cystoides intestinalis after cardiac transplantation*. Korean J Gastroenterol 1996;28:732-7.
14. Park HW, Byun SW, Kim JJ, et al. *A case of NK/T-cell lymphoma in a cardiac transplant recipient*. Korean J Intern Med 2006;70:335-40.
15. Song MG, Seo DM, Lee JW, et al. *Cardiac transplantation -1 case report-*. Korean J Thorac Cardiovasc Surg 1993;26:224-7.
16. Billingham ME, Cary NR, Hammond ME, et al. *A working formulation for the standardization of nomenclature in the diagnosis of heart and lung rejection: Heart Rejection Study Group*. J Heart Transplant 1990;9:587-93.

**=국문 초록=**

**배경:** 심장이식이 최근 증가하면서 거부반응과 감염외의 외과적합병증도 증가하고 있다. 이 논문에서는 한 외과외에 실시된 심장이식후에 발생한 외과적합병증을 보고하고자 한다. **대상 및 방법:** 1994년 4월부터 2003년 9월까지 실시된 37명의 심장이식환자를 대상으로 하였으며 심장이식의 적응은 확장성 심근증, 허혈성심근증, 판막심근증, 가족력심근증 등이었다. **결과:** 총 15명의 이식환자에서 20예의 합병증이 발생하였으며 실시된 외과적 수술의 종류는 출혈로 인한 재개흉(5), 심낭액저류배액술(4), 인공박동기거치술(1), 아스페르질루스증에 의한 우하엽절제술(1), 요석제거술(1), 담낭제거술(1), 직장주위절개술(1), 부비동배액술(1), 고관절치환술(1), 치주비대에 의한 치주절개술(1), 뇨도절개술(1), 추간관 탈출증수술(1), 자궁근종으로 인한 자궁적출술(1)이 있었다. 합병증의 위치는 흉곽내가 10예, 흉곽외가 10예였다. **결론:** 심장이식 수술후에는 흉곽 뿐만 아니라 다른 부위장기에 많은 합병증을 가져올 수 있기 때문에 장기생존율을 높이기 위해서는 다학제간의 적극적인 치료가 매우 중요하다.

**중심 단어 :** 1. 심장이식  
2. 합병증