

# Cone-beam Computed Tomography Measurement of the Position of the Inferior Alveolar Nerve Canal in Mandibular Prognathism

Sung-Hun Yun, Ji-Young Park, Young-Kyung Ko\*, Je-Uk Park, Sung-Woon Pyo

Department of Oral and Maxillofacial Surgery, College of Medicine, The Catholic University of Korea,

\*Department of Periodontics, College of Medicine, The Catholic University of Korea

## Abstract

**Background and Objectives:** To determine the anatomic position of the inferior alveolar nerve (IAN) canal in patients with mandibular prognathism using the cone-beam CT (CBCT). **Materials and Methods:** Fifty rami from 25 patients were evaluated. The images were taken by i-CAT and reconstructed 3-dimensionally using the Simplant 11 program. The linear distances between the IAN canal to the buccal cortex (a, a' and a''), from the IAN canal to the alveolar crest (b and b') and the anterior margin (b'') and finally the buccal cortical thickness (c, c' and c'') were measured at three reference planes (VP, OP and HP). **Results:** On the left side, the average distance of a, b and c were 7.12, 15.96 and 3.60 mm on the VP plane, respectively. On the OP, the distance of a', b' and c' was 6.11, 8.83 and 2.63 mm. For the HP, the distance of a'', b'' and c'' was 4.84, 10.11 and 2.30 mm. On the right side, the distance of a, b and c, on the VP, was 7.10, 16.13 and 3.42 mm, respectively. On the OP, the distance of a', b' and c' was 4.77, 8.75 and 2.68 mm. On the HP, the distance of a'', b'' and c'' was 4.55, 9.84 and 2.38 mm. Regarding the difference between genders, the distance in male's was longer than female's on the VP (p=0.019), and was thicker in males than females on the HP (p=0.002). **Conclusion:** The CBCT data provided accurate information about the location and course of the IAN.

### Key words

Cone beam computed tomography, Inferior alveolar nerve, Mandibular prognathism

## INTRODUCTION

Patients with mandible prognathism frequently undergo orthognathic surgery to restore an esthetic profile and normal masticatory function following the completion of growth. The most widely used method for correction of mandibular discrepancies is the sagittal split ramus osteotomy (SSRO).<sup>1)</sup> The safety of this surgery has been established; however, the inferior alveolar nerve (IAN) is susceptible to injury when a saw or an osteotome is used to split the mandible, since the nerve runs into the mandible.<sup>2,3)</sup> According to prior investigators, the incidence of neurological disturbances in the lower lip and chin has been reported to be 30-40%.<sup>4,5)</sup> Therefore, to prevent such complications, including abnormal sensation following this surgery, it is essential to completely understand the anatomical

location and course of the IAN canal in patients scheduled to undergo this surgery. In order to identify the course of this nerve preoperative radiological evaluation is critical.

Previous attempts to understand the course of the IAN canal, in the posterior mandible, have been made primarily in cadavers.<sup>6-8)</sup> Since the age and gender have not been recorded in many of these studies, the standards cannot be adopted for young patients with maxillofacial anomalies. In addition, prior studies have used the conventional helical fan-beam computed tomography (CT), commonly used for radiological diagnosis, to examine the location of the IAN canal in patients with mandibular prognathism.<sup>9,10)</sup> Based on the findings of the fan-beam CT, however, only the bucco-lingual positional relationship between the mandibular buccal cortex and the IAN canal could be measured, and the overall course was estimated in the axial plane.

With recent advances in medical imaging technology, the cone-beam CT has been developed, which is useful for radiological diagnosis in the field of dentistry.<sup>11,12)</sup> The major advantages of the cone-beam CT are its high spatial resolution and low radiation dose. Some experimental studies have confirmed

\* Corresponding author

### Sung-Woon Pyo

Dept. of OMFS Holy Family Hospital, The Catholic University of Korea  
2 Sosa-dong, Wonmi-ku, Puchon, Kyunggi-do, Korea 420-717  
Tel: +82-32-340-2130 Fax: +82-32-340-2135  
E-mail: spyo@catholic.ac.kr

the geometric accuracy of the cone-beam CT.<sup>13,14)</sup> Due to the development of multi-planar reformation visualizing techniques, and 3-dimensional imaging software, preoperative simulation as well as the intra-operative navigation have been achieved.<sup>11)</sup> In addition, it can obtain accurate images from all directions without distortion.<sup>15)</sup> Thus, it is possible to measure the length and area that cannot be achieved by two-dimensional uni-planar images. Furthermore, it is possible to make a diagnosis and develop a treatment plan in the three-dimensional setting.

The aim of the current study was to assess the anatomic position and course of the IAN canal using the cone-beam CT, with the advantages described above and the 3-dimensional reformation program, in patients with mandibular prognathism. In addition, the definition and optimal locations for completing the cortical cuts and splitting the mandible were assessed for reduction of neurological complications.

## MATERIALS AND METHODS

### 1. Subjects

This study was conducted on patients with mandibular prognathism who consulted the department of oral and maxillofacial surgery for orthognathic surgery. Among the cone beam CT scans that were taken for diagnosis and treatment planning, in these patients, those with no missing teeth in the mandibular molar region or asymmetry were selected for further evaluation. The number of samples included 50 rami from 25 patients (12 males and 13 females). The age distribution ranged from

**Table 1.** Descriptive statistics of the study variables

Variables	Number
Samples (n)	Right=25, Left=25
Age (years, range)	24±4.5 (18-36)
Gender	
Male	12
Female	13

**Table 2.** Measurements of the study variables (Mean±SD)<sup>a</sup>

	VP			OP			HP		
	<i>a</i>	<i>b</i>	<i>c</i>	<i>a</i> <sup>†</sup>	<i>b</i> <sup>†</sup>	<i>c</i> <sup>†</sup>	<i>a</i> <sup>†</sup>	<i>b</i> <sup>†</sup>	<i>c</i> <sup>†</sup>
Right	7.12±1.76	16.13±3.56	3.42±0.46	4.77±2.43	8.75±2.03	2.68±0.59	4.55±1.16	9.84±2.54	2.38±1.04
Left	7.12±1.65	15.96±3.72	3.60±0.51	6.11±4.45	8.83±2.47	2.63±0.56	4.84±1.33	10.11±2.19	2.30±0.41

<sup>a</sup> SD: standard variation, VP: Vertical cross sectional plane, OP: Oblique cross sectional plane, HP: Horizontal cross sectional plane, *a*, *a*<sup>†</sup>, and *a*<sup>†</sup>: the distance from IAN canal to buccal cortical bone, *b*, *b*<sup>†</sup> and *b*<sup>†</sup>: the distance from IAN canal to superior alveolar crest (or anterior ridge), *c*, *c*<sup>†</sup> and *c*<sup>†</sup>: the thickness of buccal cortical bone.

18 to 36 (a mean age of 24±4.5 years) (Table 1). The current study was approved by the Institutional Review Board and a signed consent form was obtained from all participants.

### 2. Methods

#### 1) Images

The imaging instruments were part of an i-CAT (Imaging Sciences International, Inc., Hatfield, USA) cone beam CT unit. In the i-CAT cone beam CT unit, the size of the volume place was set at 0.2 mm. The imaging conditions included a tube voltage of 120 kVp, tube current of 6.5 mA and an exposure time of 40 seconds. The CT data obtained was reformed into a three-dimensional image using Simplant 11 (CyberMed Inc., Seoul, Korea) software. The images were cut using a remove scatter device to make a cross sectional view along the area of measurement, which was visualized on a high-resolution CRT monitor for interpretation.

#### 2) Measurements of the Cone beam CT data

The reference plane was set at the vertical plane (VP) that vertically cuts the area between the mandibular first molar and the second molar, the oblique plane (OP) that cuts across the mandibular angle and the deepest part of external oblique ridge, and the horizontal plane (HP) that cuts inferior to the lingula transversely (Fig.1). On each plane, the distance from the mandibular buccal cortical bone to the IAN canal (*a*, *a*<sup>†</sup> and *a*<sup>†</sup>), between the IAN canal and its superior (or anterior) alveolar crest (*b*, *b*<sup>†</sup> and *b*<sup>†</sup>) and the thickness of the buccal cortical bone (*c*, *c*<sup>†</sup> and *c*<sup>†</sup>) were measured (Fig. 2).

The measurements were made using a caliper with 0.01 mm units. All the assessments of the images and measurements were conducted by two observers under identical conditions; the establishment of landmarks was performed after agreement was reached between the two observers.

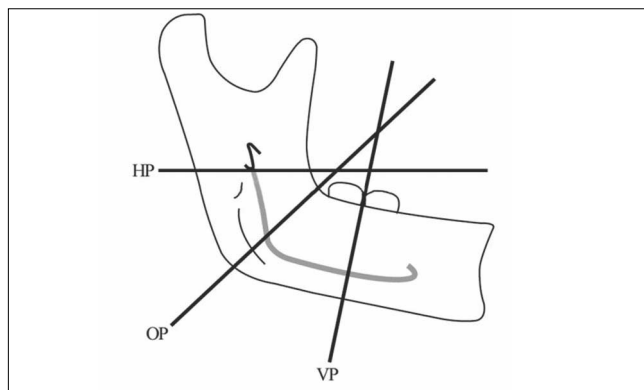
#### 3) Statistical analysis

The reproducibility of the measurements between the observers was tested using kappa values. Each measurement

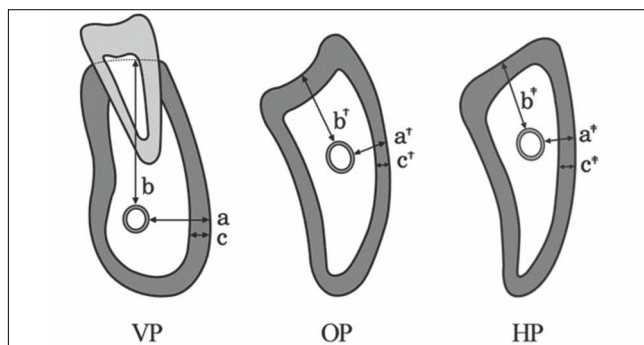
**Table 3.** Average difference in the measurement values of the inferior alveolar nerve canal between genders<sup>a</sup>

Variables		Average difference	
		Right	Left
VP	a	0.81	-1.23
	b	1.6	0.04
	c	2.43*	-2.77
OP	a <sup>†</sup>	0.92	1.82
	b <sup>†</sup>	0.92	0.25
	c <sup>†</sup>	-0.17	-1.32
HP	a <sup>†</sup>	-1.04	-0.123
	b <sup>†</sup>	1.28	3.32**
	c <sup>†</sup>	-1.4	-1.26

<sup>a</sup>VP: Vertical cross sectional plane, OP: Oblique cross sectional plane, HP: Horizontal cross sectional plane, a, a<sup>†</sup> and a<sup>†</sup>: the distance from IAN canal to buccal cortical bone, b, b<sup>†</sup> and b<sup>†</sup>: the distance from IAN canal to superior alveolar crest (or anterior), c, c<sup>†</sup> and c<sup>†</sup>: the thickness of buccal cortical bone, (+):larger measurement value of male, (-):larger measurement value of female, \*p<0.05, \*\*p<0.01.



**Fig. 1.** Diagram showing the location of the three sections through the mandible VP: Vertical cross sectional plane between the mandibular first and second molar, OP: Oblique cross sectional plane across the mandibular angle and the deepest curvature of the external oblique ridge, HP: Horizontal cross sectional plane inferior to the lingula.



**Fig. 2.** Diagram showing the measurement of thickness and distance a, a<sup>†</sup> and a<sup>†</sup>: the distance from the buccal cortical bone surface to the inferior alveolar nerve canal, b and b<sup>†</sup>: distance from inferior alveolar canal to its superior (or anterior) alveolar crest, b<sup>†</sup>: distance from inferior alveolar canal to the anterior alveolar bone crest, c, c<sup>†</sup> and c<sup>†</sup>: the thickness of buccal cortical bone.

was obtained on each reference plane, whose mean and standard deviation were calculated. A frequency analysis for each measurement was conducted. The difference depending on gender was compared and a p-value less than 0.05 was considered as a statistically significant difference. Statistical analysis was performed using SAS 8.0 software (SAS Korea, Seoul, Korea).

## RESULTS

The Kappa test ratio ranged between 0.67 and 0.9. This showed relatively good to excellent agreement for the two examiners.

### 1. Measurement of the locations of the IAN canal

Analysis of the descriptive statistics of the locations of the IAN canal was performed for the measurements obtained in the left mandible, which showed a normal distribution. The mean values on each reference plane were as follows: a=7.12 mm, b=15.96 mm and c=3.60 mm on the VP; a<sup>†</sup>=6.11 mm, b<sup>†</sup>=8.83 mm and c<sup>†</sup>=2.63 mm on the OP; and a<sup>†</sup>=4.84 mm, b<sup>†</sup>=10.11 mm and c<sup>†</sup>=2.30 mm on the HP. The measurement for the right mandible also showed a normal distribution. The mean values for each reference plane were as follows: a=7.12 mm, b=16.13 mm and c=3.42 mm on the VP; a<sup>†</sup>=4.77 mm, b<sup>†</sup>=8.75 mm and c<sup>†</sup>=2.68 mm on the OP; and a<sup>†</sup>=4.55 mm, b<sup>†</sup>=9.84 mm and c<sup>†</sup>=2.38 mm on the HP (Table 2).

### 2. Gender differences for the locations of the IAN canal

The mean distance from the mandibular buccal cortical bone to the IAN on the HP was 11.07 mm in males and 9.20 mm in female for the left side of the mandible; this demonstrated a significantly longer measurement in males than in females (p=0.002). However, the other mean values did not reach statistical significance. In regard to the right mandible, the mean thickness of the buccal cortical bone at the VP was 3.58 mm in males and 3.27 mm in females; significantly thicker in males than in females (p=0.019). The other mean values were longer or thicker in males than in females; however, there was no significant difference in this series (Table 3).

## DISCUSSION

The results of the current study corroborate the diagnostic accuracy of the cone-beam CT for the prediction of the IAN location and course, and provide clinically significant informa-

tion. The cone-beam CT, recently developed and applied in the clinical setting, has been recognized as a novel diagnostic tool in the fields of oral and maxillofacial medicine.<sup>11,12,16</sup> The cone-beam CT can enhance the diagnosis by providing high spatial resolution based on the multi-planar image reformation from three dimensional volumetric information composed of isometric voxels.<sup>14</sup> Moreover, its absorption dose and effective dose of radiation have been reported to be markedly lower compared to conventional plain radiography.<sup>17</sup> Accordingly, the cone-beam CT makes it possible to use radiography without increased concern for the accumulation of the radiation dose prior to or following orthognathic surgery, as well as for the evaluation of relapse on a regular basis. Nevertheless, despite these advantages, low doses of radiation can increase the noise of the imaging signal and thereby lower the quality of the imaging data.<sup>18</sup> It is thus essential to establish the exposure conditions that are optimal for obtaining high-quality imaging scans for the cone-beam CT. In five of 30 initial cone-beam CT scans, the IAN canal was not clearly visualized in some areas. These cases were therefore excluded from the analysis. However, these exclusions were because an accurate measurement could not be obtained at a certain location; there were no cases in which the overall pathway could not be seen.

In an attempt to minimize nerve injury while performing the SSRO, a number of studies have been conducted to examine the pathway of the IAN and its exact location within the mandible.<sup>9,10,19</sup> Rajchel et al. reviewed the anatomical buccolingual location of the IAN canal in the mandible of 45 Asian adults and reported that the distance between the buccal cortical bone and the IAN canal was the greatest in the area between the mandibular first and second molars. In addition, they noted that the IAN canal was the smallest at the mandibular third molar.<sup>19</sup> Furthermore, in our current study, the distance was the greatest at this position in both the left and right mandible. According to the studies conducted by Yamamoto et al., contact between the IAN canal and the buccal cortical bone was identified in the mandibular ramus in 25% (10/40) of cases.<sup>9</sup> However, their studies were restricted to the mandibular ramus. Here we investigated the relationship of the IAN canal in the mandibular body and the mandibular angle as well as at the lingula transverse section, to explore the entire pathway of the IAN canal. Among the 50 mandibular planes, three had contact between the inferior alveolar canal and the cortical bone in the VP, 10 (25%) in the OP and four (8%) in the HP. As the reference plane is superiorly moved toward the mandibular angle oblique line and the lingula transverse section, the IAN canal gets closer to the buccal cortical bone. Considering the total course of the IAN canal, it was the clos-

est to the mandibular buccal cortical bone in the mandibular angle oblique plane. This result confirmed the findings of Tsuji et al. that a vertical osteotomy of the buccal side of the mandible must be accomplished in the anterior area rather than the mandibular angle.<sup>10</sup>

It has been documented that the distance between the IAN canal and the superior alveolar ridge is 17.4 mm, with no differences between genders.<sup>20</sup> However, there were no results reported on the mandibular ramus oblique plane, where a reciprocating saw may pass. We therefore measured this distance, and noted that the IAN canal ran closest to the cortical bone on the mandibular angle of the oblique plane. A bone saw must therefore not exceed the measured range when the bone splitting is performed at the mandibular angle. The distance between the IAN canal and the superior alveolar ridge on the VP, in this study, was in agreement with previous studies.

There are numerous studies on the thickness of buccal cortical bone.<sup>18, 21-23</sup> According to CT-based Korean studies, the mean thickness of buccal cortical bone, at the same height as the mandibular canal in the proximal root of the first molar, was  $2.2 \pm 4.2$  mm.<sup>21</sup> In Western countries, Ylikontiola et al. reported that the thickness of buccal cortical bone, at the same height as the mandibular canal, was 2.5 mm on average in the third molar area.<sup>23</sup> In the current study, the mean thickness of the buccal cortical bone was 3.41 mm, on the left, between the first and the second molars; it was 3.57 mm, on the right, where it had the greatest measurements. These areas are favored by most surgeons in the clinical setting to secure a sufficient extent of thickness of the cortical bone so as not to encounter the IAN, and therefore avoid nerve injury. It is also inferred that the fixation of both proximal and distal fragments will be easy in these areas.

In regard to the thickness of cortical bone in association with gender, our previous study noted that the mean thickness of cortical bone was significantly greater in males compared to females. Others have also demonstrated that the mean thickness of the left and right cortical bone showed no statistically significant difference.<sup>24</sup> In our series, the correlation between gender and the thickness of cortical bone did not reach statistical significance. The absence of significant findings could be attributable to the small size of the sample and inherent variability. Therefore, further studies with an increased number of patients are necessary. Based on these findings, further studies in a larger patient population, including patients with other skeletal anomalies as well as those with normal occlusion are warranted for an accurate comparison and assessment.

In conclusion, this study confirms the reliability of the cone-beam CT for assessing the topographic relationship between

the IAN canal and buccal cortical bone.

## REFERENCES

1. MacIntosh RB. Experience with the sagittal osteotomy of the mandibular ramus: A 13-year review. *J Maxillofac Surg.* 1981;9:151-65.
2. Turvey TA. Intraoperative complications of sagittal osteotomy of the mandibular ramus: Incidence and management. *J Oral Maxillofac Surg.* 1985;43:504-9.
3. Acebal-Bianco F, Vuylsteke PL, Mommaerts MY, De Clercq CA. Perioperative complications in corrective facial orthopedic surgery: 5-year retrospective study. *J Oral Maxillofac Surg.* 2000;58:754-60.
4. Westermarck A, Bystedt H, von Konow L. Inferior alveolar nerve function after sagittal split osteotomy of the mandible: Correlation with degree of intraoperative nerve encounter and other variables in 496 operations. *Br J Oral Maxillofac Surg.* 1998;36:429-33.
5. Yoshida T, Nagamine T, Kobayashi T, Michimi N, Nakajima T, Sasakura H, Hanada K. Impairment of the inferior alveolar nerve after sagittal split osteotomy. *J Cranio Maxillofac Surg.* 1989;17:271-7.
6. Tamas F. Position of the mandibular canal. *Int J Oral Maxillofac Surg.* 1987;16:65-9.
7. Gowgiel JM. The position and course of the mandibular canal. *J Oral Implantol.* 1992;18:383-5.
8. Kim HJ, Lee HY, Chung IH, Cha IH, Yi CK. Mandibular anatomy related to sagittal split ramus osteotomy in Koreans. *Yonsei Med J.* 1997;38:19-25.
9. Yamamoto R, Nakamura A, Ohno K, Michi K. Relationship of the mandibular canal to the lateral cortex of the mandibular ramus as a factor in the development of neurosensory disturbance after bilateral sagittal split osteotomy. *J Oral Maxillofac Surg.* 2002;60:490-5.
10. Tsuji Y, Muto T, Kawakami J, Takeda S. Computed tomographic analysis of the position and course of the mandibular canal: relevance to the sagittal split ramus osteotomy. *Int J Oral Maxillofac Surg.* 2005;34:243-6.
11. Arai Y, Tammissalo E, Iwai K, Hahimoto K, Shinoda K. Development of a compact computed tomographic apparatus for dental use. *Dentomaxillofac Radiol.* 1999;28:245-8.
12. Nakajima A, Sameshima GT, Arai Y, Homme Y, Shimizu N, Dougherty H Sr. Two- and three-dimensional orthodontic imaging using limited cone beam-computed tomography. *Angle Orthod.* 2005;75:895-903.
13. Kobayashi K, Shimoda S, Nakagawa Y, Yamamoto A. Accuracy in measurement of distance using limited cone-beam computerized tomography. *Int J Oral Maxillofac Implants.* 2004;19:228-31.
14. Honda K, Larheim TA, Johannessen S, Arai Y, Shinoda K, Westesson PL. Ortho cubic super-high resolution computed tomography; a new radiographic technique with application to the temporomandibular joint. *Oral Surg Oral Med Oral Pathol Oral Radiol Endod.* 2001;91:239-43.
15. Periago DR, Scarfe WC, Moshiri M, Scheetz JP, Silveira AM, Farman AG. Linear accuracy and reliability of cone beam CT derived 3-dimensional images constructed using an orthodontic volumetric rendering program. *Angle Orthod.* 2008;78:387-95.
16. Han SY, Baik HS, Kim KD, Yu HS. Facial soft tissue measuring analysis of normal occlusion using three-dimensional CT imaging. *Korean J Orthod.* 2005;35:409-19.
17. Ludlow JB, Davies-Ludlow LE, Brooks SL, Howerton WB. Dosimetry of 3 CBCT devices for oral and maxillofacial radiology: CB Mercuray, NewTom 3G and i-CAT. *Dentomaxillofac Radiol.* 2006;35:219-26.
18. Lee ET, Kim GT, Choi YS, Hwang EH. Radiation absorbed dose of cone beam computed tomography. *Kor J Oral Maxillofac Radiol.* 2007;37:87-92.
19. Rajchel J, Ellis III E, Fonseca RJ. The anatomical location of the mandibular canal: Its relationship to the sagittal ramus osteotomy. *Int J Adult Orthod Orthognath Surg.* 1986;1:37-47.
20. Levine MH, Goddard AL, Dodson TB. Inferior alveolar nerve position: a clinical and radiographic study. *J Oral Maxillofac Surg.* 2007;65:470-4.
21. Ha SsY, Song NK, Koh KJ. A Computerized Tomographic Study on the Location of the Mandibular Canal and the Cortical Thickness of the Mandible. *Kor J Oral Maxillofac Radiol.* 1997;27:217-30.
22. Carter TB, Frost DE, Tucker MR, Zuniga JR. Cortical thickness in human mandibles: clinical relevance to the sagittal split ramus osteotomy. *Int J Adult Orthod Orthognath Surg.* 1991;6:257-60.
23. Ylikontiola L, Moberg K, Huuonen S, Soikkonen K, Oikarinen K. Comparison of three radiographic methods used to locate the mandibular canal in the buccolingual direction before bilateral sagittal split osteotomy. *Oral Surg Oral Med Oral Pathol Oral Radiol Endod.* 2002;93:736-42.
24. Pyo SW, Kung DH. Cortical thickness measurement of mandibular retromolar area using computerized tomography. *Kor J Oral Maxillofac Implants.* 2006;10:32-40.