

# A Pulmonary Sarcoidosis Manifesting as a Rare Atypical Pattern and Distribution

Departments of <sup>1</sup>Radiology, <sup>2</sup>Pathology, and <sup>3</sup>Internal Medicine, Korea University Guro Hospital, Korea University College of Medicine, Seoul, Korea

Sun-Hwa Hong, M.D.<sup>1</sup>, Eun-Young Kang, M.D.<sup>1</sup>, Ok Hee Woo, M.D.<sup>1</sup>, Hwan Seok Yong, M.D.<sup>1</sup>, Yu-Whan Oh, M.D.<sup>1</sup>, Bong Kyung Shin, M.D.<sup>2</sup>, Jae Jeong Shim, M.D.<sup>3</sup>

## 드문 비전형적인 형태와 분포를 보인 폐 유육종증 1예

홍선화<sup>1</sup>, 강은영<sup>1</sup>, 우옥희<sup>1</sup>, 옹환석<sup>1</sup>, 오유환<sup>1</sup>, 신봉경<sup>2</sup>, 심재정<sup>3</sup>  
고려대학교 의과대학 <sup>1</sup>영상의학교실, <sup>2</sup>병리학교실, <sup>3</sup>내과학교실

A unique case of atypical pulmonary sarcoidosis in a 62-year-old man complaining of dyspnea is presented. Chest CT scan showed an unusual pattern and distribution of pulmonary sarcoidosis manifesting mainly as reticular densities, interlobular septal thickening, and ground-glass opacities, in the subpleural and lower lung predominancy. However, a surgical lung biopsy revealed classical findings of sarcoidosis. Knowledge of this atypical pulmonary involvement may improve understanding sarcoidosis as the great masquerader. (*Tuberc Respir Dis* 2008;64:236-239)

**Key Words:** Sarcoidosis, Pulmonary disease, CT

### Introduction

Sarcoidosis is a systemic granulomatous disease of unknown etiology and can affect any organ system. The thorax is one of the most commonly affected areas, and thoracic involvement is reported in up to 90% of patients with sarcoidosis<sup>1-4</sup>. Thoracic sarcoidosis usually affects the lymph nodes and the lung parenchyma. Radiologic manifestation of thoracic sarcoidosis is well established, and symmetric bilateral hilar and mediastinal lymphadenopathy with or without concomitant lung parenchymal infiltrates is the most common manifestation of thoracic sarcoidosis<sup>1,3</sup>. Although 60% to 70% of patients with thoracic sarcoidosis have characteristic radiologic findings, the remaining patients may have a variety of radiologic findings<sup>5,6</sup>. Furthermore, the appearance of pulmonary sarcoidosis is occasionally very unusual,

nonspecific, and atypical. Therefore, pulmonary sarcoidosis often resembles many other lung diseases.

A rare, atypical case of thoracic sarcoidosis manifesting with an unusual pattern and distribution of lung involvement is reported in this paper.

### Case Report

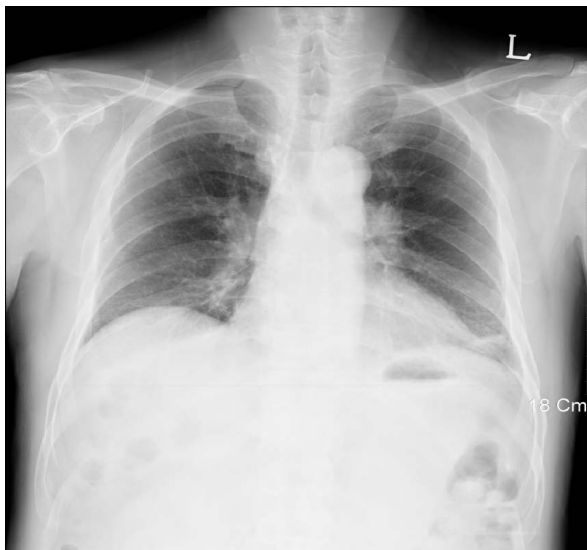A 62-year-old man visited the hospital with a complaint of NIHA class II dyspnea. On auscultation, his breathing sound was normal and on a thorough physical examination, no abnormalities were found. The patient had a past history of hypertension and was an ex-smoker of 40-pack years. In laboratory tests, collagen vascular disease markers were negative.

Simple chest radiography was performed as a routine check-up. Lymph node enlargement was suspected in both hilum (Figure 1). A chest CT scan taken 4 days later showed fine reticular densities, interlobular septal thickenings, and faint ground-glass opacities on both lungs. The lesions were distributed on both lungs symmetrically, but predominant lower and subpleural lung involvement was noted (Figure 2A, B). Discrete lymph node enlargements without internal calcifications were

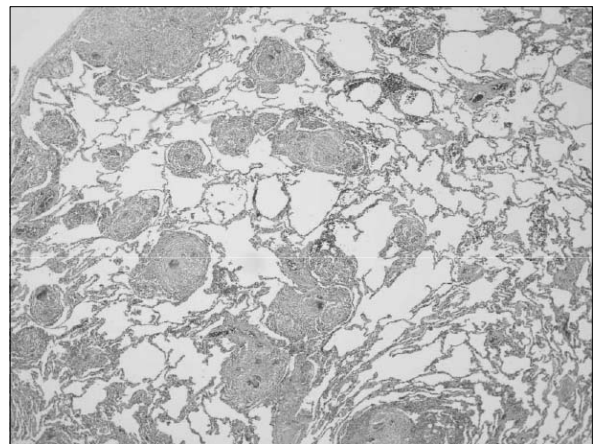
Address for Correspondence: **Eun-Young Kang, M.D.**  
Department of Radiology, Korea University Guro Hospital,  
97 Guro-dong, Guro-gu, Seoul 152-703, Korea  
Phone: 82-2-2626-1342, Fax: 82-2-863-9282  
E-mail: keyrad@korea.ac.kr

Received: Jan. 31, 2008

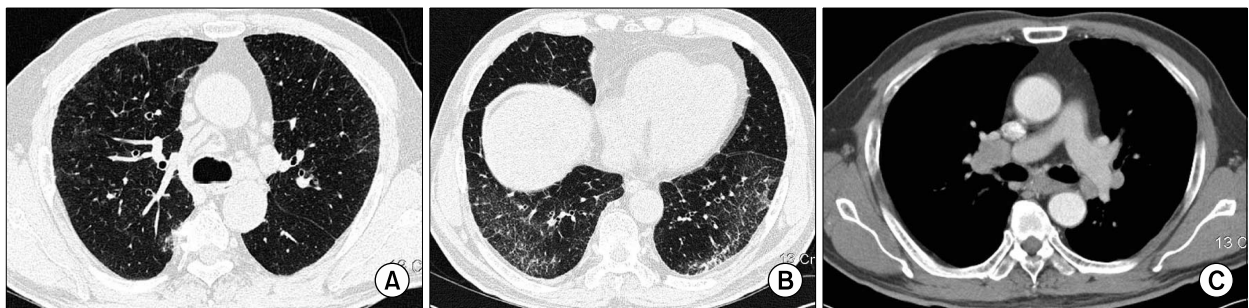
Accepted: Mar. 11, 2008



**Figure 1.** Chest PA view shows bilateral hilar lymphadenopathies.



**Figure 3.** Surgical lung biopsy specimen shows extensive infiltration by noncaseating granulomas distributed along the pleura, interlobular septa, and bronchovascular bundles (H&E stain,  $\times 40$ ).



**Figure 2.** Thin-section CT with lung window setting (A, B) shows fine reticular densities, faint ground-glass opacities, and interlobular septal thickenings on both lungs, predominantly the lower subpleural lung zone. Enhanced chest CT scan with a mediastinal window setting (C) shows bilateral mediastinal and hilar lymphadenopathies.

observed in the prevascular, subaortic, subcarinal, and both paratracheal and hilar areas (Figure 2C). Thus, with the presumptive diagnosis of idiopathic interstitial pneumonia such as nonspecific interstitial pneumonitis and lymphocytic interstitial pneumonia, or lymphoma, a surgical lung biopsy was performed on the left upper and lower lobes. A mediastinoscopic biopsy was also performed on the right paratracheal lymph nodes. However, the result of the lung biopsy revealed extensive infiltration by noncaseating granulomas distributed along the pleura, interlobular septa, and bronchovascular bundles, which are characteristic findings of pulmonary sarcoidosis (Figure 3). A mediastinal lymph node

biopsy also revealed noncaseating chronic granulomatous inflammation consisting of sarcoidosis.

## Discussion

The CT features of pulmonary sarcoidosis include micronodules and nodules, central peribronchovascular thickening, alveolar or pseudoalveolar consolidations, septal and nonseptal lines, ground-glass opacity, conglomerate masses, lung architectural distortion, bronchiectasis, honeycombing or other types of cyst, emphysema, and thickening of the pleural surface<sup>1</sup>. Pulmonary sarcoidosis is typically bilateral and symmetric, and in-

volves mainly the central rather than peripheral lungs. The upper lobes, particularly the apical and posterior segments, are the most severely affected<sup>2</sup>.

The most characteristic CT appearance of pulmonary sarcoidosis consists of small nodules in a perilymphatic distribution<sup>1,2,6</sup>. Small nodules usually have irregular margins and range from 1 to 10 mm in size. They are typically scattered throughout the interstitium of the lungs, along the lymphatics, particularly in the peribronchovascular and subpleural spaces, and along the interlobular septa. Pathologically, noncaseating granulomas distribute mostly along the lymphatics in the peribronchovascular sheath and, to a lesser extent, in the subpleural and interlobular septal lymphatics<sup>6,7</sup>. However, the diseases in lymphatic and perilymphatic distribution include lymphangitic carcinomatosis, lymphoproliferative disease, silicosis, and amyloidosis as well as sarcoidosis. Therefore, CT findings of these diseases can be similar to that of sarcoidosis<sup>3,8</sup>. Sarcoidosis is more significantly involved bilaterally and in the upper lungs than lymphangitic carcinomatosis and malignant lymphoma. Thickened interlobular septa observed in lymphangitic carcinomatosis are rare in sarcoidosis<sup>8</sup>. Lymphoma may present with predominant peribronchovascular nodules but are typically larger and less profuse than sarcoidosis. Silicosis also shows perilymphatic nodules, but the distinction can be made easily by clinical history. Thus, sarcoidosis can usually be differentiated from these diseases.

Sarcoid granulomas can coalesce and become confluent to produce large nodules and alveolar opacities. The alveolar opacities vary in size from 1~10 cm, are bilateral with ill-defined borders, and may show internal air bronchograms. This peripheral nonsegmental airspace consolidation is called alveolar sarcoidosis. Pulmonary sarcoidosis sometimes shows patchy areas of ground-glass opacity, which may be superimposed on a background of interstitial nodules or fibrosis. Other CT findings include solitary or multiple pulmonary masses, atelectasis, focal or asymmetric alveolar or interstitial disease. Pulmonary sarcoidosis can show miliary nodules located in a random distribution. This miliary pattern can show

similar findings of miliary tuberculosis, miliary fungal infection, and hematogenous metastasis.

Pulmonary sarcoidosis may resolve spontaneously or progress to fibrosis. As fibrosis progresses, irregular reticular densities, lung parenchymal distortions with large conglomerate mass, and lung volume loss are predominant. These findings can be associated with traction bronchiectasis and peripheral honeycombing<sup>2</sup>.

In the present case, fine reticular densities and interlobular septal thickening with basal subpleural distribution, and faint ground-glass opacity without a background of visible interstitial nodules rendered a diagnosis of sarcoidosis difficult. Furthermore, areas of ground-glass attenuation and reticular opacities distributed peripherally in both lower lung zones were contrary to the upper and central lung distribution pattern of classic pulmonary sarcoidosis. These are the dominant CT findings among patients with nonspecific interstitial pneumonia, and they are similar to lymphocytic interstitial pneumonia, which manifests with diffuse ground-glass attenuation, poorly defined centrilobular nodules, thickening of perilymphatic interstitium, septal thickening, and scattered thin-walled cysts with lower lung zone predominance<sup>9</sup>. Hence, an initial diagnosis was made of idiopathic interstitial pneumonia, such as nonspecific interstitial pneumonia and lymphocytic interstitial pneumonia, rather than sarcoidosis in this case. Therefore, a surgical lung biopsy was performed in the left upper and lower lobes to make a diagnosis. However, histologically, the pathologic specimen showed classical findings of pulmonary sarcoidosis.

## Summary

In this report, a rare atypical case of pulmonary sarcoidosis manifesting mainly as reticular densities, interlobular septal thickening, with ground-glass opacities, in subpleural and lower lung predominancy is presented. Pulmonary sarcoidosis can mimic other lung diseases radiologically and cause radiologic diagnostic uncertainties. Awareness of the diverse manifestations as well as typical manifestations can help prevent unnecessary

procedures in patients with sarcoidosis.

### References

1. Nunes H, Brillet PY, Valeyre D, Brauner MW, Wells AU. Imaging in sarcoidosis. *Semin Respir Crit Care Med* 2007;28:102-20.
2. Vagal AS, Shipley R, Meyer CA. Radiological manifestations of sarcoidosis. *Clin Dermatol* 2007;25:312-25.
3. Koyama T, Ueda H, Togashi K, Umeoka S, Kataoka M, Nagai S. Radiologic manifestations of sarcoidosis in various organs. *Radiographics* 2004;24:87-104.
4. Hennebicque AS, Nunes H, Brillet PY, Moulahi H, Valeyre D, Brauner MW. CT findings in severe thoracic sarcoidosis. *Eur Radiol* 2005;15:23-30.
5. Hamper UM, Fishman EK, Khouri NF, Johns CJ, Wang KP, Siegelman SS. Typical and atypical CT manifestations of pulmonary sarcoidosis. *J Comput Assist Tomogr* 1986;10:928-36.
6. Müller NL, Kullnig P, Miller RR. The CT findings of pulmonary sarcoidosis: analysis of 25 patients. *AJR Am J Roentgenol* 1989;152:1179-82.
7. Nishimura K, Itoh H, Kitaichi M, Nagai S, Izumi T. Pulmonary sarcoidosis: correlation of CT and histopathologic findings. *Radiology* 1993;189:105-9.
8. Honda O, Johkoh T, Ichikado K, Yoshida S, Mihara N, Higashi M, et al. Comparison of high resolution CT findings of sarcoidosis, lymphoma, and lymphangitic carcinoma: is there any difference of involved interstitium? *J Comput Assist Tomogr* 1999;23:374-9.
9. Johkoh T, Müller NL, Pickford HA, Hartman TE, Ichikado K, Akira M, et al. Lymphocytic interstitial pneumonia: thin-section CT findings in 22 patients. *Radiology* 1999;212:567-72.