

## A Study of the Adjustment and Treatment Depending on the Change of Prostate Location Using DIPS in Proton Beam Therapy for Prostate Gland in which a Fiducial Gold Marker was Inserted

June-Ki Park, Sun-Young Kim, Tae-Yoon Kim, Kye-Sook Choi, Doo-Suk Yeom,  
Dong-Yoon Kang, Seung-O Choi, Ji-Youn Park

Center For Proton Therapy, National Cancer Center, Goyang, Korea

**Purpose:** To monitor the changes of location of prostate gland using DIPS and to examine the adjustment and proton beam therapy depending on the movement of prostate gland in proton beam therapy for prostate gland in which a fiducial gold marker was inserted.

**Materials and Methods:** This study was conducted in ten patients with prostate cancer who received proton beam therapy since April of 2008. To monitor the change of prostate location, three fiducial gold markers were inserted prior to the treatment. To minimize the movement of prostate gland, patients were recommended to urinate prior to the treatment, to intake a certain amount of water and to concomitantly undergo rectal balloon. In these patients, the set-up position was identical to that for a CT-simulation. The PA (posterior-anterior) and lateral images were obtained using both DIPS (digital image positioning system) and a plain radiography, and they were compared between the two imaging modalities. Thus, the changes of the location of fiducial gold marker were assessed based on three coordinates (x, y, z) and then adjusted. This was followed by proton beam therapy.

**Results:** Images which were taken using a plain radiography were compared with those which were taken using DIPS. In ten patients, according to a reference bony marker, the mean changes of the location of fiducial gold marker based on an iso-center were X-axis:  $\pm 0.116$  cm, Y-axis:  $\pm 0.19$  cm and Z-axis:  $\pm 0.176$  cm. These ten patients showed a difference in the changes of location of prostate gland and it ranged between RT: 0.04 cm and RT: 0.24 cm on the X-axis; between Inf: 0.03 cm and Sup: 0.42 cm on the Y-axis; and Post: 0.05 cm and Ant: 0.35 cm on the Z-axis.

**Conclusion:** To minimize the movement of prostate gland, as the pre-treatment prior to the treatment, in all the patients, however, three fiducial gold markers showed a daily variation which were inserted in the prostate gland. Based on the above data, thus, the requirement of gold marker matching system depending on the daily variation in the proton beam therapy for which more accurate establishment of target was confirmed. It is assumed that an accurate effect of proton beam therapy would be enhanced by adjusting the target-center depending on the location change of prostate gland using DIPS which was used in the current study.

**Key words:** proton therapy, prostate, DIPS (digital image positioning system), fiducial gold marker, daily variation

### INTRODUCTION

Currently in western countries, the most prevalent cancer that occurs in men is prostate cancer. To date, the incidence

of prostate cancer has been lower in Korea than western countries. In recent years, however, its incidence is gradually increasing because of westernized eating habits and prolonged life span. With the early diagnosis of prostate cancer based on the interest in it, the number of patients with prostate cancer will be further increased.<sup>2)</sup> Previously, the standard treatment regimen for prostate cancer has been 3D-CRT. Recently in Korea, however, with the introduction of proton therapy

이 논문은 2007년 11월 10일 접수하여 2008년 1월 7일 채택되었음.  
책임저자 : 박준기, 국립암센터 양성자치료센터  
Tel: 031)920-0487, Fax: 031)920-0149  
E-mail: park5518@hanmail.net

equipment, the interest in proton beam therapy has been increasing. In all the radiotherapies, it is essential to minimize the movement of treatment area.<sup>3)</sup> Particularly in proton beam therapy where Bragg-Peak is present, efforts must be made to minimize the errors due to the status of rectum and urinary bladder and those due to such factors as set-up.

Given this background, prior to the treatment, we adjusted the movement of prostate using DIPS based on three reference fiducial gold markers so that the change of prostate location may be monitored during the treatment.<sup>7)</sup> Thus, we attempted to examine the proton beam therapy in a more accurate, efficient manner.

## MATERIALS AND METHODS


### 1. CT-simulation & Pre-treatment

Of 20 patients with prostate cancer who received proton beam therapy at our hospital between April and September of

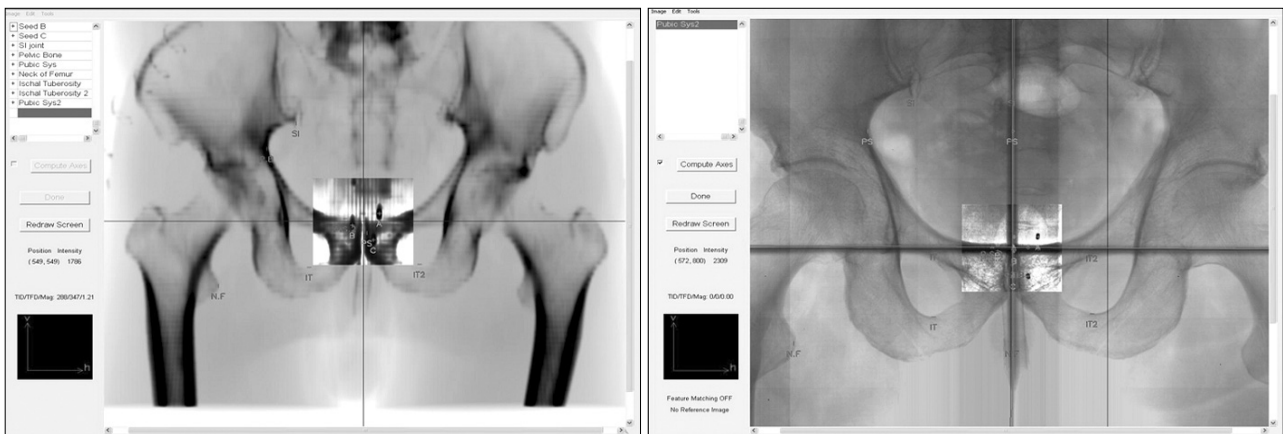2008, ten were enrolled in the current study. Prior to proton beam therapy, to mark the location of tumor in a more accurate manner, three fiducial gold markers were inserted to the site of prostate tumor under the ultrasonographic guidance (Fig. 1). Prior to CT-Simulation, to minimize the movement of prostate gland, the pre-treatment was done. For the pre-treatments, patients were recommended to urinate and evacuate one hour prior to CT-Simulation and to intake a 300 cc of water. Prior to CT-Simulation, the final pre-treatments include a rectal balloon and this was followed by CT-Simulation. At this time, a rectal balloon was performed using a 100 cc of saline. A set-up position of patients was established with a dual leg in a supine position (Fig. 2).



**Fig. 1.** Gold marker: Three fiducial gold markers were inserted to the site of prostate tumor under ultrasonographic guidance.



**Fig. 2.** The patient's set-up position & acquire the DIPS image: The position established with a dual leg in a supine position. Images which were taken using DIPS on the posterior-anterior and lateral side.



**Fig. 3.** The PA (posterior-anterior) image in DIPS.

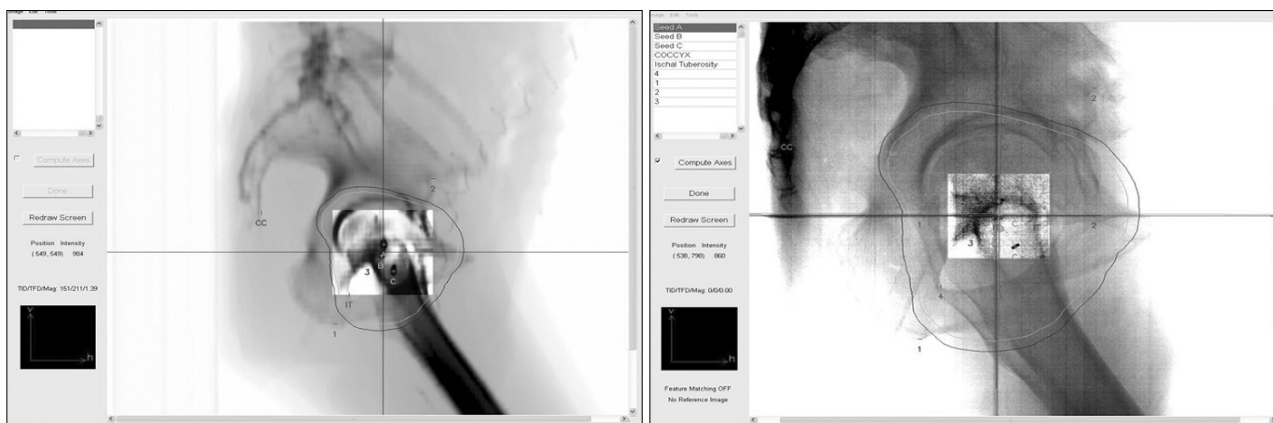


Fig. 4. The lateral image in DIPS.

```

Setup(Seed) Corrections to 31274829 position:
(cm/deg)  (seed)    (anat)    (diff)
Dx        0.12     0.04     0.08
Dy        0.04     0.03     0.02
Dz        0.18     0.27    -0.09
Drot              -0.1
Dpitch           0.2
Droll            0.1
    
```

Fig. 5. The measurements for the change of prostate location: According to a reference bony marker, the changes of location of fiducial gold marker were monitored and then recorded based on three coordinates.

## 2. Position Correction & Proton Therapy

In the same posture that was first used to perform a CT-Simulation during the treatment, a set-up position of patients was established. Then, in the same method, a rectal balloon was performed. To make sure that the posture of patients and the location of fiducial gold marker which was inserted in the prostate gland is always consistent with the posture and location which were used for a CT-Simulation prior to the treatment, DIPS was used. Images which were taken using DIPS on the posterior-anterior and lateral side of patients were compared with those using a plain radiography (Fig. 3, 4). Then, according to a reference bony marker, the changes of the location of fiducial gold marker were monitored and then

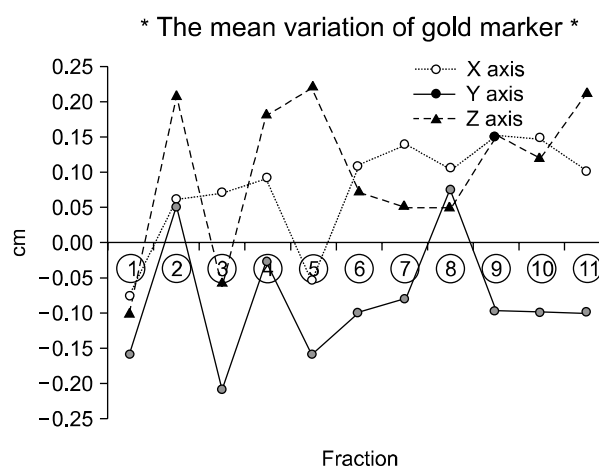


Fig. 6. The table showed a difference in the changes of location of prostate gland in ten patients.

recorded based on three coordinates (X, Y, Z) (Fig. 5). Then, the measurements for the change of location were entered into DIPS when each patient was treated. Thus, the prostate of patients was adjusted and the treatment was performed.

## RESULTS

With the use of a CT-simulation, images which were taken using a plain radiography were compared with those which were taken using DIPS following a pre-treatment set-up. In ten patients, according to a reference bony marker, the mean changes of the location of fiducial gold marker based on an iso-center were X-axis:  $\pm 0.116$  cm, Y-axis:  $\pm 0.19$  cm and Z-axis:  $\pm 0.176$  cm. These ten patients showed a difference in

the changes of location of prostate gland and it ranged between RT: 0.04 cm and RT: 0.24 cm on the X-axis; between Inf: 0.03 cm and Sup: 0.42 cm on the Y-axis; and Post: 0.05 cm and Ant: 0.35 cm on the Z-axis (Fig. 6).

## DISCUSSION AND CONCLUSION

Unlike the conventional photon therapy, proton beam therapy is advantageous in more protecting normal tissue with the use of Bragg-peak and performing a more accurate treatment for malignant tumor. The objectives of the current study lie in adjusting the location change of moving prostate gland for every treatment and thereby enhancing the effectiveness of proton beam therapy. To minimize the movement of prostate gland, as the pre-treatment prior to the treatment, patients were recommended to urinate and evacuate, to intake a certain amount (300 cc) of water on a daily basis and to undergo a rectal balloon with the use of a 100 cc of saline. In all the patients, however, three fiducial gold markers showed a daily variation which were inserted in the prostate gland. As compared with Radio-Therapy, proton beam therapy, a high-energy treatment, requires more accurate establishment of target.<sup>2)</sup> Thus, the requirement of gold marker matching system depending on the daily variation in the proton beam therapy was confirmed.

It is assumed that an accurate effect of proton beam therapy would be enhanced by adjusting the target-center depending on the location change of prostate gland using DIPS which was used in the current study.

## REFERENCES

1. Kupelian P, Langen K, Willoughby P: Image-guided radiotherapy for localized prostate cancer: treating a moving target. *Semin Radiat Oncol* 2008;18:58-66
2. McNair A, Hansen V, Parker C: A comparison of the use of bony anatomy and internal markers for offline verification and an evaluation of the potential benefit of online and offline verification protocols for prostate radiotherapy. *Radiation Oncology* 2008;71:41-50
3. Kotte A, Hofman P: Intrafraction motion of the prostate during external-beam radiation therapy : analysis of 427 patient with implanted fiducial markers. *Radiation Oncology* 2007;69:419-425
4. John M, Herman M, Kruse J: Prostate position relative to pelvic bony anatomy based on intraprostatic gold markers and electronic portal imaging. *Radiation Oncology* 2005;63:800-811
5. Lee J, Chen W, Sause T: Image guided radiation therapy for prostate cancer using implanted fiducial markers with daily portal imaging. *Radiation Oncology* 2007;69(Suppl):815-823
6. Chen J, Lee R, Handrahan D: Intensity-modulated radiotherapy using implanted fiducial markers with daily portal imaging: assessment of prostate organ motion. *Radiation Oncology* 2007;68:912-919
7. Nederveen A, Lagendijk J, Hofman P: Detection of fiducial gold markers for automatic on-line megavoltage position verification using a marker extraction kernel *Radiation Oncology* 2005;47:800-811
8. Pollack A, Zagars GK, Starkschall G, et al.: Prostate cancer radiation dose response: result of the m.d anderson phase iii randomized trial. *Int J Radiation Oncology Biol Phys* 2002 53:1097-1105
9. Antolak JA, ROSEN II, Childress CH, et al.: Prostate target volume variations during a course of radiotherapy. *Int J Radiat Oncol Biol Phys* 1998;42:661-672
10. Hanks GE, hanlon AL, Epstein B, et al.: Dose response in prostate cancer with 8-12 years follow up. *Int J Radiat Oncol Biol Phys* 2002;54:427-435
11. Dawon LA, Franssen E, Morton G: Target position variability throughout prostate radiotherapy. *Int J Radiat Oncol Biol Phys* 1998;42:1155-1161
12. Smitsmans MHP, Wolthaus JWH, Artignan X, et al.: Automatic localization of the prostate for on-line or off-line image guided radiotherapy. *Int J Radiat Oncol Biol Phys* 2004 60:623-635

## Abstract

## Fiducial Gold Marker가 삽입된 전립선암 양성자 치료 시 Digital Image Positioning System (DIPS)을 이용한 전립선의 위치변화에 따른 보정에 관한 연구

국립암센터 양성자치료센터

박준기 · 김선영 · 김태윤 · 최계숙 · 염두석 · 강동윤 · 최승오 · 박지연

**목 적:** Fiducial Gold Marker가 삽입된 전립선암 양성자 치료 시 DIPS를 이용하여 전립선의 위치변화를 관찰하고, 전립선의 움직임에 따른 보정 및 양성자치료에 관한 연구를 하고자 한다.

**대상 및 방법:** 2008년 4월 이후로 본원에서 양성자치료를 받은 10명의 전립선암환자를 대상으로 하였다. 전립선의 위치변화를 관찰하기 위해 치료 전에 전립선에 3개의 Fiducial Gold Marker를 삽입하였고, 전립선의 움직임을 최소화하기 위해 치료 전에 소변을 보고, 매일 정량의 물을 섭취하며, Rectal balloon을 함께 시행하였다. 환자의 처음 치료자세는 CT 모의치료 때와 같고, DIPS (Digital Image Positioning System)를 이용하여 AP, Lat 촬영을 하여 얻은 영상과 치료계획에서 얻은 PA, Lat 영상을 비교하여, Fiducial Gold Marker 위치변화(X, Y, Z) 관찰하였고, 이에 따른 보정 후에 양성자치료를 시행하였다.

**결 과:** 치료계획에서 얻은 영상과 DIPS를 이용하여 얻은 영상의 각각의 Fiducial Gold Marker의 위치변화 차이는 10명 환자에 있어서 치료 중심을 기준으로 평균 X축:  $\pm 0.116$  cm, Y축:  $\pm 0.19$  cm, Z축:  $\pm 0.176$  cm이었다. 10명의 환자 중 X축으로 최고 RT: 0.24 cm, 최저 RT: 0.04 cm의 위치변화 차이가 나타났고, Y축으로 최고 Sup: 0.42 cm, 최저 Inf: 0.03 cm 위치변화 차이가 나타났고, Z축으로 최고 Ant: 0.35 cm, 최저 Post: 0.05 cm의 위치변화 차이가 관찰되었다.

**결 론:** 전립선의 움직임을 최소화 하기위해 치료 전에 전처치로 소변을 보고, 매일 정량의 물을 섭취하며, Rectal balloon을 시행하였으나, 모든 환자의 경우에서 전립선에 삽입된 3개의 Fiducial Gold Marker의 매일 움직임을 관찰할 수 있었다. 위 자료를 바탕으로 보다 정확한 치료 중심 설정이 요구되는 양성자치료에서 Gold Marker Matching System의 필요성을 확인할 수 있었으며, 본 연구에서 사용된 DIPS를 이용하여 전립선의 위치변화에 따른 치료 중심을 보정함으로써 보다 정밀한 양성자치료 효과를 향상시킬 수 있을 것으로 사료된다.

**핵심용어:** 양성자 치료, 전립선, 디지털 영상 환자자세 체계, 기준의 금 표시, 매일의 변화차이