

Pure esophageal atresia. 2 case

* * * * * **

=Abstract=

Pure esophageal atresia. 2 case

Sang Seok Jeong, M.D.* , Phil Jo Choi, M.D.* , Kwon Jae Park, M.D.*
Jung Hee Bang, M.D.* , Gwang Jo Cho, M.D.* , Jong Soo Woo, M.D.*
Jin A Jung, M.D.**

*Department of Thoracic and Cardiovascular Surgery, College of Medicine,

**Department of Pediatrics, College of Medicine, Dong-A University

Pure esophageal atresia without tracheoesophageal fistula is a uncommon form of congenital malformation of the esophagus, which is able to be suspected by fetal ultrasonography before delivery and diagnosed definitely by simple chest X-ray and esophagogram immediately after delivery. We performed delayed primary repair in 2 cases of pure esophageal atresia by using stomach for conduit in one case and colon in the other case. But there were graft failure in the latter case, so reoperation was performed by using stomach. Postoperatively, two patients showed no stenosis and leakage in anastomotic site and were discharged in good oral intake without dysphagia.

Key words : Pure esophageal atresia, Conduit

1
38 , 2.4kg
4
가 5
가 가

(Fig. 1).

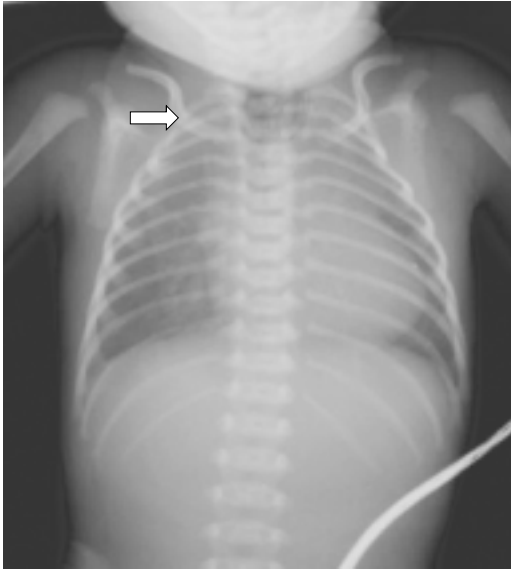


Fig. 1. Preoperative simple chest X-ray shows no gastric air bubble and twisting L-tube around blind pouch of proximal esophagus (arrow).

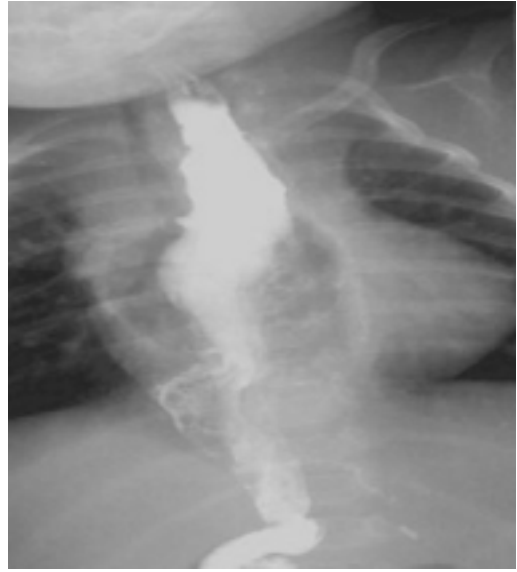

Fig. 2. Postoperative esophagogram shows no leakage and stenosis at anastomotic site.

가
 10~12 mmHg
 가
 PDS
 black silk
 PDS
 black silk
 가
 6
 23
 (Fig. 2).
 42
 2
 가
 가
 38 , 2.9kg(3~10
 percentile), 50cm(25 percentile)
 1/3 가
 (Graft failure)
 (gastric tube)
 7
 (Fig. 3A).
 (Blind

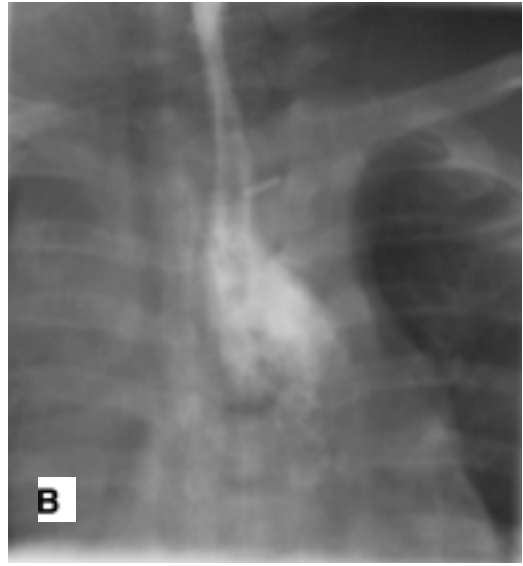
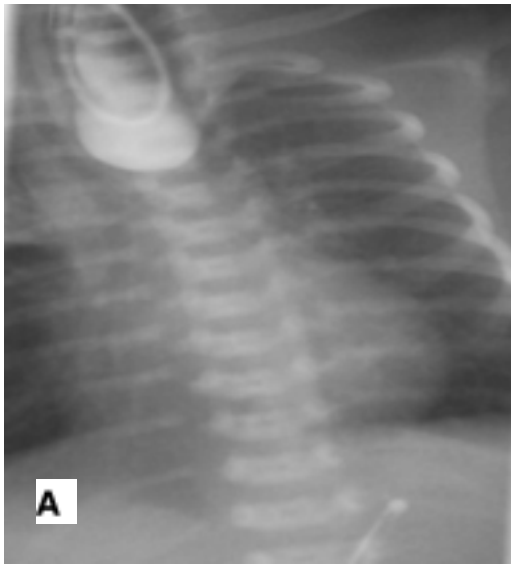

Fig. 3. Preoperative esophagogram shows blind pouch of proximal esophagus(A). Postoperative esophagogram shows no leakage and stenosis at anastomotic site(B).

pouch) 6 1
 4
 6 6
 (Fig. 3B).
 가
 7 TD(Tolerable diet) 600cc
 12
 (Vascular pedicle) 9.6kg(25-50 percentile), 74cm
 (10-25 percentile)
 가
 (Sternal notch) 가
 (Sternocleidomastoid muscle) 40,000 1 가
 3cm 가
 . Prolene 5-0 4
 5 가 가
 7.7%

가 4.7% , 29% , 가

10% , 4 , 가 가

가 가³⁾ 가

90% 가 (Double blood supply)

1), 가 가 가⁴⁾ 가

100% 가 가⁴⁾ 가

2) 1 가⁵⁾ 가 가

가 1 가

가 가 가

(Delayed primary repair)

(Graft redundancy) (Early repair)

"Value Added Technique for Esophageal Reconstruction"(VATER)⁶⁾ 가

Tannuri 가⁵⁾ 가 가⁷⁾

가

가가

가가

가

가

20% 40%

가

가

1,600g

가

(Bolus feed-

ing)

가

(fundoplication)

가

가

가

가

2

가

References

1. Mellins RB. Cardiovascular anomalies and esophageal atresia. *Am J disease of children.* 1966;107:160.
2. Boyle EM, Foker JE, Irwin ED, et al. Primary repair of ultra-long-gap esophageal atresia: results without a lengthening procedure. *Ann Thorac Surg* 1994;57:576-9.
3. Gupta DK, Srinivas M, Agarwala S, et al. Neonatal gastric pull up: reality or myth? *Pediatr Surg Int* 2003;19:100-3.
4. Tannuri U, Maksoud-Filho JG, Andrade W, et al. Which is better for esophageal substitution in children, esophagocoloplasty or gastric transposition? A 27-year experience of a single center. *J Pe-diatr Surg* 2007;42:500-4.
5. Spitz L, Kiely E, Sparnon T. Gastric transposition for esophageal replacement in children. *Ann Surg* 1987;206:69-73.
6. Varjavandi V, Shi E. Early primary repair of long gap esophageal atresia: The VATER Operation. *J Pediatr Surg* 2000;35:1830-2.
7. McCollum MO, Rangel SJ, Blair GK, et al. Primary reversed gastric tube reconstruction in long gap esophageal atresia. *J Pediatr Surg* 2003;38:957-62.