

A case of herpes zoster in a 4-month-old infant

Ji Hyun Kim, M.D., Jung Ju Lee, M.D., Sin Weon Yun, M.D.
Soo Ahn Chae, M.D., In Seok Lim, M.D., Dong Keun Lee, M.D.
Eung Sang Choi, M.D. and Byoung Hoon Yoo, M.D.

Department of Pediatrics, College of Medicine, Chung-Ang University, Seoul, Korea

= Abstract =

Herpes zoster in infancy is very rare but can be developed following intrauterine or postnatal exposure to varicella zoster virus. We report a case of herpes zoster in a 4-month-old male infant. He had no prior history of primary varicella or varicella vaccination. His mother had no history of varicella infection and no contact history with varicella during pregnancy. He had a history of exposure to his father with herpes zoster 3 months ago, and to his cousin with convalescent chickenpox 2 months ago. Multinucleated, giant cells were shown on a Tzanck smear. He was treated with acyclovir and first generation cephalosporin for herpes zoster with Staphylococcal skin infection, with complete resolution without sequelae. (*Korean J Pediatr* 2008;51:1368-1371)

Key Words : Herpes zoster, Infant

Introduction

Herpes zoster is caused by reactivation of varicella zoster virus (VZV) from the dorsal sensory ganglia or the cranial nerve ganglia after a previous primary infection with chickenpox. It is known that pediatric zoster rarely occurs and usually not so severe when it develops, except in immunocompromised children¹⁾. In particular, herpes zoster in infancy is very rare but can be developed following intrauterine or postnatal exposure to VZV^{2,3)}. To our knowledge, there were only 5 cases of infantile herpes zoster reported in Korea⁴⁻⁸⁾.

We describe an uncommon case of herpes zoster in a 4-month-old infant, not following symptomatic varicella infection. In addition, we also review the literature on herpes zoster in infants reported in Korea.

Case report

A 4-month-old male infant presented to the emergency department with a 2-day history of erythematous vesicles on

the right side of his chest and back. He was born at 40 weeks gestation, with a birth weight of 3,450 g. The child had been eating, sleeping well, and remained afebrile. His mother had no history of varicella infection and no contact history with varicella during pregnancy. The patient had a history of exposure to his father with herpes zoster corresponding to the left C7 dermatome 3 months ago, and to his cousin with convalescent chickenpox 2 months ago. The infant had neither a history of febrile illness nor of symptoms that appeared to be primary varicella. Initial physical examination of the infant showed grouped vesicles and crusts on an erythematous based scattered along the chest and back, with a sharp demarcation at the midline. This corresponded to the right T4 dermatome (Fig. 1). There was a yellowish discharge from the lesion. No other abnormalities were noted. He was admitted for treatment of possible bacterial superinfection complicating herpes zoster. Findings from a Tzanck smear were positive for multinucleated giant cells.

Complete blood cell count with differential count was within normal limit. Immunologic work-up was undertaken. Quantitative serum immunoglobulin levels were as follows: IgA, 38 mg/dL (normal range, 8-90 mg/dL); IgM, 73 mg/dL (normal range, 10-90 mg/dL); and IgG, 583 mg/dL (normal range, 200-1,200 mg/dL). Lymphocyte subset analysis revealed normal ratios of CD3, CD4, CD8, CD19, CD16, and CD56 surface markers. Methicillin-sensitive Staphylococcus

Received : 17 August 2008, Revised : 24 December 2008

Accepted : 17 October 2008

Address for correspondence : In Seok Lim, M.D., Ph.D.

Department of Pediatrics, Chung-Ang University Yongsan Hospital

65-207, Hwangro-3ga, Yongsangu, Seoul, 140-757, Korea

Tel : +82.2-748-9967, Fax : +82.2-795-4698

Email : inseok@cau.ac.kr

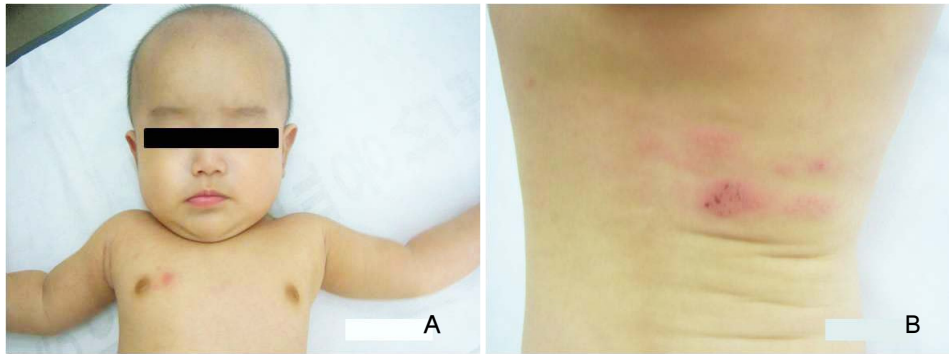


Fig. 1. Multiple grouped vesicles and crusts on an erythematous based were shown along the chest and back. This corresponded to the right T4 dermatome.

Table 1. Reported Cases of Herpes Zoster in the First Year of Life in Korea

Source	Sex/Age	Age of exposure	Source of exposure	Side	Dermatome	Complication
Na, 1996 ⁵⁾	M/3 mo	Intrauterine (7 mo gest)	Maternal exposure without clinical Sx	Rt.	T2	No
Kim, 1997 ⁶⁾	M/23 d	Unknown	Unknown (Maternal febrile illness at 7 mo gest)	Lt.	T3-4	No
Kim, 1999 ⁵⁾	F/11 mo	3 mo	Primary varicella infection	Rt.	T4	No
Keun, 2002 ⁴⁾	F/9 mo	7 d	A child with convalescent varicella without clinical Sx	Rt.	T11	No
Lee, 2005 ⁷⁾	F/9 mo	Unknown	Unknown (Presumptive postnatal exposure)	Rt.	T4	Pneumonia→subsided
Present report	M/4 mo	1-2 mo	Father with herpes zoster or cousin with primary varicella infection	Rt.	T4	Bacterial skin infection→subsided

Abbreviations : Gest, gestation; Sx, symptom

aureus was isolated from the skin lesions. Serologic tests obtained on admission were positive for anti-VZV IgG, but negative for anti-VZV IgM.

The patient was received intravenous therapy, including acyclovir and first generation cephalosporin. He showed improvement in the eruption and exudates, and was discharged to home after 4 days. He recovered completely without sequelae, and has remained well.

Discussion

Primary varicella tends to occur in childhood, whereas herpes zoster is a disease of adults, with most patients being older than 45 years^{1, 3)}. The incidence of herpes zoster is very low in the group 0 to 5 years of age (20 per 100000 person-years) compared with adolescents or adults⁹⁾. In Korea, Park et al. reported that children under 18 years old constituted 5.7% (17/1271) of total herpes zoster patients, and 18% (13/72) of the children were aged 4 years and younger¹⁰⁾.

Herpes zoster in healthy immunocompetent children in early childhood or during intrauterine exposure is associated

with the immaturity of the immune system^{11, 12)}. It has been reported that, infants had a lower response of VZV-specific cellular and humoral immunity than older children after primary varicella, and the low response of specific immunity provide a possible explanation for the finding that chickenpox in infancy is a risk factor for the development of herpes zoster in otherwise healthy children^{10, 12)}.

Infantile herpes zoster has been described following intrauterine exposure to VZV²⁾. Virus-specific immunoglobulin detection is uncommon in the fetal stage, and the frequency of lymphocytes, natural killer cells, cytokine mediators responding to herpetic antigens is low in infants^{13, 14)}. These may result in the difficulty of maintaining virus latency with an increased risk of developing zoster in the infant period¹⁴⁾. Intrauterine VZV exposure can result in asymptomatic congenital infection with subsequent herpes zoster within the first year of life²⁾. Intrauterine VZV infection can cause congenital varicella syndrome, acute varicella at birth, or herpes zoster in infancy¹⁴⁾. In addition, infantile herpes zoster can occur after postnatal exposure to VZV, but postnatally acquired herpes zoster is less common than intrauterine infec-

tion³⁾. It has been suggested that protective maternal VZV antibodies passively transferred to the infant may modify the disease into a subclinical varicella and that subclinical form of primary varicella infection may predispose to herpes zoster^{11, 15, 16)}. In general, infants with primary varicella infection are at high risk for herpes zoster within the first year of life¹⁵⁾.

In this case, the patient was exposed to his father with herpes zoster 3 months ago, and to his cousin with convalescent chickenpox 2 months ago. Varicella can develop in a nonimmune individual after exposure to cases of varicella or zoster¹⁷⁾. In this case, thereafter, the patient might develop subclinical form of primary varicella infection from his father with herpes zoster or his cousin with chickenpox, and subsequently present clinically with herpes zoster. There were no reported varicella exposures or infection to the patient's mother during pregnancy, but this cannot be conclusively ruled out.

Summaries of the reported Korean cases of herpes zoster in the first year of life are presented in Table 1. There were 2 cases (33%) of prenatal acquisition and 4 cases (67%) of postnatal acquisition. Male to female ratio was 1:1. The locations were thoracic dermatomes in all patients. According to reports by Kurlan *et al.*³⁾, of the 62 cases, 43 cases (69%) were prenatal exposure and 19 cases (31%) were postnatal exposure. In their study, of the cases in which patient sex was reported, 60% occurred in boys and 40% in girls. They reported that the dermatomes most frequently affected are thoracic dermatomes (33%), but, all dermatomes are nearly equally affected. Cranial nerves were involved in 27%, cervical in 20%, and lumbosacral dermatomes in 20%. In another study of Korean children¹⁰⁾, the dermatomal involvements of herpes zoster were most commonly on thoracic dermatomes.

Oral (40–60 mg/kg per day) or intravenous (30 mg/kg per day) acyclovir has been used for 5 to 8 days or for 2 days after new lesions stop developing for VZV in children¹⁸⁾. It is well known that children with herpes zoster have a better prognosis than adults, with milder symptoms and less complication¹⁾. In this case, the patient had no other symptoms than skin lesion, and complete resolution occurred without sequelae. In cases of infantile herpes zoster reported in Korea, a patient had developed pneumonia but subsided. All patients treated with acyclovir and healed completely without sequelae.

한 글 요약

4개월 영아에서 발생한 대상포진 1예

김지현 · 이정주 · 윤신원 · 채수안
임인석 · 이동근 · 최응상 · 유병훈

중앙대학교 의과대학 소아과학교실

영아에서의 대상포진은 매우 드문 질환이지만, 자궁 내에서 혹은 출생 후 수두 바이러스에 노출되어 발생할 수 있다. 태생기에는 바이러스에 대한 특이 면역글로불린 수치가 낮으며, 영아기에는 항원에 반응하는 림프구, 자연살해세포, 사이토카인이 적어 바이러스의 잠복기를 유지하기가 어려워, 이 때에 감염되는 경우 생후 1년 이내에 대상포진이 발병하는 것으로 알려져 있다. 저자들은 수두에 이환 되었거나 수두 예방접종을 받았던 적이 없었던 생후 4개월 영아에서 대상포진을 경험하였기에 보고하는 바이다. 환자의 어머니 역시 임신 중 수두에 감염되었거나 노출된 병력이 없었으며 환아는 대상포진에 병발된 포도상구균 감염에 대하여 acyclovir와 1세대 세팔로스포린으로 치료를 받고, 합병증 없이 치료되었다.

References

- 1) Myers MG, Seward JF, LaRussa PS. Varicella zoster virus. In: Behrman RE, Kliegman RM, editors. Nelson Textbook of pediatrics. 18th ed. Philadelphia: WB Saunders Co, 2007:1366–72.
- 2) Enders G, Miller E, Craddock-Watson J, Bolley I, Ridehalgh M. Consequences of varicella and herpes zoster in pregnancy: prospective study of 1739 cases. *Lancet* 1994;343:1548–51.
- 3) Kurlan JG, Connelly BL, Lucky AW. Herpes zoster in the first year of life following postnatal exposure to varicella-zoster virus: four case reports and a review of infantile herpes zoster. *Arch Dermatol* 2004;140:1268–72.
- 4) Keun SO, Lee SY, Kim SM, Jeong DC, Chung SY, Kang JH. A case of herpes zoster in a 9-month-old infant. *Korean J Pediatr Infect Dis* 2002;9:230–5.
- 5) Kim GI, Park CW, Lee CH. A case of herpes zoster in an 11-month-old infant. *Korean J Dermatol* 1999;37:948–50.
- 6) Kim KH, Ro YI, Yang ES, Moon KR, Park SK, Jung BS. A case of herpes zoster in premature infant. *J Korean Pediatr Soc* 1997;40:1169–72.
- 7) Lee YH, Lim JW, Suh MK, Jang JW, Kim JR. A case of herpes zoster in a 9-month-old infant. *Korean J Dermatol* 2005;43:1136–8.
- 8) Na GY, Choi SK. A case of herpes zoster in a normal 3-month-old infant. *Korean J Dermatol* 1996;34:476–9.
- 9) Donahue JG, Choo PW, Manson JE, Platt R. The incidence of herpes zoster. *Arch Intern Med* 1995;155:1605–9.
- 10) Park SJ, Song HJ, Kim CW, Lee KS. A clinical study of 72 cases of herpes zoster in children and adolescents. *Korean J*

- Dermatol 2006;44:664-8.
- 11) Baba K, Yabuuchi H, Takahashi M, Ogra PL. Increased incidence of herpes zoster in normal children infected with varicella zoster virus during infancy: community-based follow-up study. *J Pediatr* 1986;108:372-7.
 - 12) Terada K, Kawano S, Yoshihiro K, Morita T. Varicella-zoster virus (VZV) reactivation is related to the low response of VZV-specific immunity after chickenpox in infancy. *J Infect Dis* 1994;169:650-2.
 - 13) Paryani SG, Arvin AM. Intrauterine infection with varicella-zoster virus after maternal varicella. *N Engl J Med* 1986;314:1542-6.
 - 14) Chiang CP, Chiu CH, Huang YC, Lin TY. Two cases of disseminated cutaneous herpes zoster in infants after intrauterine exposure to varicella-zoster virus. *Pediatr Infect Dis J* 1995;14:395-7.
 - 15) Dobrev H. Herpes zoster in infants. *Folia Med (Plovdiv)* 1994;36:45-9.
 - 16) Baba K, Yabuuchi H, Takahashi M, Ogra PL. Immunologic and epidemiologic aspects of varicella infection acquired during infancy and early childhood. *J Pediatr* 1982;100:881-5.
 - 17) Feder HM, Jr., Hoss DM. Herpes zoster in otherwise healthy children. *Pediatr Infect Dis J* 2004;23:451-7; quiz 8-60.
 - 18) Kakourou T, Theodoridou M, Mostrou G, Syriopoulou V, Papadogeorgaki H, Constantopoulos A. Herpes zoster in children. *J Am Acad Dermatol* 1998;39:207-10.