

Intracapsular and Paraarticular Chondroma of the Infrapatellar Hoffa's Fat Pad: A Case Report

Suk Ki Jang¹, Hyeok Jin Hong¹, Eun Mee Han², Su Min Kang¹, Jin Young Yoo¹, In Oak Ahn¹

Intracapsular and paraarticular chondroma is a rare benign lesion of the large joints (mostly the knee). We report a case of intracapsular and paraarticular chondroma in the infrapatellar Hoffa's fat pad that presented as a painful palpable mass in 15-year-old woman. A physical examination revealed a firm, movable and tender mass in the infrapatellar area. Magnetic resonance images showed an ovoid, well-defined, soft tissue mass with focal calcification in the infrapatellar fat pad. The final pathology revealed an intracapsular and paraarticular chondroma.

Index words : Chondroma

Lower Extremity

Knee

Magnetic Resonance Imaging

Extraskkeletal chondromas are benign tumors that appear in three variants: synovial chondromatosis, paraarticular chondroma and soft tissue chondroma. The first type is very common, the others are quite rare and they may show atypical features. The fibrous coat of the joint capsule and/or the paraarticular connective tissue, very rarely, can suffer cartilaginous metaplasia (1). The intracapsular or paraarticular chondromas are formed by this metaplasia. These lesions have reported in a few English literatures (1, 2). This report presents findings of the plain radiograph, magnetic resonance (MR) images, and a pathologic findings by surgical biopsy. A surgical excisional biopsy of the tumor confirmed to intracapsular and paraarticular

chondroma in the infrapatellar fat pad.

Case Report

A 15-year-old woman had a painful palpable mass in the left knee for two years. The patient had no history of trauma or any previous surgery. There was a firm, movable, tender mass in the infrapatellar area on physical examination. An initial lateral plain radiograph of the left knee showed an infrapatellar calcified mass (Fig. 1a). Magnetic resonance (MR) imaging showed a 3 × 3 × 4 cm sized well-defined ovoid-shaped soft tissue mass in the lateral aspect of the infrapatellar fat pad. The mass had similar signal intensity to surrounding

JKSMRM 12:197-200(2008)

¹Department of Radiology, Bundang Jesaeng General Hospital

²Department of Pathology, Bundang Jesaeng General Hospital

Received; August 28, 2008, accepted; September 27, 2008

Corresponding author : Hyeok Jin Hong, M.D., Department of Radiology, Bundang Jesaeng General Hospital

255-2, Seohyun-dong, Bundang-gu, Seongnam-si, Gyeonggi-do 463-774, Korea

Tel. 82-31-779-0051 Fax. 82-31-779-0062 E-mail: hjhong@dmc.or.kr

muscle on T1-weighted spin echo images (Fig. 1b) and heterogenous high signal intensity on the T2-weighted fast spin echo image with foci of low signal intensity (Fig. 1c). The area of low signal intensity on the T2-weighted images corresponded to calcification. Surgical resection revealed a mass measuring 3×3×4 cm in continuity with the capsule of the joint.

Macroscopically, on cross section there are calcified foci surrounded by the hyaline cartilage (Fig. 2A). The histologic examination showed mature hyaline cartilage with focal calcification beneath synovial membrane (Fig. 2b, c). The diagnosis was intracapsular and paraarticular chondroma.

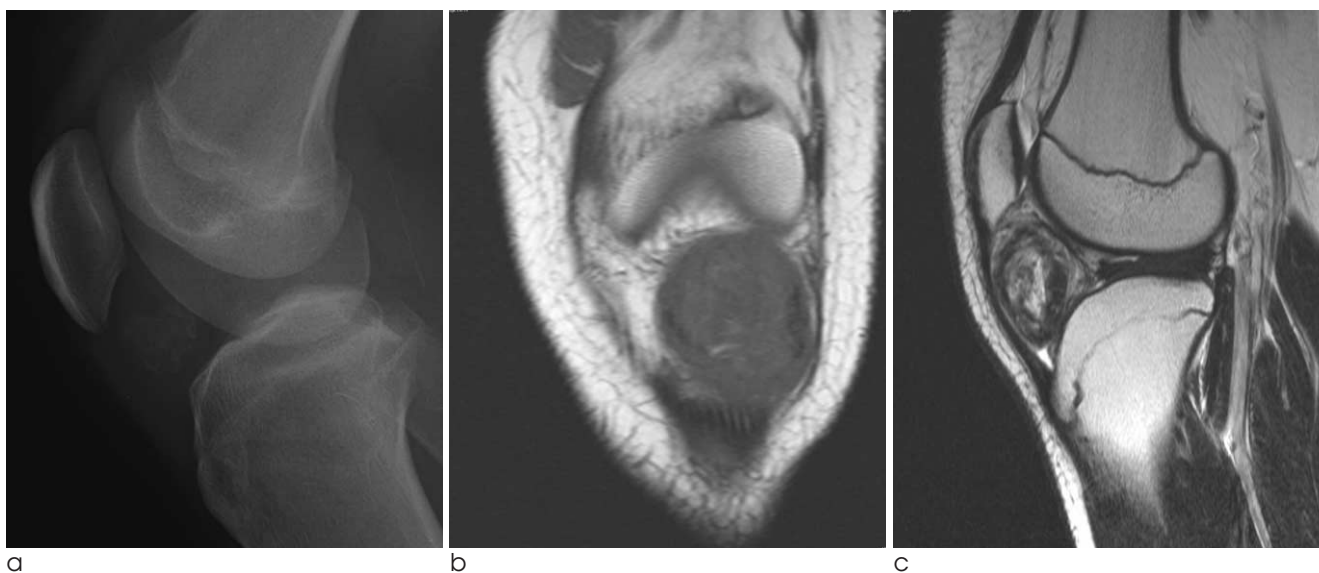


Fig. 1. A 15-year-old woman with intracapsular or paraarticular chondroma on infrapatellar fat pad. a. Lateral radiograph of the knee shows an infrapatellar calcified soft tissue mass (white arrows). b. Coronal T1 weighted image shows intermediate to low signal intensity similar to surrounding muscle (black arrows). c. Sagittal T2 weighted image shows high signal intensity corresponding to areas of hyaline cartilage and low signal intensity corresponding to areas of calcified foci (arrowheads).

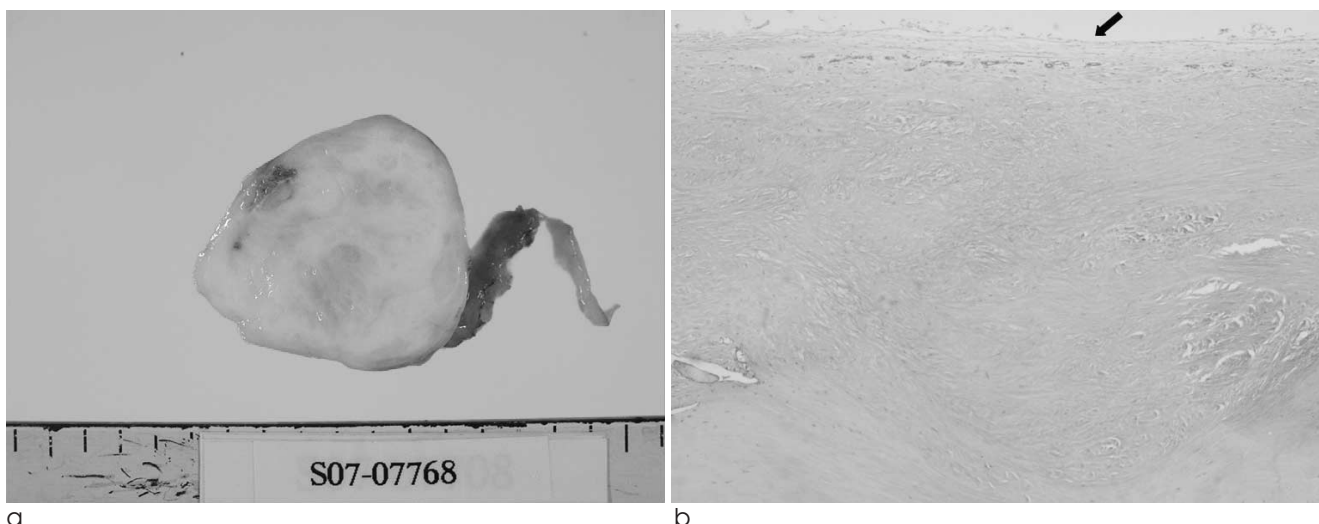


Fig. 2. Gross and photomicrograph of the specimen. a. Macroscopic appearance of the cross-sections of the tumor showing white glistening cartilage mixed with yellow calcified foci. b. Microscopic finding shows mature lobules of hyaline cartilage with focal calcification beneath synovial membrane (black arrow) (H & E, ×40).

Discussion

Intracapsular and paraarticular chondromas have been named capsular osteomas, osteochondromas or chondromas depending on the relative proportions of bone and cartilage (3). Jaffe et al (2) in 1958, grouped all these entities under the term intracapsular and paraarticular chondromas. The knee region seems to be the most common site for intracapsular, extrasynovial chondromas. And most paraarticular chondromas around the knee have been located anteriorly, in the infrapatellar region, usually on the medial aspect (4), in contrast to the lateral aspect as in our case. The age range varies from 12 to 75 years (mean 49.4 years). There is no preponderance for sex either. The clinical presentations are moderate-degree pain lasting from 2 months to 20 years and limitation of joint movement in some cases (3).

Our case showed the characteristic features of soft tissue chondroma. Lateral plain radiograph of the knee demonstrated a large soft tissue mass with a wide radiodensity due to calcification. T2-weighted MR imaging demonstrates a heterogeneous mass within the infrapatellar fat pad, with the high signal intensity representing chondroid matrix or edema and areas of low signal intensity representing calcification (5). Variable degrees and patterns of calcification are often seen, at times becoming so marked as to suggest tumoral calcinosis or dystrophic calcification. Ossification is generally peripheral and focal. In some cases, the pattern of ossification is central with a peripheral cartilaginous layer enough to warrant the denomination of osteochondroma (4).

The pathogenesis of these tumors is also controversial. They most likely originate from the connective tissue in the vicinity of the capsule of a joint or from the outer coat of the capsule. Metaplasia from extrasynovial mesenchymal pluripotential cells is thought to be the origin of soft tissue chondromas. The natural evolution of these lesions is a process of metaplasia, cartilaginous proliferation, and eventually ossification. Prior trauma is unlikely to play any significant role in the pathogenesis of these tumors (1, 4). Intracapsular and paraarticular chondromas must be considered in the differential diagnosis of radiological calcified soft tissue lesions about the joints, such as old hematomas, calcifying

bursitis, tumoral calcinosis, periosteal chondromas, calcified synovial sarcomas, localized nodular synovitis, primary synovial chondromatosis and soft tissue chondrosarcoma (3). Especially, intracapsular or paraarticular chondroma must be differentiated from localized nodular synovitis, synovial chondromatosis and soft tissue chondrosarcoma. Localized nodular synovitis is the localized form of the villonodular synovitis. It can occur in the anterior aspect of the knee, including the infrapatellar fat pad. The hemosiderin deposition in localized nodular synovitis, unlike that in PVNS, is highly variable and may even be absent. Hemosiderin appears as dark signal intensity on the T1 and T2 weighted MR images and as marked susceptibility effect (hypointense blooming) on gradient-echo images. Hence localized nodular synovitis can be differentiated by the signal intensity from intracapsular and paraarticular chondroma (5, 6). Synovial chondromatosis is composed of intra- or extra-articular multiple nodules rather than a single mass, and the small hyaline nodules are arranged in characteristic chondrocyte clusters, with slight atypia and focal endochondral ossification. In contrast, intracapsular chondroma shows large masses of cartilage with prominent endochondral ossification and even mass effect with adjacent osseous erosion may be seen (3, 5). Soft tissue chondrosarcoma may present a problem when the lesion is primarily cartilage. Most reported cases occur in the proximal skeleton and are large. When a mass is present at the knee and there is no evidence that the adjacent bone is involved, the lesion is probably a paraarticular chondroma rather than a soft tissue chondrosarcoma (7, 8). The treatment of choice for intracapsular or paraarticular chondroma is surgical excision. Malignant transformation has never been reported and local recurrence is rare. With correct diagnosis, unnecessarily aggressive surgical treatment will be avoided (1).

In conclusion, intracapsular and paraarticular chondromas of the knee is a rare benign lesion and must be differentiated from other benign or malignant tumors which occur in the same region.

References

1. Samardziski M, Foteva M, Adamov A, Zafiroski G. Intracapsular and para-articular chondroma of knee: a report

of four cases and review of the literature. Radiol Oncol 2006;40(4):205-209

2. Jaff HL. Tumors and tumorous conditions of the bones and joints. Philadelphia: Lea & Febiger, 1958:567-569

3. Gonzales-Lois C, Garcia-de-la-Torre JP, SantosBriz-Terron A, Vila J, Manrique-Chico J, Martinez-Tello FJ. Intracapsular and para-articular chondroma adjacent to large joints: report of three cases and review of the literature. Skeletal Radiol 2001;30:672-676

4. Nuovo MA, Desai P, Shankman S, Present D. Intracapsular and paraarticular chondroma of the knee. Bull Hosp Jt Dis Orthop Inst 1990;50:189-195

5. Jacobson JA, Lenchik L, Ruhoy MK, Schweitzer ME, Resnick D. MR imaging of the infrapatellar fat pad of Hoffa. Radiographics 1997;17:675-691

6. Kim JC, Lee YS, Ji JH, Lee EH, Kang SW. Intracapsular and Paraarticular Chondroma of the Knee: case report. J Korean Radiol Soc 2004;51:449-452

7. Mosher JF Jr, Kettelkamp DB, Campbell CJ. Intracapsular or para-articular chondroma. A report of three cases. J Bone Joint Surg Am 1966;48:1561-1569

8. Bansal M, Goldman AB, DiCarlo EF, McCormack R. soft tissue chondroma: diagnosis and differential diagnosis. Skeletal Radiol 1993;22:309-315

대한자기공명영상학회지 12:197-200(2008)

Hoffa씨 지방층의 관절강내 및 관절주위 연골종: 증례 보고

¹분당제생병원 영상의학과, ²분당제생병원 진단병리과

장석기¹ · 홍혁진¹ · 한은미² · 강수민¹ · 유진영¹ · 안인욱¹

관절강내 및 관절주위 연골종은 큰 관절 중 주로 슬관절에 생기는 드문 양성 종양이다. 저자들은 동통을 동반한 만져지는 슬개골하 종괴를 주소로 내원한 15세 여자 환자에서 Hoffa씨 지방층에 발생한 관절강내 및 관절주위 연골종을 경험하였다. 이학적 검사에서 슬개골하 부위에 단단하고 이동성이 있는 종괴가 만져졌으며 자기공명영상에서 이 종괴는 국소 석회화를 동반한 경계가 좋은 연조직 종괴였다.

통신저자 : 홍혁진, (463-774) 경기도 성남시 분당구 서현동 255-2, 분당제생병원 영상의학과
Tel. (031) 779-0051 Fax. (031)779-0062 E-Mail: hjhong@dmc.or.kr