



^{18}F -FDG PET/CT 에서 발견된 S상 결장암의 단일 비장 전이

아주대학교 의과대학 핵의학교실
안영실 · 윤준기 · 홍선표 · 최봉희 · 조철우 · 윤석남

Isolated Splenic Metastasis of Sigmoid Colon Cancer Detected by ^{18}F -FDG PET/CT

Young-Sil An, M.D., Joon-Kee Yoon, M.D., Seon Pyo Hong, M.D., Bong-Hoi Choi, M.D.,
Chul-Woo Joh Ph.D., and Seok-Nam Yoon M.D.

Department of Nuclear Medicine and Molecular Imaging, Ajou University School of Medicine, Suwon, Korea

Splenic metastasis from colon carcinoma are rare and usually occur in the presence of disseminated visceral metastasis. The liver is the most common site of metastatic spread from colon cancer.¹⁻⁴⁾ Several hypotheses have attempted to explain the low incidence of splenic metastasis. It should be difficult for colorectal cancer cells to reach the spleen through the portal venous system, in which the blood flow is usually from the spleen to the liver.^{4,6)} Reticuloendothelial system or rhythmic contraction of the spleen may squeeze out the tumor in the spleen.^{4,7)} The absence of afferent lymphatic to the spleen, phagocytic activity and humoral anticancer substances are considered to be other reason for low incidence of splenic metastasis. We report the case of ^{18}F -FDG PET/CT finding in a 70-year-old woman who develop isolated splenic metastasis of sigmoid colon cancer.^{4,5,8)} (Nucl Med Mol Imaging 2007;41(3):263-264)

Key Words: splenic metastasis, colon cancer, ^{18}F -FDG PET/CT

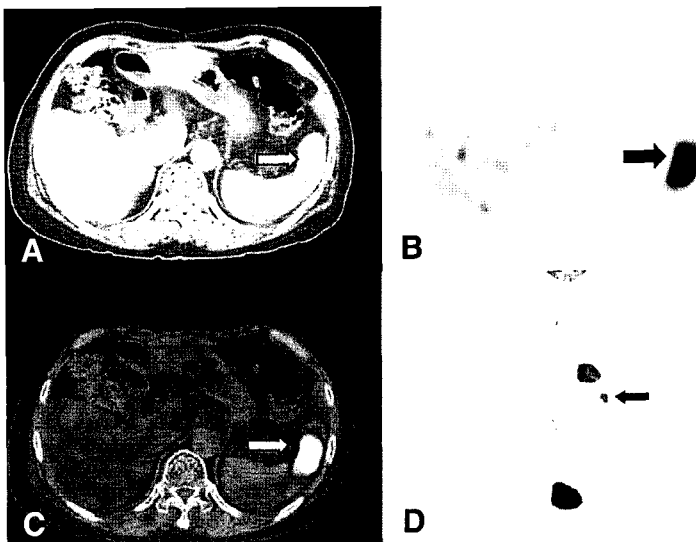


Fig 1. A 70-year-old woman had undergone left hemicolectomy for a sigmoid colon cancer. She also had liver segmentectomy due to liver metastasis. She was placed under chemotherapy for six times. Upon follow-up, she had no specific symptom but, the serum CEA level was elevated to 237. ^{18}F -FDG PET/CT was done to detect recurrence lesions or other metastasis. The PET/CT demonstrated focal, intense increased uptake, about 3cm with 7.3 of peak SUV in the anterior aspect of spleen (arrows point to lesion on, from A to D, CT, PET, fusion image and whole body PET image) suggesting metastasis. The bulging contour like mass in spleen was detected in CT image (A). There were no other lesions to suggest malignancy (D). She refused to have operation due to old age and she is under chemotherapy.

- Received: 2007. 5. 11. • Accepted: 2007. 5. 17.
- Address for reprints: Seok-Nam Yoon, M.D., Department of Nuclear Medicine and Molecular Imaging, Ajou University School of Medicine, San 5, Woncheon-dong, Yeongtong-gu, Suwon 442-749, Korea
Tel: 82-31-219-5947, Fax: 82-31-219-5950
E-mail: snyoon@ajou.ac.kr

References

1. Genna M, Leopardi F, Valloncini E, Molfetta M, De Manzoni G, Castelli A. Metachronous splenic metastasis of colon cancer. A case report. *Minerva Chir* 2003;58:811-4.

2. Place RJ. Isolated colon cancer metastasis to the spleen. *Am Surg* 2001;67:454-7.
3. Indudhara R, Vogt D, Levin HS, Church J. Isolated splenic metastases from colon cancer. *South Med J* 1997;90:633-6.
4. Sawai T, Nakagoe T, Tagawa Y, Sasano O, Yamaguchi H, Yasutake T, et al. A case of solitary splenic metastasis from colon cancer. *Nippon Geka Gakkai Zasshi* 1996;97:1109-11.
5. Berge T. Splenic metastasis. *Acta Pathol Microbiol Scand A* 1974;84:499-506.
6. Miller NJ, Milton GW. An experimental comparison between tumor growth in the spleen and liver. *J Pathol Bacteriol* 1965;90:515-21.
7. Kettle EH. Carcinomatous metastases in the spleen. *J pathol Bacteriol* 1912;17:40-6.
8. Warren S, Davis AH. Studies on tumor metastasis: V. The metastasis of carcinoma to spleen. *Am J Cancer* 1934;21:517-33.