

인지 중지골에서 발생한 거대 세포 육아종

순천향대학교 천안병원 정형외과교실, 병리학교실*, 대전 선병원 정형외과†

박종석 · 최호림 · 이상선 · 오미혜* · 문명상†

거대 세포 육아종(Giant cell reparative granuloma)는 흔하지 않는 양성 종양으로 상악 골이나 하악골에서 흔하다. 그러나 수지에서는 매우 드물다. 저자들은 21세된 남자 환자로 인지에서 발생한 거대 세포 육아종을 보고하고자 한다.

조직학적으로 거대 세포 육아종이었다.

색인 단어: 거대 세포 육아종, 수지, 소파술 및 골이식술

In 1953, Jaffe²⁾ first described giant cell reparative granuloma (GCRG) as a benign lesion affecting the mandible and maxilla, which was a reactive response to intraosseous hemorrhage. Ackerman and Spjut called extragnathic lesions “giant cell reaction” (GCR), because the word “reparative” seemed inappropriate¹⁾.

Unni(1996) also took the view of Ackerman and Spjut in calling these extragnathic lesions in small bones of hand and foot “giant cell reactions” or “giant cell lesions”⁶⁾. The term giant cell granuloma (GCG) has also been introduced to account for the lack of pre-existing trauma or reparative tissue in some of these lesion. Although this lesion is most frequently seen in the mandible and maxilla²⁾, it has rarely

been described to involve other extragnathic sites: the small bones of the hands and feet, the long tubular bones, the paranasal sinuses, the orbit, and the cranial vault.

We report an unusual case of GCRG arising in an index finger in which radiologic imaging and pathologic correlation was made.

Case Report

A 21-year-old solidier presented his chief complaint of pain for 2 years on his right index finger.

Physical examination revealed mild swelling over the dorsum of the right index finger. He was otherwise healthy. He had full flexion of his digits, but had extensor

※통신저자: 이 상 선

충청남도 천안시 봉명동 23-20

순천향대학병원 정형외과

Tel: 041) 571-3644, Fax: 041) 572-7234, E-mail: sslee@schch.co.kr

lag of 15° at the proximal interphalangeal joint of the index.

The plain radiograph of right hand (Fig. 1) showed slightly expansile, well-defined osteolytic lesion in the proximal metaphysis of the middle phalanx of right index finger extending into epiphysis. The cortex was thinned and the lesion eccentrically located without cortical destruction or soft tissue involvement. No surrounding bony sclerosis was present. Calcifications were not seen within the radiolucent area.

He underwent open biopsy and subsequently an curettage and autogenous bone graft from ipsilateral olecranon. By 8 months postoperatively, he could return to unrestricted activities.

Discussion

Clinically, giant cell tumors (GCTs) are usually seen in the 3rd and 4th decade of life, but are rarely seen in patients younger than 20 years. In giant cell reparative granuloma (GCRG), there is a slight female predominance, and although it has been reported in all ages, it typically occurs before the age of 30 years.

The etiology of giant cell reparative granuloma of bone is unknown, and no clue is provided by the case reported here.

The giant cells in GCT are uniformly distributed, more rounded, and are larger, as opposed to the giant cells in GCRGs, which are gathered around hemorrhagic foci, irregular shaped, and smaller. There is evidence of recent and remote hemorrhage in GCRGs

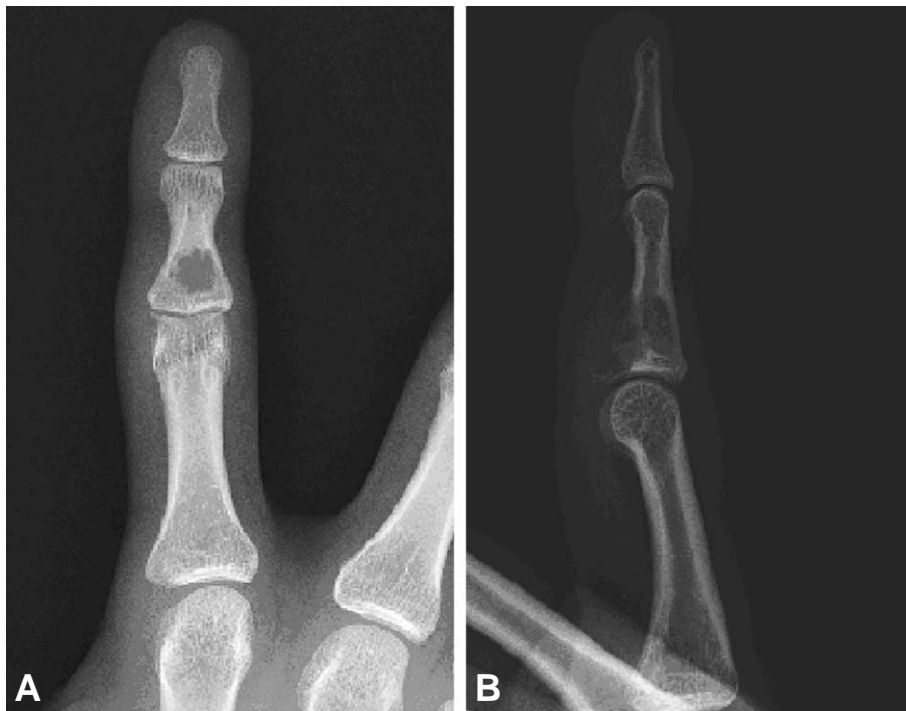

Fig. 1. Anteroposterior (A) and lateral (B) radiographs show the eccentrically located well-defined cystic lesion in the middle phalanx of the index finger, with cortical thinning, but no surrounding sclerosis or mineralization within the radiolucent area.

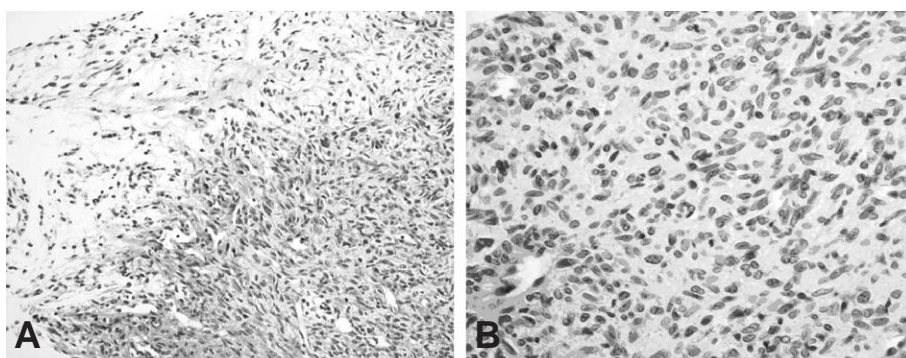


Fig. 2. (A) The tumor shows varying degrees of cellularity (H&E, $\times 200$). (B) The tumor cells of cellular area are spindled to ovoid with no cellular atypism and mitosis (H&E, $\times 400$).

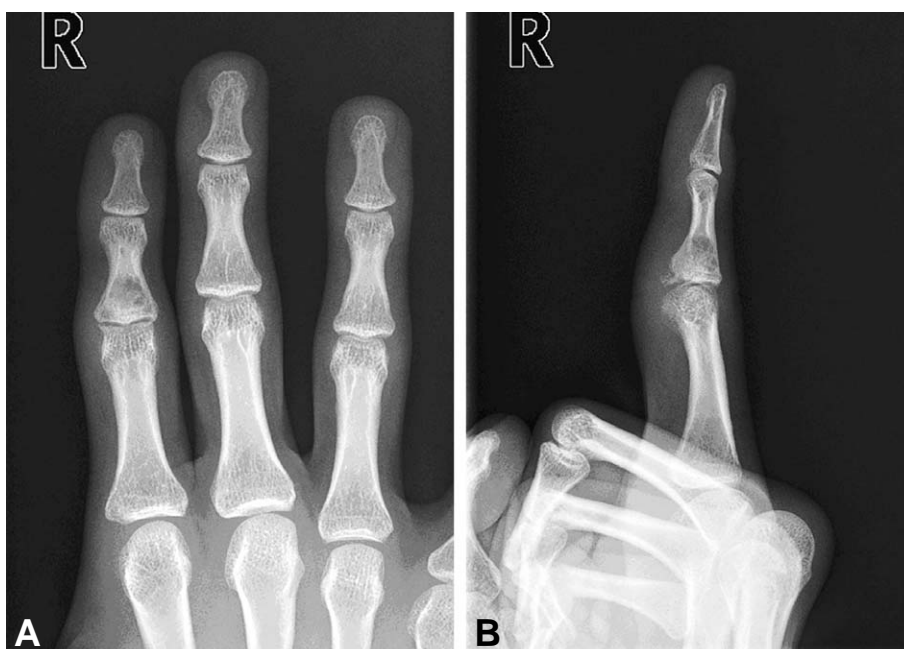

Fig. 3. Anteroposterior (A) and lateral (B) radiographs show complete union at postoperative 12 months.

with new osteoid formation, whereas in GCT there is limited fresh hemorrhage despite its rich vascularity and no osteoid formation^{3,5}. GCRGs has benign clinical course although it is locally aggressive, whereas GCT has more malignant course, higher rate of recurrence, and reported to metastasize⁴.

Radiographic manifestations of GCRGs are nonspecific. Gnathic GCRGs demonstrate

expansile remodelling of the bone and multi-locular appearance⁷.

The radiographic finding of GCRGs in hand and foot was generally that of a purely lytic defect, but some degree of mineralization within the lesion was noted in some cases. As in our case, a densely sclerotic lesion or lesion containing scattered areas of dense sclerosis was uncommon, and giant

cell reactions involving the small bones of the hands very frequently resulted in expansion of the affected bone⁸⁾.

GCRGs in the small bones of the hands and feet most commonly appear as lytic with expansile remodelling and no periosteal reaction. The cortex is thin but usually intact.

Pathologically, the differential diagnosis for giant cell lesions in bone includes giant cell tumor, ABCs and brown tumor of hyperparathyroidism (osteitis fibrosa cystica).

Most physicians are in agreement with surgical excision or debulking, which are the standard treatment. The radiation is reserved for inoperable or recurrent cases.

Surgical excision is recommended over simple curettage because of the higher risk of recurrence^{4,5)}. Our treatment had been curettage and autogenous bone graft from the ipsilateral olecranon area (Fig. 3).

Microscopically, varying degrees of cellularity, with predominantly fibroblast-like spindle cells were seen (Fig. 2A). Focal areas showed recent hemorrhage and lymphocytic infiltration with fibrosis. The tumor cells were spindled to ovoid nuclei with fine chromatin pattern and abundant eosinophilic cytoplasm with indistinct border. Mitosis was not seen (Fig. 2B).

Immunohistochemically, the tumor showed negative reaction for smooth muscle actin, desmin, CD34 and cytokeratin, and equivocal positivity for S-100 protein.

The distinction between GCTs and GCRGs

is important as GCTs carry a small but real risk of metastasis, which is not the case with GCRGs. Although they cannot be reliably distinguished from the clinical or radiologic features, the histologic findings in most cases will provide the correct diagnosis.

REFERENCES

- 1) **Ackerman LV, Spjut HJ**: Atlas of tumor pathology, sect. 2, fasc. 4. Washington DC: *Armed Forces Institute of Pathology*, 282, 1962.
- 2) **Jaffe HL**: Giant -cell reparative granuloma, traumatic bone cyst, and fibrous (fibro-osseous) dysplasia of jawbones. *Oral Surg Oral Med Oral Patol*, 6(1):159-175, 1953.
- 3) **Lorenzo JC, Dorfman HD**: Giant-cell reparative granuloma of short tubular bones of the hands and feet. *Am J Surg Pathol*, 4(6):551-63, 1980.
- 4) **Murphey MD, Nomikos GC, Flemming DJ, Gannon FH, Temple HT, Kransdorf MJ**: From the archives of AFIP. Imaging of giant cell tumor and giant cell reparative granuloma of bone: radiologic-pathologic correlation. *Radiographics*, 21(5):1283-309, 2001.
- 5) **Nemato Y, Inoue Y, Tashiro T, et al**: Central giant cell granuloma of the temporal bone. *Am J Neuroradiol*, 16:982-85, 1995.
- 6) **Unni KK**: Dahlin's bone tumors. General aspects and data on 11087 cases. Philadelphia: Lippincott-Raven, 1996.
- 7) **Waldron CA, Shafer WG**: The central giant cell reparative granuloma of the jaws: An analysis of 38 cases. *Am J Clin Pathol*, 45(4):437-47, 1966.
- 8) **Wold LE, Dobyns JH, Swee RG, Dahlin DC**: Giant cell reaction(giant cell reparative granuloma) of the small bones of the hands and feet. *Am J Surg Pathol*, 10:491-6, 1986.

Abstract

Giant cell Reparative Granuloma of the Middle Phalanx of the Index Finger

**Jong-Seok Park, M.D., Ho-Rim Choi, M.D., Sang-Seon Lee, M.D.,
Mee-Hye Oh, M.D.*, Myung-Sang Moon, M.D,Ph.D.†**

Department of Orthopedic Surgery, Pathology,
College of Medicine, Soonchunhyang University, Cheonan
Department of Orthopedic Surgery, Sun General Hospital, Daejeon,† South of Korea*

Giant cell reparative granuloma (GCRG) is an uncommon benign lesion that is most commonly found in the mandible and maxilla, and is a very rare condition in finger. We report an unusual case of GCRG arising in the index finger of a 21-year-old man.

Histology was characteristic of giant cell reparative granuloma.

Key Words: Giant cell reparative granuloma, Finger, Curettage and bone graft

Address reprint requests to

Sang-Seon Lee, M.D.
Department of Orthopaedic Surgery, Soonchunhyang University,
Cheonan Hospital, 23-10 Bong-Myung dong, 330-721, South Korea
TEL: 82-41-570-3644, FAX: 82-41-572-7234, E-mail: sslee@schch.co.kr