

## Dentin Dysplasia Type I: a Case Report

Jung-A Ryu, Seung-Hey Kim, Byung-Jai Choi, Chung-Ju Hwang\*, Jae-Ho Lee

*Department of Pediatric Dentistry, \*Department of Orthodontics,  
College of Dentistry and Oral Science Research Center, Yonsei University*

### Abstract

A case of dentinal dysplasia type I is presented. Dentin dysplasia type I is a rare dental anomaly that is characterized by disturbance in dentin formation. It appears to be normal clinically, but, radiographically, it is characterized by obliteration of all pulp chambers and short, blunted, and malformed roots. Histological analysis shows whorls of tubular dentin and atypical osteodentin. In this case, features of dentin dysplasia type I in mixed dentition is presented. The clinical, radiographic, and histopathological findings of this condition are described along with its management.

**Key words** : Dentin Dysplasia, Dental Anomaly, Obliteration

### I . INTRODUCTION

Dentin dysplasia(DD) is a rare hereditary disturbance of dentin formation that is characterized by an apparently normal enamel formation with an underlying bizarre whorl-like spherical dentinal pattern. It has a partial or complete pulpal obliteration, defectively formed roots, and a predisposition for an abscess and cyst formation without an obvious inciting factor<sup>1-6</sup>. It is described as a rootless tooth<sup>3</sup>, nonopalescent dentin<sup>4</sup>, or dentinal dysplasia<sup>5</sup>. Its prevalence has been reported as 1 in 100,000 in the general population<sup>1,7</sup>.

Generally, two main classes of DD have been recognized based on their clinical and radiographic appear-

ance. Shields et al.<sup>6</sup> proposed a classification for heritable human dentin defects in which they divided DD into two types, type I(DD1) and type II(DD2). Witkop<sup>1</sup> arrived at a similar distinction but used the term radicular dentin dysplasia for DD1 and coronal dentin dysplasia for DD2. O'Carroll et al.<sup>8</sup> identified four broad categories of the variations according to the radiographic appearance of radicular dentin dysplasia(type I). Scola and Watts<sup>9</sup> proposed subclassification of DD1 into 'total' and 'subtotal'.

In DD1, both the primary and permanent dentitions are affected. Even though the involved teeth clinically appear to have normal size, shape, and consistency<sup>6</sup>, Witkop<sup>10</sup> reported that in some cases the teeth may vary from normal to have slightly amber translucency. The teeth can be poorly aligned, drifted and mobile, as well as prematurely exfoliate secondary to the abnormal root formation<sup>11</sup>. Radiographically, DD1 produces a partial obliteration of the coronal pulp chambers, a total obliteration of the pulp canals, and short conical roots<sup>6</sup>.

교신저자 : 이 제 호

서울시 서대문구 신촌동 134

연세대학교 치과대학 소아치과학교실

Tel: 82-2-2228-8800, 3173 Fax: 82-2-392-7420

E-mail: leejh@yumc.yonsei.ac.kr

Histologically, in DD1, most of the coronal and mantle dentin of the root appears normal, and the dentin defect is confined mainly to the root<sup>1,12,13</sup>. An examination of the tissues from the periapical lesions reveals periapical cysts or granulomas occurring in association with necrotic pulp<sup>14</sup>.

In DD2, both dentitions are affected, even though the involvement in each dentition is different clinically, radiographically and histologically<sup>15</sup>. Clinically, the primary teeth present amber, translucent appearance similar to that in dentinogenesis imperfecta, while the permanent dentition usually looks normal in the aspect of color<sup>15</sup>. Radiographically, the primary teeth show total pulp obliteration, and the permanent teeth show a thistle-tube pulp configuration and pulp stones in the pulp chambers<sup>16</sup>. The primary teeth exhibit amorphous and tubular dentin in the radicular portion, whereas the coronal dentin is relatively normal<sup>12,13</sup>. The permanent teeth also show a relatively normal coronal dentin, but the pulp chamber contains multiple pulp stones or denticles<sup>12,13</sup>.

This is a report of a case of dentin dysplasia type I in the mixed dentition.

## II . CASE REPORT

A 12-year-old boy was referred to the Department of Pediatric Dentistry, College of Dentistry, Yonsei University, for the treatment of parulis on the maxillary left second primary molar. The patient's medical history

revealed no evidence of any disturbance in his general health. In particular, there was no history of bone fractures. His dental history revealed that multiple parulis were formed on the gingival mucosa during the primary dentition. The protruding maxillary central incisors were traumatized twice four years ago. He requested advanced orthodontic treatment because of the protruding incisors and impacted canines.

An extraoral examination showed a class II profile with an insufficient lip closure. The intraoral examination disclosed a parulis on the palatal mucosa of the left maxillary second primary molar. It revealed yellowish brown discoloration of the left maxillary central incisor with no mobility or symptoms, and the other teeth had a normal color. It also showed prolonged retention of primary teeth(Fig. 1, 2).

The panoramic radiographic examination(Fig. 3) showed generalized short, blunted, conical roots and a horizontal, crescent-shaped, radiolucent pulpal remnant. The pulp chambers in all teeth were completely obliterated. The furcation areas of the primary and permanent molars were located quite far from the normal location. Ectopic eruption paths of the maxillary canines and second premolars were shown, and external root resorption of the maxillary lateral incisor was observed. There was proximal dental caries on the right maxillary second primary molar, and periapical lesion was present on the right maxillary second primary molar. There was no periapical radiolucency observed on the left maxillary central incisor.

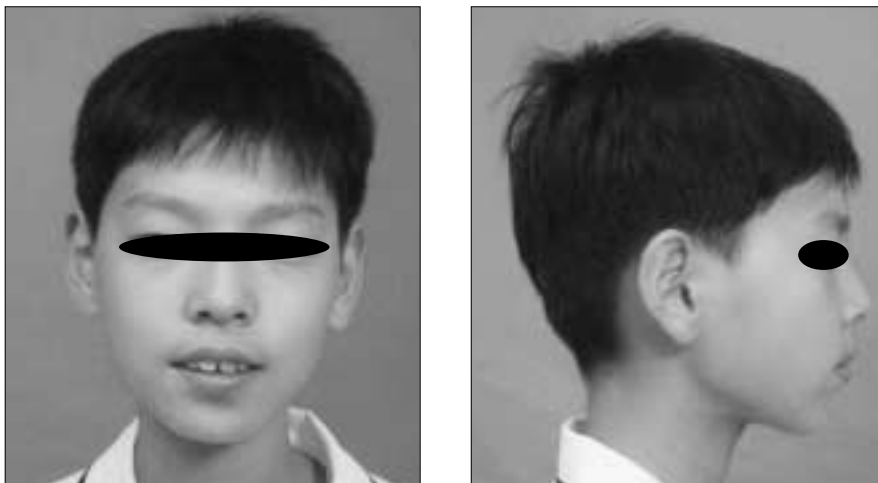
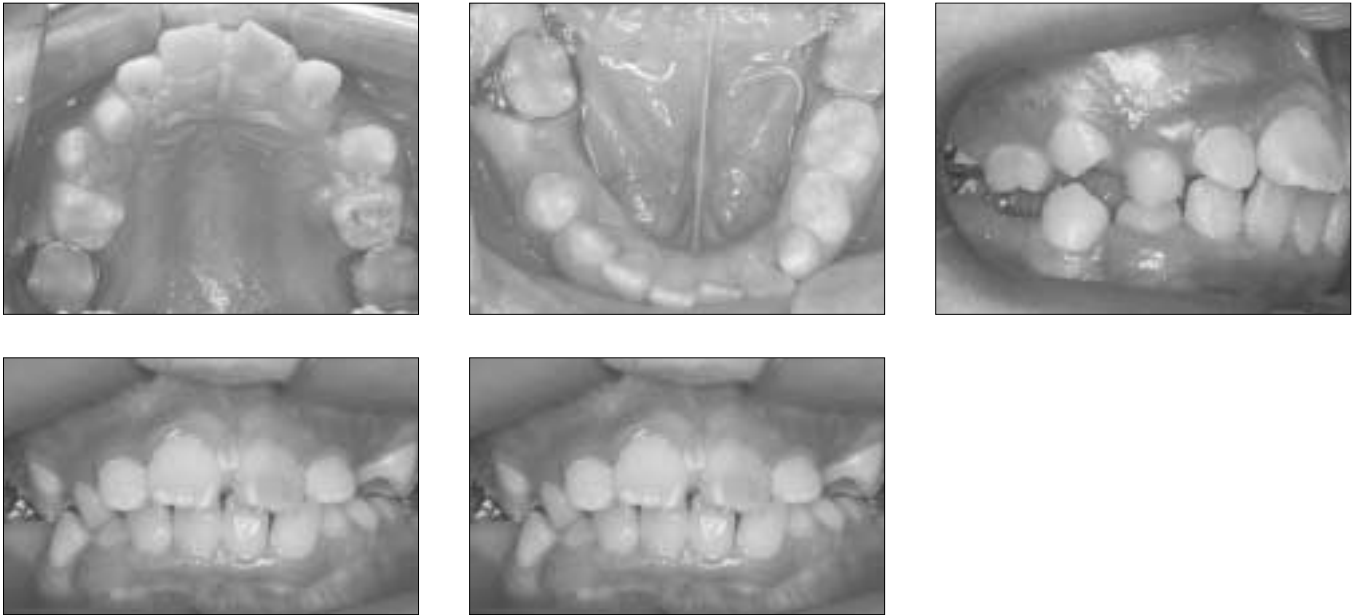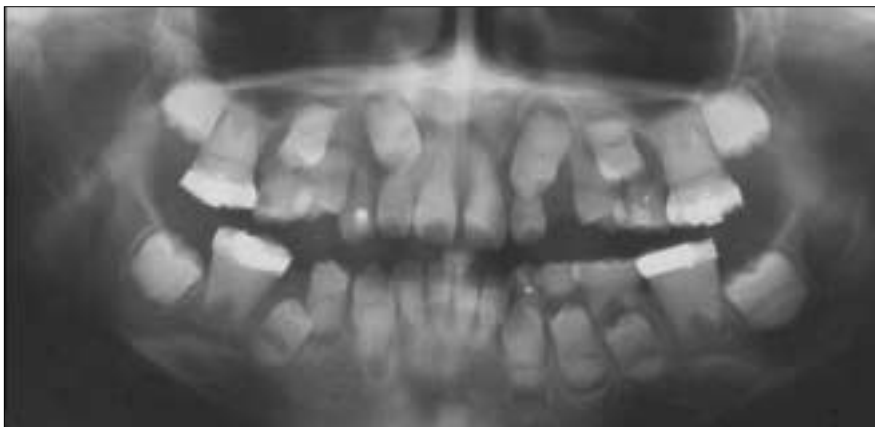


Fig. 1. Extraoral view showed maxillary protrusion and insufficient lip closure.



**Fig. 2.** Intraoral view. Protrusion of the maxillary central incisors, diastema, discoloration of the maxillary permanent left central incisor, and prolonged retention of primary teeth are observed.

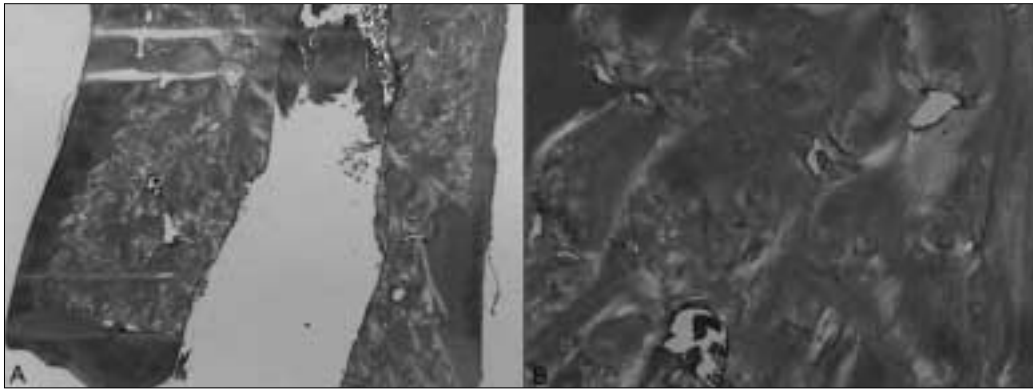


**Fig. 3.** Panoramic radiograph shows short blunted conical roots and complete obliteration of the pulp chambers.

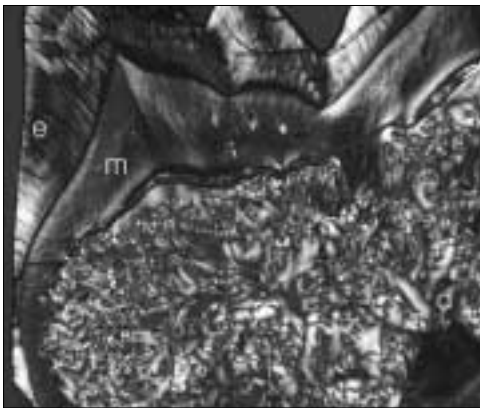
A microscopic examination of the longitudinal sections of right the maxillary second primary molar, which was extracted for periapical abscess, showed loss of enamel due to decalcification and scalloping of the dentin enamel junction(Fig. 4). Most of the coronal and mantle dentin of the root was normal, and the dentin defect was mainly to the root. Apical to the point of disorganization, the central portion of the root was composed of whorls of tubular dentin and atypical osteodentin. Deeper layers of dentin showed atypical tubular patterns with amorphous atubular areas and irregular organization. A ground section of the maxillary left second primary molars showed

a normal outline of the tooth and normal enamel formation(Fig. 5). These features are consistent with the clinical diagnosis of dentin dysplasia type I.

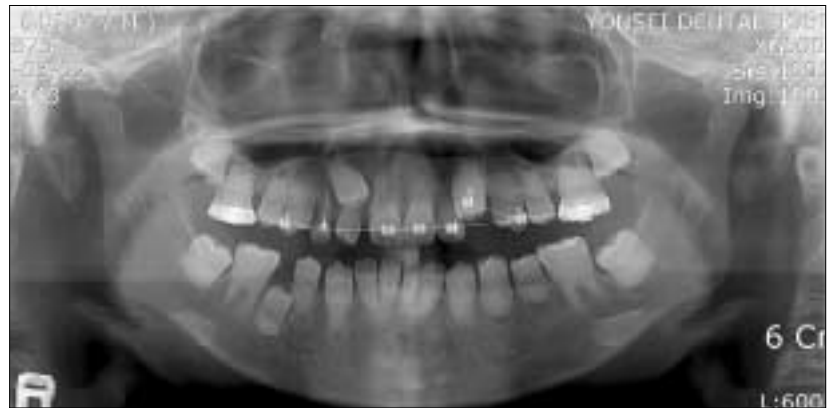During the follow-up, the right maxillary primary canine showed a periapical radiolucent lesion and parulis. The smallest round bur was used for the mechanical creation of canal path and conventional endodontic procedure was done. The pulp canal was filled with a silicone oil-based  $\text{Ca}(\text{OH})_2$  paste (Vitapex, Neo Dental Chemical Products Co., Ltd., Tokyo, Japan). After the treatment, the parulis on labial mucosa of the right maxillary primary canine was healed.



**Fig. 4.** Polarized light view of a tooth shows whorls of tubular dentin and atypical osteodentin(hematoxylin and eosin stain). A, × 10. B, × 40.



**Fig. 5.** Ground section of a tooth shows normal enamel(e) and mantle dentine(m), and pulp chamber was obliterated by dysmorphic dentin(d) (polarized light view, × 10).



**Fig. 6.** Panoramic view after two years reveals closure of diastema, eruption of the maxillary left permanent canine, and pulp treated state of the maxillary right primary canine.

It was difficult to decide the exact orthodontic treatment for this child. It was determined that although the typical root changes were evident, the roots of his teeth were longer than usual and appeared adequate for retention. Extraoral force was used for retraction of the maxilla. Already aware of the questionable prognosis, the patient was further advised that eventually some or all of his teeth might need to be extracted in some time. After retraction of the maxillary permanent first molar using extraoral force, fixed appliance was applied in the permanent dentition with very light orthodontic force. Although both maxillary lateral incisors had external root resorption and both maxillary canines were impacted(Fig. 4), treatment plan was not the same on both sides. The right lateral incisor was planned for extraction because it coincided with the eruption path of the right canine. In contrast, they did not coincide in the left

side. Panoramic view, taken in 14 years old, revealed the closure of diastema and forced eruption state of the left maxillary permanent canine(Fig. 6).

### III. DISCUSSION

This case exhibited the defined features of dentin dysplasia type I(DD1), including a clinically normal crown, the radiographic obliteration of the pulp chambers, periapical radiolucent lesions, taurodontism, and short blunted roots<sup>1-6,14,17</sup>. DD1 appears to occur at different stages of tooth development, and the earlier it occurs, the more severe the pulpal obliteration and the stunting of the roots are<sup>8</sup>. This case appeared to occur at early stage, because the pulpal obliteration was severe. Delayed dental eruption was also examined in this case, even though delayed dental eruption has only rarely

been reported as a characteristic of DD1<sup>14,18)</sup>.

In many cases DD1 appear to be an inherited condition that is transmitted in an autosomal dominant pattern<sup>3,13,14,19-23)</sup>. However, not all cases of DD1 has a genetic in origin<sup>5,24-29)</sup>. A familial pattern was not immediately evident in this patient. He had no siblings and radiographs of his parents' dentition appeared normal.

Preventive care is of foremost importance for patients with dentin dysplasia type I. Perhaps as a result of the shortened roots, the early loss from periodontitis is frequent<sup>1,6,8)</sup>. In addition, pulp vascular channels extend close to the dentino-enamel junction. Therefore, even shallow occlusal restorations can result in pulpal necrosis<sup>24)</sup>.

When periapical inflammatory lesions develop, the therapeutic choice is guided by the root length<sup>23,30)</sup>. The conventional endodontic procedure of the primary tooth was carried out in the left maxillary primary canine which had enough long root.

The orthodontic treatment in these patients with DD1 is very difficult. Although malocclusion is not a specific feature of DD1, a few cases of malocclusion have been reported in association with this disorder<sup>18-21)</sup>. In this patient, orthodontic treatment was required to prevent additional traumatic injuries to the maxillary incisors for protrusion of upper incisors and insufficient lip closure. The very light forces should be used during a prolonged period as other cases in which orthodontic treatment has been attempted<sup>11,23)</sup>.

#### IV. SUMMARY

In conclusion, DD 1 is a rare abnormality of dentin formation, leading to multiple complications. Treating these patients is a challenge to all clinicians involved. It is particularly difficult because the treatment may not always be successful. However, an attempted treatment as in this case can allow these abnormal teeth to be retained as opposed to the alternative of extraction and replacement with dentures.

#### REFERENCES

1. Witkop CJ Jr : Hereditary defects of dentin. *Dent Clin North Am*, 19:25-45, 1975.
2. Langlais, Robert P, Langland, et al. : Diagnostic imaging of the jaws, Williams & Wilkins, Baltimore,

- p.141-146, 1975.
3. Herbst E, Apffelstaedt M : Malformations of the jaws and teeth, Humphrey Milford & Oxford University Press, p.286, 1930.
4. Association of Korean Oral and maxillofacial Radiology : *Oral & Maxillofacial Radiology*. 2nd ed. Yeewoo Munwha Press, Seoul, p.280-282, 1996.
5. Rushton MA : A case of dentinal dysplasia. *Guys Hosp Rep*, 89:369-73, 1939.
6. Shields ED, Bixler D, El-Kafrawy AM : A proposed classification for heritable human dentine defects with a description of a new entity. *Arch Oral Biol*, 18:543-53, 1939.
7. Stewart RE, Prescott GH : *Text book of Oral facial Genetics*. Mosby Co., St. Louis, p. 237-239, 1976.
8. O'Carroll MK, Duncan WK, Perkins TM : Dentin dysplasia: Review of the literature and a proposed subclassification based on radiographic findings. *Oral Surg Oral Med Oral Pathol Oral Radiol Endod*, 72:119-25, 1991.
9. Scola SM, Watts PG : Dentinal dysplasia type I subclassification. *British J Orthod*, 14:175-179, 1987.
10. Witkop CJ Jr : Manifestations of genetic diseases in the human pulp. *Oral Surg Oral Med Oral Pathol Endod*, 32:278-316, 1971.
11. Brenneise CV, Dwornik RM, Brenneise EE : Clinical, radiographic, and histological manifestations of dentin dysplasia, type I : report of case. *JADA*, 119:721-723, 1980.
12. Melnick M, Levan LS, Brady J : Dentin dysplasia type I: a scanning electron microscopic analysis of the primary dentition. *Oral Surg Oral Med Oral Pathol*, 50:335-40, 1980.
13. Sauk JJ, Lyons HW, Trowbridge Ho, et al. : An electronoptic analysis and explanation for the etiology of dentin dysplasia. *Oral Surg Oral Med Oral Pathol*, 33:763-71, 1972.
14. Logan J, Becks H, Silverman S Jr, et al. : Dentinal dysplasia. *Oral Surg*, 15:317-33, 1962.
15. Seow WK, Shusterman S : Spectrum of dentin dysplasia in a family : case report and literature review. *Pediatr Dent*, 16:437-42, 1994.
16. Rosenburg LR, Phelan JA : Dentin dysplasia type II : review of the literature and report of a family. *ASDC J Dent Child*, 50:372-75, 1983.
17. Özer L, Karasu H, Aras K, et al. : Dentin dysplasia type I : Report of atypical cases in the permanent

- and mixed dentitions. *Oral Surg Oral Med Oral Pathol Oral Radiol Endod*, 98:85-90, 2004.
18. Kalk WWI, Batenburg RHK, Vissink A : Dentin dysplasia type I. Five cases within one family. *Oral surg Oral Med Oral Pathol Oral Radiol Endod*, 86:175-8, 1998.
  19. Morris ME, Augsburger RH : Dentinal dysplasia with sclerotic bone and skeletal anomalies inherited as an autosomal dominant trait. *Oral Surg Oral Med Oral Pathol*, 33:763-71, 1977.
  20. Steidler NE, Radden BG, Reade PC : Dentinal dysplasia: A clinicopathological study of eight cases and review of the literature. *Br J Oral Maxillofac Surg*, 22:274-86, 1984.
  21. Goldweber SS, Low ME : Hereditary opalescent-dentin. *JADA*, 55:413-4, 1957.
  22. Dym H, Levy J, Sherman PM : Dentinal dysplasia type I : review of the literature and report of a family. *ASDC J Dent Child*, 49:437-40, 1982.
  23. Rankow H, Miller AS : Dentin dysplasia: endodontic considerations and report of involvement of three siblings. *J Endod*, 10:384-6, 1984.
  24. Luffingham JK, Noble HW : Dentinal dysplasia. *Br Dent J*, 160:281-3, 1986.
  25. Perl T, Farman AG : Radiocular (type I) dentin dysplasia. *Oral Surg Oral Med Oral Pathol*, 43:746-53, 1977.
  26. Elzay RP, Robinson CT : Dentinal dysplasia. *Oral Surg Oral Med Oral Pathol*, 23:338-42, 1967.
  27. Brookerson KR, Miller AS : Dentinal dysplasia: report of case. *JADA*, 77:608-11, 1968.
  28. Peterson A : A case of dentinal dysplasia and/or calcification of the dental papilla. *Oral Surg Oral Med Oral Pathol*, 33:763-71, 1972.
  29. Baka'een G, Snyder CW, Baka'een G : Dentinal dysplasia type I: report of case. *ASDC J Dent Child*, 52:128-9, 1985.
  30. Tidwell E, Cunnungham CJ : Dentinal dysplasia: endodontic treatment with case report. *J Endod*, 5:372-6, 1979.

국문초록

## 상아질 이형성증 1형: 증례보고

류정아 · 김승혜 · 최병재 · 황충주\* · 이제호

연세대학교 치과대학 소아치과학교실, \*교정과학교실, 구강과학연구소

상아질 이형성증 1형에 관한 증례 보고이다. 상아질 이형성증 1형은 드물게 나타나는 치아 이상으로 상아질 형성 장애가 특징적으로 나타난다. 임상적으로 정상이지만, 방사선상 모든 치수강은 폐쇄되어 있으며, 짧고 무딘 치근의 형태 이상이 관찰된다. 조직학적 소견으로 비전형적 골양 상아질 및 소용돌이 모양의 관상 상아질이 관찰된다. 이 증례에선, 혼합치열기에 나타난 상아질 이형성증 1형의 임상적, 방사선학적, 조직 병리학적 소견 및 치료방법을 보고하는 바이다.

**주요어** : 상아질 이형성증, 치아 이상, 치수강 폐쇄