

The effect of *Actinobacillus actinomycetemcomitans* lipopolysaccharide on rat periodontal tissues

Chong-Cheol Kim¹, De-Zhe Cui², Young-Joon Kim^{1,2}

1. Department of Periodontology, Graduate School of Dentistry, Chonnam National University
2. Dental Science Research Institute, Graduate School of Dentistry, Chonnam National University

I. INTRODUCTION

Periodontitis is a chronic inflammatory disease characterized by destruction of gingival connective tissue and resorption of alveolar bone. Periodontopathic bacteria, such as *Actionbacillus actinomycetemcomitans* (*A. actinomycetemcomitans*) and *Porphyromonas gingivalis* (*P. gingivalis*), are thought to be involved in periodontal disease¹⁾. *A. actinomycetemcomitans* is a gram-negative, capnophilic, fermentative coccobacillus that has been implicated in the aetiology and pathogenesis of several forms of periodontal disease. Clinical, microbiological, and immunological studies have explored the correlation between *A. actinomycetemcomitans* and several types of periodontitis^{1,2)}. *A. actinomycetemcomitans* produces several tis-

sue-damaging products such as leukotoxin, lipopolysaccharide (LPS), and bone resorption-inducing toxin. Among these products, *A. actinomycetemcomitans* LPS has been considered to be involved in the pathogenesis of alveolar bone and connective tissue degradation in periodontitis³⁾.

LPS is a major component of the outer membrane of gram-negative bacteria and is known to induce bone resorption by enhancing osteoclastogenesis^{4,5)}. Although it is still not clear whether LPS could directly target osteoclast precursors, previous reports provided evidences that LPS indirectly influenced the osteoclast formation through osteoblasts or bone marrow stromal cells^{6,7)}. In addition, LPS induces the secretion of several cytokines such as interleukin (IL)-1, IL-6, and tumor necrosis factor- α .

* Correspondence: Young-Joon Kim, Department of Periodontology, Graduate School of Dentistry, Chonnam National University, 8, Hak 1 Dong, Dong-Gu, Gwangju, 501-757, Korea, (E-mail: youngjun @ chonnam.ac.kr)

Increasing these cytokines causes the imbalance of proteolytic enzymes which eventually leads to connective tissue and bone destruction^{8,9)}.

Bone resorption involves the removal of both the mineral and organic constituents of the bone matrix¹⁰⁾. Osteoclasts release proton and hydrochloric acid which lead to the dissolution of minerals, while the organic matrix is degraded by proteolytic enzymes. In addition, several enzymes including matrix metalloproteinases (MMPs) which are secreted by osteoblasts, degrading the non-mineralized organic matrix covering the bone surface, thereby facilitating bone resorption by osteoclasts¹¹⁾.

MMPs are the family of zinc-dependent endopeptidases, including collagenases, gelatinases and stromelysins which have the ability to degrade the organic components of organic matrices¹²⁾. Several collagenases (MMP-1, MMP-8, and MMP-13) and gelatinases (MMP-2 and MMP-9) have been considered to have a role in periodontitis. MMP-13 is protein in the MMPs family and although type II collagen is the main substrate target for this enzyme, it also degrades collagen types I, III and V, which are all major components of cartilage and bone¹³⁾. Recent studies have shown that MMP-13 plays a significant role in both the initiation and the progression of bone resorption. In periodontium, MMP-13 has been shown to exist at higher level in periodontal infected tissues than in healthy control tissues^{14,15)}. In peri-implantitis models of

bone loss, implants having > 3mm of bone loss had higher levels of MMP-13 from the peri-implant sulcus fluid at these sites¹⁶⁾. So, MMP-13 might be related not only to collagen degradation in connective tissues, but also directly or indirectly associated with alveolar bone destruction. However, there were no reports that the effects of *A. actinomycetemcomitans* LPS on MMP-13 production in vitro and in vivo. In addition, there were few studies on immunolocalization of MMP-13 in alveolar bone and its role in alveolar bone resorption. Therefore, the purpose of this study was to evaluate the effects of *A. actinomycetemcomitans* LPS on the expression of MMP-13 mRNA and osteoclastogenesis in vivo and in vitro study.

II. MATERIALS & METHODS

1. Cell culture

RAW 264.7 cells (murine macrophages) were obtained from RIKEN (JAPAN). Mouse periodontal ligament (mPDL) fibroblasts and RAW 264.7 cells were cultured in DMEM medium (Life technology, U.S.A), and supplemented with 10% fetal bovine serum.

2. Lipopolysaccharide (LPS) preparation

The procedures for LPS extraction from *A. actinomycetemcomitans* was carried out as previously described¹⁷⁾. In brief, LPS extraction consisted of culturing the *A. actinomycetemcomitans*

strain Y4 (serotype B) via anaerobic chamber using a modified Brucella- Broth Medium specific for anaerobes. After the growing process, each batch was centrifuged at 5000 rpm for 30 min. The supernatant was discarded and the cells were resuspended in sterile water to be centrifuged. The final pellet was frozen at -20°C until the total needed amount of bacteria had been obtained for the entire experiment. In a 3-day step procedure, the bacteria were sequentially treated with lysozyme, DNase, RNase and proteases to extract and purify the LPS.

3. Reverse transcription-polymerase chain reaction (RT-PCR) analysis

Cells were grown to near confluency in 6-well dishes, deinduced and then treated with $1\ \mu\text{g}/\text{ml}$ of *A. actinomycetemcomitans* LPS for 24 hours. A negative control that represented by the PBS used to dilute the LPS and a positive control that stimulated IL- 1β ($1\ \mu\text{g}/\text{ml}$) were also included.

After the treatment periods, total RNA was collected with Trizol[®] reagent (Invitrogen, U.S.A), according to the instructions provided by the manufacturer. Briefly, approximately 1 ml of Trizol[®] reagent was added to each well to cell lysis and this cell lysate was homogenized by passing several times through a pipette. This solution was transferred to Eppendorf tubes, incubated at room temperature (RT) for 15-30 min, and then 0.2 ml of chloroform per ml of Trizol[®] reagent was added. After vigorously shaking

the tubes and centrifugation at $10,000 \times g$ for 15 min at $2-8^{\circ}\text{C}$, the aqueous phase was collected and transferred to a fresh tube. Total RNA was precipitated by adding isopropyl alcohol, washed in 75% ethanol and redissolved in RNase-free water for storage at -70°C until use.

Using spectrophotometry, 5 μg of RNA was quantitated (read at an absorbance of 260 nm) and used for cDNA synthesis with oligo (dT) 12-18 primer by reverse transcriptase (RT) reactions (RT-PCR primers: MMP-13 328 bp S5-GACTT CACGATGGC ATTGCTG-3, A5-G CATCAACCTGCTGAG GATGC-3 GAPDH 418bp S5-ATCCATGGCA CCGTCAAGGC T-3, A5-TCAGGTCCACCA CTGACA CGTT3;). Approximately 2 μl of RT product was used as a template for PCR.

The PCR products were checked by 2% agarose gel electrophoresis, stained by ethidium bromide. Semi-quantitative PCR was performed. Semi-quantitative differences of MMP-13 mRNA expression were normalized by GAPDH.

4. Osteoclastogenesis assays

RAW 264.7 cells were cultured in the presence of $1\ \mu\text{g}/\text{ml}$ of *A. actinomycetemcomitans* LPS for 5 days. For controls, RAW 264.7 cells were cultured only with culture media. Tartrate resistant acid phosphatase (TRAP) staining was performed as dictated from the commercial kit (Sigma, U.S.A).

5. Creation of LPS-induced alveolar bone resorption

The following protocol for the induction of alveolar bone loss had been adapted as previously reported using *A. actinomycetemcomitans* endotoxin instead of *E. coli* endotoxin¹⁸⁾. Seven adult female Sprague-Dawley rats (approximately weight 200g each) were served as periodontitis group. In brief, rats had experimental periodontitis which created by delivery of 6 μ l of 5 μ g/ml of *A. actinomycetemcomitans* endotoxin by injection into the interproximal regions of palatal gingiva between the maxillary first (M1), second (M2), and third molars (M3). The administrations were repeated two times per week over 8-week time period. Four adult female Sprague-Dawley rats received LPS vehicle (1x phosphate buffered saline; PBS) between M1, M2, and M3 served as control group.

6. Histological analysis

Rats were sacrificed at 8 weeks after surgery and block biopsies were taken and placed into 10% formalin solution, decalcified with 5% nitric acid for 2-3 weeks, and then embedded in paraffin. Four to five μ m sagittal sections were prepared for TRAP stains and immunohistochemical stains.

7. Tartrate resistant acid phosphatase (TRAP) assay

TRAP histochemistry was used to identify multinucleated osteoclastic-like cells. Staining was carried out as described previously¹⁹⁾. In brief, tissues were stained using naphthol ASTR-phosphate (in N-dimethyl formamide) as a substrate. Para-rosaniline hydrochloride in tartaric acid at 37°C for 60 min was used as coupling agent. After 30 min of dehydration in 70% alcohol, sections were counterstained with hematoxyline. Negative controls were provided by omitting the substrate. TRAP-positive multinucleated cells that had at least 3 nuclei or more, adjacent to the alveolar bone were regarded as 'osteoclasts'. The number of osteoclasts was counted under a light microscope.

8. Immunohistochemical staining

Tissue sections were stained with anti-MMP-13 at a dilution of 1:100. The presence of MMP-13 was detected using Vectastain Elite ABC reagent and Nova Red (Vector Labs, U.S.A) according to manufactures's instructions. Briefly, after deparaffinization, hydration and washing in phosphated-buffered saline (PBS), the sections were exposed to 5% hydrogen peroxide for 15 mins. Next, the sections were incubated with 1:10 horse serum for 1 hour, to block non-specific protein binding. After incubation, the sections incubated with the primary antibody for overnight. After 3 minutes washing for three times with 1X PBS, the sections were incubated with secondary antibody for 30 minutes. Then, sections were rinsed with 1X

PBS and stained with methyl green.

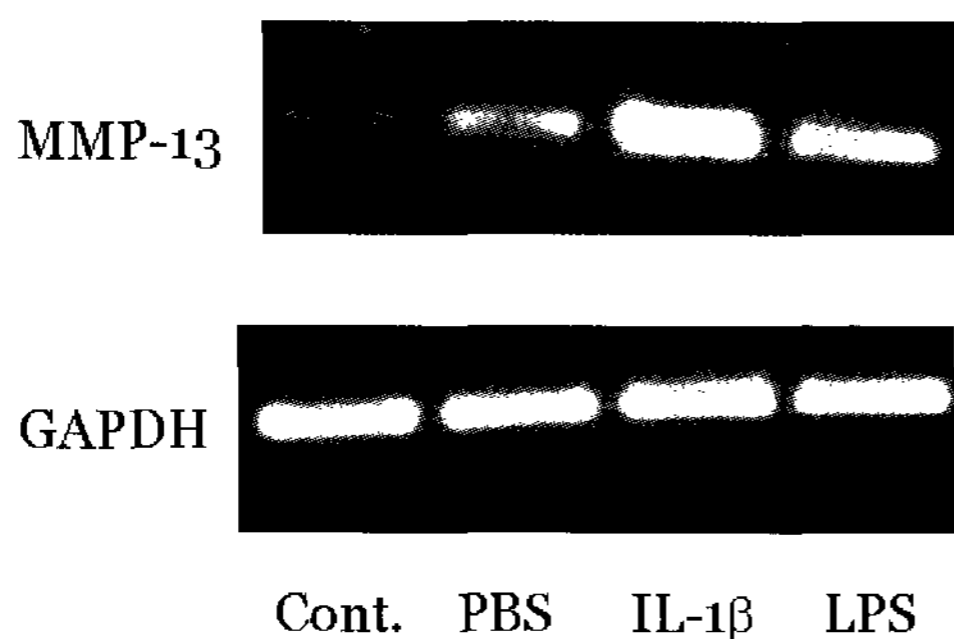
9. Statistical analysis

The data were analyzed and compared by student t-test and by DUNCAN multiple range test was done using SAS program.

III. RESULTS

1. Effects of *A. actinomycetemcomitans* LPS on MMP-13 mRNA expression

Steady-state MMP-13 mRNA expression in mouse PDL (mPDL) cells was determined



by RT-PCR. Figure 1 illustrated the effects of *A. actinomycetemcomitans* LPS on MMP-13 gene expression. MMP-13 gene expression was increased approximately 2.6-fold with *A. actinomycetemcomitans* LPS stimulated mouse PDL fibroblases for 24 hours, compared to PBS stimulated cells (Figure 1).

2. Osteoclastogenesis assay

Figure 2 showed the effects of *A. actinomycetemcomitans* LPS on osteoclastogenesis. After stimulated with LPS, RAW cells induced TRAP-positive cell formation.

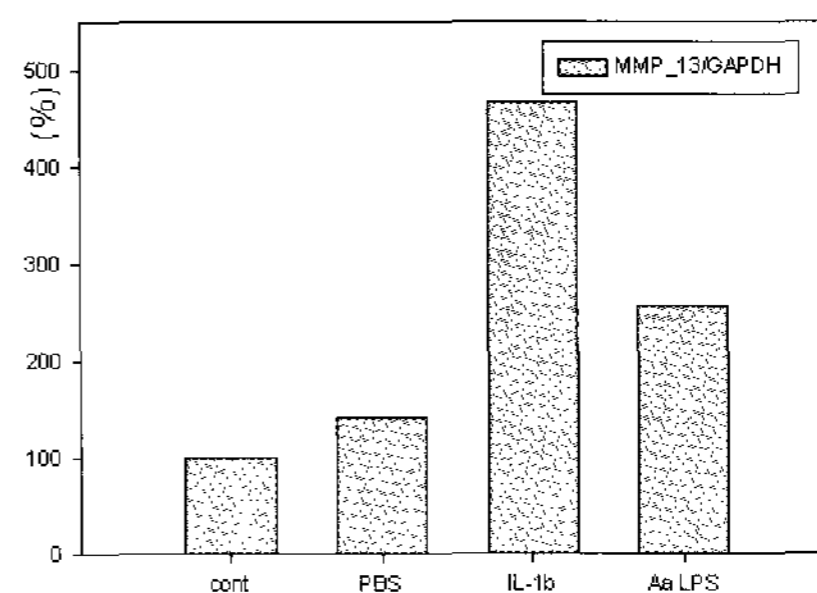


Figure 1. RT-PCR analysis of matrix metalloproteinase-13 (MMP-13) and glyceraldehyde-3-phosphate dehydrogenase (GAPDH) mRNA expression in mPDL cells.

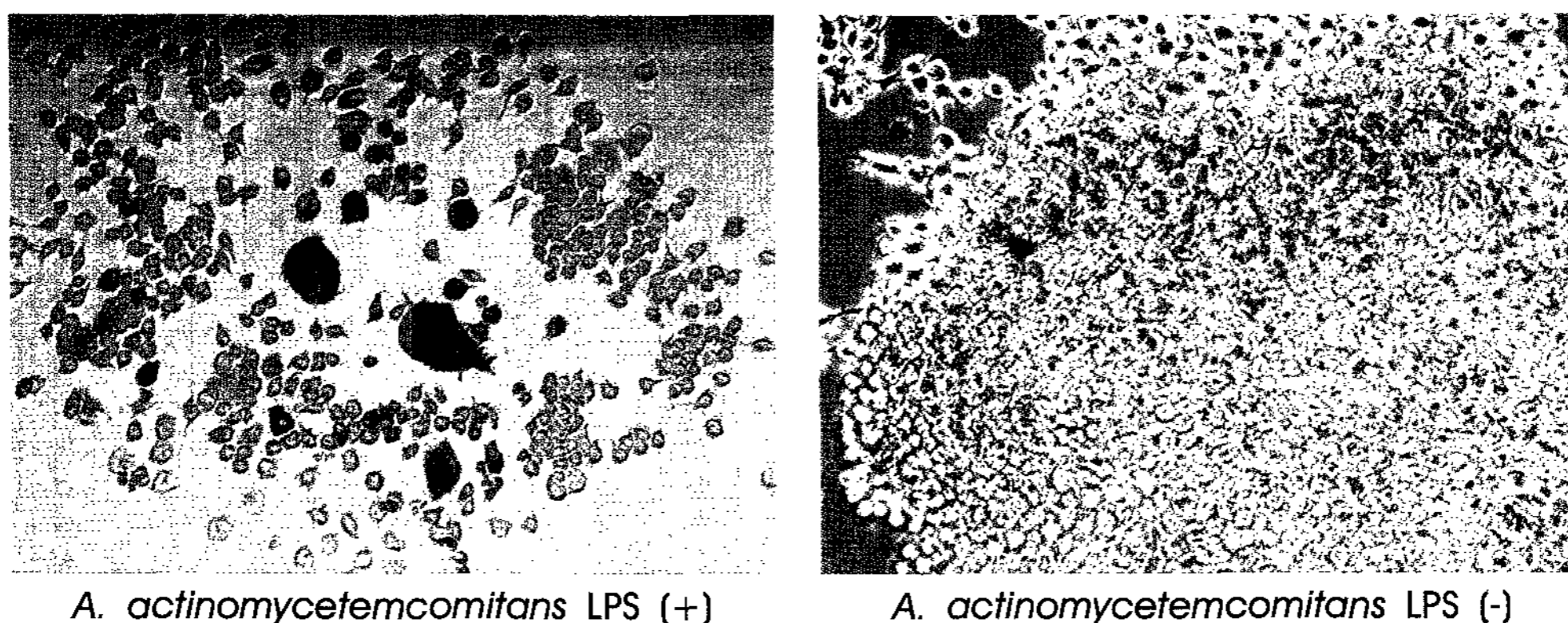


Figure 2. The effect of *A. actinomycetemcomitans* LPS on osteoclast formation. RAW 264.7 cells were cultured for 7 days with or without LPS. Osteoclastogenesis increase in RAW 264.7 with *A. actinomycetemcomitans* LPS.

Table 1. Linear measurement of maxillary alveolar bone loss (from CEJ to alveolar bone crest)

group	CEJ-AB
control group (n=4)	0.4 ± 0.1 mm
periodontitis group (n=7)	1.0 ± 0.4 mm*

* Statistically significant difference (p<0.001) between control and periodontitis group

3. In vivo studies

A. Histometric analysis

A. actinomycetemcomitans LPS injection sites showed significant loss of the palatal

and interproximal bone. However, PBS-injection sites showed little bone loss. Linear measurements of alveolar bone loss from cemento-enamel junction (CEJ) to the alveolar bone crest were done. *A. actinomycetemcomitans* LPS in-

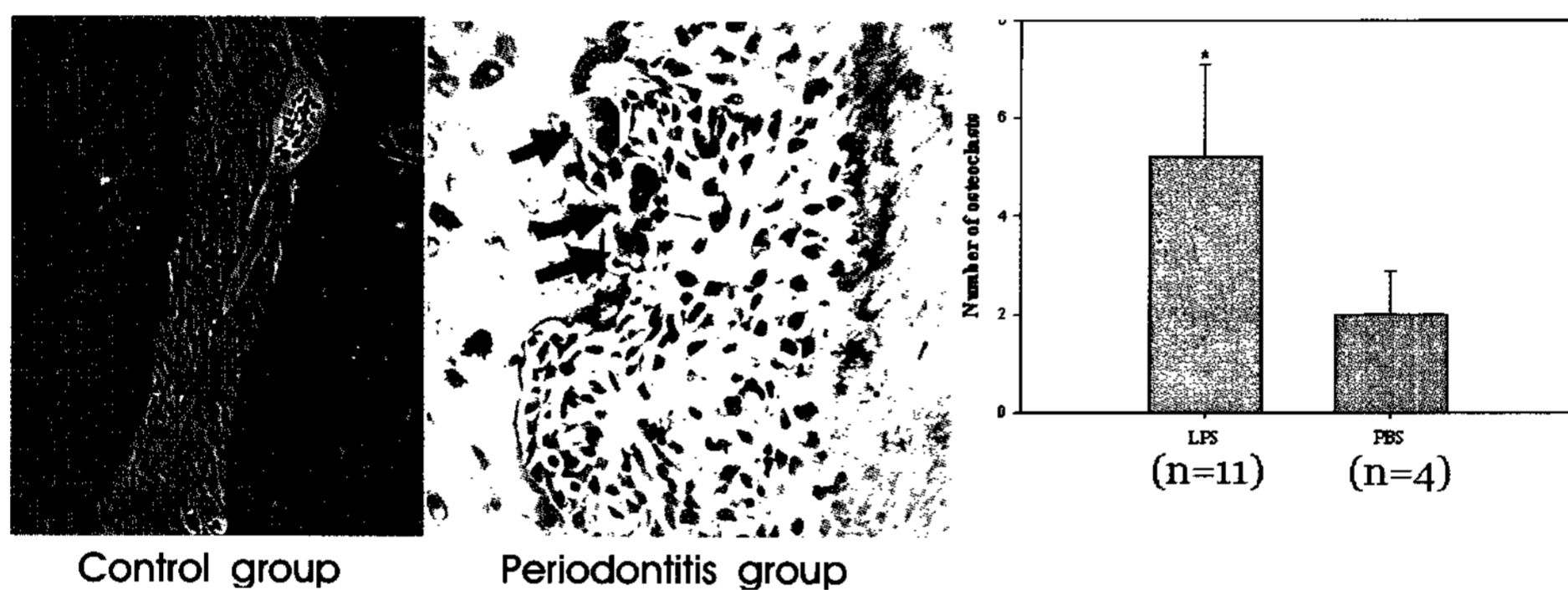


Figure 3. Light micrographs of rat periodontal tissues. TRAP positive multinucleated cells (arrows) are shown at irregular alveolar bone surfaces in periodontitis group. Magnifications 100× (control group), 200× (periodontitis group). (AB : alveolar bone, PDL : periodontal ligament, C : cementum)

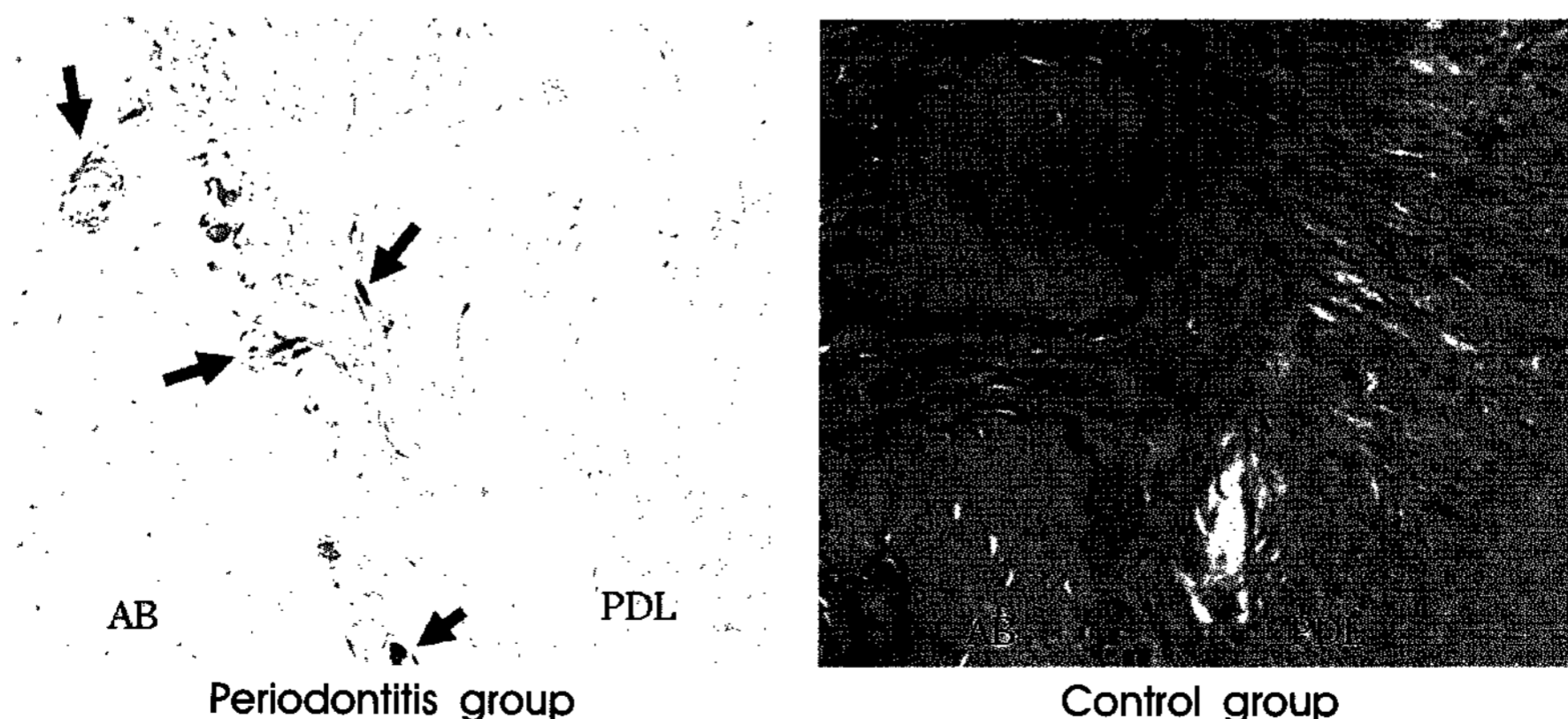


Figure 4. Light micrographs of rat periodontal tissues. MMP-13 immunoreactivities are observed in both periodontitis group and control group (arrows). MMP-13 immunoreactivities are seen on alveolar bone surfaces and periodontal ligaments in periodontitis group. Magnifications 100×. (AB : alveolar bone, PDL : periodontal ligament)

jection induced severe bone loss whereas PBS-injection induced unchanged. LPS injection sites showed 1.0 ± 0.4 mm from CEJ to alveolar bone crest. However, PBS-injected sites showed 0.4 ± 0.1 mm ($P < 0.001$, Table 1)

B. Tartrate-resistant acid phosphatase (TRAP) staining

TRAP-positive multinucleated osteoclast-like cells were mainly observed in surface of the alveolar bone facing the PDL. Control group had few TRAP positive cells and alveolar bone margin showed relatively smooth surfaces. TRAP positive multinucleated cells were shown at irregular alveolar bone surfaces in periodontitis group (Figure 3). Occasionally, TRAP-positive multinucleated osteoclast-like cells were observed in bone marrow in periodontitis group.

Significantly more TRAP-positive multinucleated osteoclast-like cells were observed in periodontitis group when compared with control group ($p < 0.001$).

C. Immunostaining for MMP-13

MMP-13 immunopositive cells were observed at the PDL near to alveolar bone and at irregular bone surfaces in both LPS-injection. Perivascular cells also showed MMP-13 positive activity. The number of MMP-13 immunopositive cells increased in LPS-injection sites. MMP-13 immunopositive cells were not observed in epithelial and gingival connective tissues (Figure 4).

IV. DISCUSSION

Lipopolysaccharide (LPS) is a major component of the outer membrane of gram-negative bacteria, including periodontopathogens and has been suspected as one of the major virulence factors in the development of periodontal disease. This constituent activates and stimulates both gingival and peripheral blood mononuclear and polymorphonuclear cells to produce arrays of cytokines necessary for the induction of host defenses as well as tissue destruction^{20,21}). LPS from periodontopathogens, such as *A. actinomycetemcomitans*, *P. gingivalis*, and *E. coli* stimulate bone resorption both in vitro and in vivo^{3,4,7-9,17}). So, in this study, it was proposed that *A. actinomycetemcomitans* LPS would directly or indirectly induce bone resorption by stimulating osteoblasts or other type of cells to produce cytokines including MMP-13 necessary for alveolar bone resorption.

Human longitudinal studies of periodontal diseases indicate many problems in the study of the mechanisms of disease as there are many inter-patient variables that are difficult to control, such as the level of disease activity, individual disease susceptibility and time of disease progression. Therefore, animal models of periodontitis have been used to evaluate both the pathogenesis of periodontal diseases and various periodontal treatment modalities²²). In several animal models, experimental periodontitis has been induced by placing silk or nylon ligatures to encourage the accumulation of plaque in the sub-

gingival area. However, the microflora in ligature-induced periodontitis differ from those in human periodontitis²³⁾. The bacterial products, mainly LPS, initiate a local host response in gingival tissues that involves recruitment of inflammatory cells, generation of prostaglandins and cytokines, and activation of osteoclasts. However, the periodontitis models using *E. coli*'s endotoxin result in very rapid and severe bone destruction (typically >50% or more) over a 1-2 week period²⁴⁾. These models represent acute models of bone resorption.

With regards to limitations of several experimental periodontitis models, it was developed an LPS-mediated bone resorption model in rats whereby it would promote alveolar bone resorption at palatal region of molars using LPS-derived from the periodontal pathogen, *A. actinomycetemcomitans* strain Y4. These thoughts were based on the evidence linking *A. actinomycetemcomitans* to human periodontal disease. This experimental periodontitis model was a "chronic" type of disease and showed a significant amount of bone loss after 8-week LPS-injection periods. Because *A. actinomycetemcomitans* LPS had more potent bone resorptive activity than *P. gingivalis* LPS in our preliminary study, *A. actinomycetemcomitans* LPS was used for inducing alveolar bone resorption.

The present study showed that injection of *A. actinomycetemcomitans* LPS into rat palatal gingiva caused destruction of alveolar bone in loss of alveolar bone and suggested that *A. actinomycetemcomitans* LPS would

directly or indirectly stimulate osteoclast activation at the injection sites (Table 1).

Tartrate resistant acid phosphatase (TRAP) is an enzyme, used as a marker of osteoclast function, but also expressed by other differentiated cells of mononuclear phagocyte lineage, such as macrophages^{18,25)}. In this study, the osteoblasts were present on bone lining surface, and TRAP-positive multinucleated osteoclast-like cells were observed on resorption lacunae of alveolar bone. The number of TRAP-positive multinucleated osteoclast-like cells was significantly higher in LPS-injection sites compared to PBS-injection sites ($p < 0.001$, Figure 3). The present study also showed that *A. actinomycetemcomitans* LPS stimulated murine macrophages to differentiate to the osteoclast-like cells (Figure 2). These results were in line with other studies^{26,27)} and suggested that *A. actinomycetemcomitans* LPS might mediate osteoclast differentiation.

Periodontal ligament resides between the cementum of the roots of the teeth and the alveolar bone. In this location, PDL fibroblasts are uniquely situated to maintain space and the overall integrity of the PDL²⁸⁾. PDL fibroblasts function as support cells for periodontal tissues regeneration, however, produce various inflammatory mediators when stimulated by bacteria and/or bacterial products²⁹⁾. In this study, *A. actinomycetemcomitans* LPS was administered into rat palatal gingiva. This study showed the stimulatory effects of *A. actinomycetemcomitans* LPS on expression of MMP-13

mRNA in periodontal ligament fibroblasts near alveolar bone. Generally, the expression of MMP-13 is regulated by inflammatory cytokines such as IL-1 and prostaglandins. So, taken together with other reports, it is proposed that *A. actinomycetemcomitans* LPS would stimulate inflammatory cytokines release in PDL fibroblasts and these inflammatory cytokines induce MMP-13 in PDL fibroblasts. Finally, MMP-13 produced by PDL fibroblasts, degrades collagen constituents in PDL and destroys overall integrity of PDL and results in pathologic tissue breakdown.

Immunostaining for MMP-13 in this study also showed that MMP-13 was localized on the osteoblasts at irregular bone surfaces and perivascular area. Sakamoto and Sakamoto³⁰⁾ proposed that collagenases secreted by osteoblast-lineage cells play a pivotal role in osteoclastic bone resorption. It is generally supposed that collagenase in the vicinity of bone lining cells plays a significant role in exposing mineralized bone matrix, by removing non-mineralized collagen fibrils from the bone surface prior to osteoclastic bone resorption. Removal of these fibrils appears to be essential for differentiation and activation of osteoclasts. Taken together, it indicated that after osteoclasts destroyed inorganic components of bone, osteoblast-lineage cells secreted MMP-13 and degraded organic matrix of bone during bone resorption.

As regards to periodontal tissue destruction, proinflammatory cytokines stimulate metalloproteinases such as MMP-1, MMP-3,

and MMP-13, which degrade extracellular matrix components in periodontium^{31,32)}. Moreover, IL-1 and TNF- α induce bone resorption by indirectly stimulating IL-6 or directly stimulating downstream effectors associated with osteoclast differentiation and activation, such as receptor activator of nuclear factor kappa B ligand (RANKL). Proinflammatory cytokine productions including MMP-13 expression in murine osteoblasts are increased by bacterial LPS. LPS signals are transduced by CD 14 and toll-like receptors and also mediated through MEK and p38 MAP kinase pathway³¹⁾. Recent studies of both osteoblasts and periodontal ligament fibroblasts have shown that the IL-1 β or TNF- α -induced MMP-13 production can be blocked with p38 MAP kinase inhibitors^{32,33)}. It was confirmed that *A. actinomycetemcomitans* LPS-induced MMP-13 expression was repressed by p38 MAP kinase inhibitors in our lab. When PDL fibroblasts were stimulated with *A. actinomycetemcomitans* LPS for 2 days and then added RAW cells for additional 7 days, TRAP-positive cells were formed in LPS stimulated co-culture system (data unshown). Pre-treatment of mouse PDL fibroblasts with p38 MAP kinase inhibitor decreased the numbers of TRAP-positive cells. Therefore, further studies are needed to demonstrate the functional consequence of blocking of MMP-13 or receptor activation of nuclear factor κ B ligand (RANKL) when p38 MAP kinase inhibitor prevents LPS- or cytokines-mediated bone resorption in vivo and

in vitro model.

In summary, this study showed that *A. actinomycetemcomitans* LPS played a significant role in the alveolar bone resorption in rat. *A. actinomycetemcomitans* LPS induce alveolar bone resorption by formation of osteoclasts and the expression of MMP-13 in osteoblasts. This *A. actinomycetemcomitans* LPS-induced experimental periodontitis model also represents chronic models of bone resorption and this model would provide the window of efficacy that one could be able to observe for some therapeutics.

V. CONCLUSION

Bone resorption involves the removal of both the mineral and organic constituents of the bone matrix, which is caused by osteoclasts and matrix metalloproteinases (MMPs).

The bacterial products, mainly lipopolysaccharide (LPS), initiate a local host response in gingival tissues that involves recruitment of inflammatory cells, generation of cytokines, elaboration of lytic enzymes and activation of osteoclasts. *A. actinomycetemcomitans* is considered to be associated with aggressive periodontitis. *A. actinomycetemcomitans* produces a lot of tissue damaging products, including LPS. Among these products, LPS induces bone resorption. Recent studies have shown MMP-13 plays a role in both the initiation and progression of bone resorption. Therefore, MMP-13 would be related not only to collagen degradation in connective tissues, but also directly or in-

directly associated with alveolar bone destruction. However, there were few reports about the effects of *A. actinomycetemcomitans* LPS on MMP-13 production in vitro and in vivo. So, the purpose of this study was to evaluate the effects of *A. actinomycetemcomitans* LPS on osteoclastogenesis and the expression of MMP-13 in periodontal ligament (PDL) space and alveolar bone.

The results are as follows;

1. MMP-13 gene expression was increased approximately 2.6-fold with *A. actinomycetemcomitans* LPS compared to control in mouse PDL fibroblasts (Figure 1).
2. Osteoclastogenesis increased in RAW 264.7 when stimulated with *A. actinomycetemcomitans* LPS compared to control (Figure 2).
3. *A. actinomycetemcomitans* LPS injection induced severe bone loss. PBS-injection induced unchanged. LPS injection sites showed 1.0 ± 0.4 mm from cemento-enamel junction to alveolar bone crest. PBS-injected sites showed 0.4 ± 0.1 mm ($P < 0.001$, Table 1).
4. TRAP-positive multinucleated osteoclast-like cells were mainly observed in surface of the alveolar bone facing the PDL in both periodontitis and control groups. The number of TRAP-positive multinucleated osteoclast-like cells was significantly higher in periodontitis group when compared with control group ($p < 0.01$, Figure 3).

5. Immunolocalization of MMP-13 was mainly observed at the PDL fibroblasts near to alveolar bone and osteoblasts lining on irregular bone surfaces in periodontitis groups. Perivascular cells also showed MMP-13 positive activity. In control group, MMP-13 immunopositive cells were observed in surface of the alveolar bone near to the PDL, however, MMP-13 immunopositive cells were not observed in PDL fibroblasts (Figure 4).

These results suggest that *A. actinomycetemcomitans* LPS induce alveolar bone resorption by formation of osteoclasts and the expression of MMP-13 in osteoblasts. This *A. actinomycetemcomitans* LPS-induced experimental periodontitis model also represents chronic inflammatory models of bone resorption and this model might provide the window of efficacy that one would be able to observe for some therapeutics.

VI. REFERENCES

1. Slot J, Listgarten MA. *Bacteroides gingivalis*, *Bacteroides intermedius* and *Actinobacillus actinomycetemcomitans* in human periodontal diseases. J Clin Periodontol 1988;15:85-93.
2. Zambon JJ, Christersson LA, Genco RJ. Diagnosis and treatment of localized juvenile periodontitis. J Am Dent Assoc 1986;115:295-299.
3. Ueda N, Koide M, Ohguchi M et al. Involvement of prostaglandin E2 and interleukin-1 alpha in the differentiation and survival of osteoclasts induced by lipopolysaccharide from *Actinobacillus actinomycetemcomitans* Y4. J Periodontal Res 1998;33:509-516.
4. Iino Y, Hopps RM. The bone resorbing activities in tissue culture of lipopolysaccharides from bacteria *Actinobacillus actinomycetemcomitans*, *Bacteroides gingivalis* and *Capnocytophaga ochracea* isolated from human mouth. Arch Oral Biol 1984;29:59-63.
5. Kiley P, Holts SC. Characterization of the lipopolysaccharide from *Actinobacillus actinomycetemcomitans* Y4 and N27. Infect Immun 1980;30:862-873.
6. Slots J, Genco RJ. Black-pigmented *Bacteroides* species, *Capnocytophaga* species, and *Actinobacillus actinomycetemcomitans* in human periodontal disease: virulence factors in colonization, survival, and tissue destruction. J Dent Res 1984;63:412-421.
7. Suda K, Woo JT, Takami M et al. Lipopolysaccharide supports survival and fusion of preosteoclasts independent of TNF-alpha, IL-1, and RANKL. J Cell Physiol 2002;190:101-108.
8. Kikkawa I, Saito S, Tominaga K et al. Lipopolysaccharide (LPS) stimulates the production of tumor necrosis factor (TNF)-alpha and expression of inducible nitric oxide synthase (iNOS) by osteoclasts (OCL) in murine bone marrow cell culture. Microbiol Immunol 1998;42:591-598.
9. Kondo A, Koshihara Y, Togari A. Signal transduction system for IL-6 synthesis stimulated by lipopolysaccharide in human osteoblasts. J Interferon Cytokine Res 2001;21:943-950.
10. Blair HC, Schlesinger PH, Ross FP, Teitelbaum SL. Recent advances toward understanding osteoclast physiology. Clin Orthop 1993;294:7-22.
11. Delaisse JM, Engsig MT, Everts V.

- Proteinase in bone resorption: obvious and less obvious roles. *Clin Chim Acta* 2000; 291:223-234.
12. Jeffrey JJ. Interstitial collagenases. In: Matrix metalloproteinases. Parks CW, Mecham RP, editors. San Diego, CA: Academic Press, p12-42, 1998.
 13. Freije JMP, Diez-Itza I, Balbin M et al. Molecular cloning and expression of collagenase-3, a novel human matrix metalloproteinase produced by breast carcinomas. *J Biol Chem* 1994;269:16766-16773.
 14. Tervahartiala T, Pirila E, Ceponis A et al. The in vivo expression of the collagenolytic matrix metalloproteinases (MMP-2, -8, -13, and -14) and matrilysin (MMP-7) in adult and localized juvenile periodontitis. *J Dent Res* 2000;79:1969 -1977.
 15. Hernandez M, Valenzuela MA, Lopez-Otin C et al. Matrix metalloproteinase-13 is highly expressed in destructive periodontal disease activity. *J Periodontol* 2006; 77:1863-1870.
 16. Ma J, Kitti U, Teronen O et al. Collagenases in different categories of peri-implant vertical bone loss. *J Dent Res* 2000;79:1870-1873.
 17. Wilson ME, Hamilton RG. Immunoglobulin G subclass response of localized juvenile periodontitis patients to *Actinobacillus actinomycetemcomitans* Y4 lipopolysaccharide. *Infect Immun* 1992;60:1806-1812.
 18. Kirkwood KL, Li F, Rogers JE et al. A p38-alpha selective mitogen-activated protein kinase inhibitor prevents periodontal bone loss. *J Pharmacol Exp Ther.* 2007; 320:56-63.
 19. Minkin C. Bone acid phosphatase: tartrate resistant acid phosphatase as a marker of osteoclast function. *Calcif Tissue Int* 1982;34:285-290.
 20. Baker PJ. The role of immune responses in bone loss during periodontal disease. *Microbes Infect* 2000;2:1181-1192.
 21. Madianos PN, Bobetsis YA, Kiane DF. Generation of inflammatory stimuli: how bacteria set up inflammatory responses in the gingiva. *J Clin Periodontol (suppl)* 2005;32:57-71.
 22. Klausen B. Microbiological and immunological aspects of experimental periodontal disease in rats: A review article. *J Periodontol* 1991;62:59-73.
 23. Samejima Y, Ebisu S, Okada H. Effect of infection with *Eikenella corrodens* on the progression of ligature-induced periodontitis in rats. *J Periodontal Res* 1990; 25:308-315.
 24. Ramamurthy NS, Xu JW, Bird J et al. Inhibition of alveolar bone loss by matrix metalloproteinase inhibitors in experimental periodontal disease. *J Periodontal Res* 2002;37:1-7.
 25. Snipes RG, Lam KW, Dodd RC et al. Acid phosphatase activity in mononuclear phagocytes and the U937 cell line: monocyte-derived macrophages express tartrate resistant acid phosphatase. *Blood* 1986;67: 729-734.
 26. Jiang J, Li H, Fahid FS et al. Quantitative analysis of osteoclast-specific gene markers stimulated by lipopolysaccharide. *J Endod* 2006;32:742-746.
 27. Jiang Y, Mehta CK, Hsu TY, Alsulaimani FF. Bacteria induced osteoclastogenesis via an osteoblast-independent pathway. *Infect Immun* 2002;70:3143-3148.
 28. Pitaru S, McCulloch CAG, Narayanan SA. Cellular origins and differentiation control mechanisms during periodontal development and wound healing. *J Periodontal Res* 1994;29:81-94.
 29. Ishihara Y, Nishihara T, Maki E et al.

- Role of interleukin-1 and prostaglandin *in vitro* bone resorption induced by *Actinobacillus actinomycetemcomitans* lipopolysaccharide. J Periodontal Res 1991;26:155-160.
30. Sakamoto S, Sakamoto M. Biochemical and immunohistochemical studies on collagenase in resorbing bone in tissue culture. A novel hypothesis for the mechanism of bone resorption. J Periodontal Res 1982;17:523-526.
 31. Kondo A, Koshihara Y, Togari A. Signal transduction system for interleukin-6 synthesis stimulated by lipopolysaccharide in human osteoblasts. J Interferon Cytokine Res 2001;21:943-950.
 32. Chung CC, Cui DZ, Chung HJ, Kim YJ. Role of MAP kinase on MMP-13 expression in rat periodontal ligament cells. J Kor Acad Periodontol 2006;36:85-96.
 33. Rossa C, Ehmann K, Liu M et al. MKK3/6-p38 MAPK signaling is required for IL-1beta and TNF-alpha-induced RANKL expression in bone marrow stromal cells. J Interferon Cytokine Res 2006;26:719-729.

Actinobacillus actinomycetemcomitans 내독소가 백서 치주조직에 미치는 영향

김종철¹, 쇠득철², 김영준^{1,2}

1. 전남대학교 치의학전문대학원 치주과학교실
2. 전남대학교 치의학전문대학원 치의학연구소

치조골 흡수는 파골세포와 matrix metalloproteinases (MMPs)에 의한 골의 무기질과 유기질의 파괴로 일어나는 과정이다. 세균성 산물, 주로 내독소는 치은조직 내에서 염증세포의 유주, 사이토카인 생산, 조직파괴 효소 분비 및 파골세포 활성화 등의 국소 면역반응을 유도한다. *A. actinomycetemcomitans*는 급진성 치주염의 원인 균주중 하나로 그 내독소는 치조골의 흡수와 관련된다. MMP-13은 세균성 산물이나 염증성 사이토카인의 자극에 의해 분비되며, 최근의 연구 결과들은 MMP-13이 치주질환의 진행과 골 흡수 과정에서 일정한 역할을 담당하는 것으로 보고하고 있으나 *A. actinomycetemcomitans* 내독소와 MMP-13과의 관련성에 대한 연구는 미미하다. 이에 이번 연구에서는 *A. actinomycetemcomitans* 내독소에 의한 MMP-13의 발현과 파골세포 형성을 세포배양을 통하여 관찰하였고, 백서 구개부 치은에 *A. actinomycetemcomitans* 내독소를 주입하여 흡수가 진행되고 있는 치조골에서 파골세포의 분화와 MMP-13의 발현을 TRAP 염색, 면역조직화학적 방법 등을 통해 관찰하여 다음과 같은 결과를 얻었다.

MMP-13 mRNA의 발현은 *A. actinomycetemcomitans* 내독소 (1 ug/ml)로 24시간 자극한 마우스 치주인대 섬유모세포에서 생리식염수로 자극한 세포에 비하여 약 2.6배 증가하였으며 마우스 대식세포에서는 TRAP 양성 세포가 대조군보다 더 많이 나타났다. *A. actinomycetemcomitans* 내독소를 주입한 백서 치주조직에서는 대조군보다 더 심한 골소실을 보였다. TRAP-양성 다핵 파골세포 유사세포는 치주염군과 대조군 모두 치조골에서 관찰되었다. TRAP-양성 다핵 파골세포 유사세포는 치주염군에서 대조군보다 유의하게 많은 숫자가 관찰되었으며 치주염군에서 대조군보다 유의하게 많은 숫자가 관찰되었다. MMP-13 면역양성 반응은 치주염군에서 거친 골연을 갖는 치조골상에 배열된 조골세포와 그 인접한 치주인대에서 관찰되었으며 대조군에서는 MMP-13 면역 양성 반응이 치조골 표면에서만 일부 관찰되었다.

이상의 결과는 *A. actinomycetemcomitans* 내독소가 MMP-13의 발현을 증가시키며 파골세포의 활성을 통하여 치조골의 흡수를 유도함을 시사한다. 또한 *A. actinomycetemcomitans* 내독소 투여에 의한 실험적 모델은 백서에서 중등도의 골 소실을 동반한 만성 치주염 모델로 향후 치주질환 치료제의 효과를 평가하는데 유용하게 사용될 수 있으리라 기대된다.