

## Joubert syndrome with peripheral dysostosis - A case report of long term follow-up -

Jung Tae Kim, M.D.\*<sup>†</sup>, Sun Jun Kim, M.D.\*<sup>†</sup>  
Chan-Uhng Joo, M.D.\*<sup>†</sup>, Soo Chul Cho, M.D.\*<sup>†</sup> and Dae-Youl Lee, M.D.\*<sup>†</sup>

Department of Pediatrics\*, Institute for Medical Science<sup>†</sup>, Chonbuk National University  
Medical School, Jeonju, Jeonbuk, Korea

This report describes the long-term follow-up of a 10-year-old female patient with Joubert syndrome with short stature and brachydactyly. She presented with hyperpnea alternated with hypopnea, uncontrolled jerking eye movements, and hypotonia during early infancy. She was diagnosed with Joubert syndrome based on clinical symptoms and typical MRI findings at 5 months of age. Abnormal ventilation and eye movements disappeared at around 4 years of age. Head circumference kept within normal range for her age, but her height and weight growth were markedly retarded. Simple X-ray showed an enlarged skull with increased digital markings, hypoplasia of facial bones, and abnormal enchondral bone formations in hands and feet. This article is the first report of Joubert syndrome with peripheral dysostosis. (*Korean J Pediatr* 2007;50:315-318)

**Key Words:** Joubert syndrome, Peripheral dysostosis, Brachydactyly, Short stature

### Introduction

The most common clinical features of Joubert syndrome in infants include hyperpnea and hypopnea, wandering eye movements, mental retardation, and ataxia<sup>1)</sup>. A variety of other minor abnormalities have been reported, including polydactyly<sup>2,3)</sup>, cleft lip or palate, retinal dysplasia, kidney abnormalities (renal cysts), coloboma, meningoencephalocele, microcephaly, low-set ears, tongue abnormalities, liver disease and duodenal atresia<sup>4)</sup>. It is quite uncertain whether the peripheral dysostosis in this patient is a coincidental finding or is related to Joubert syndrome, because peripheral dysostosis in Joubert syndrome has not been documented yet.

There are some reports of Joubert syndrome with polydactyly<sup>2)</sup>. To our knowledge, this may be the first case of Joubert syndrome with short stature and unique peripheral dysostosis.

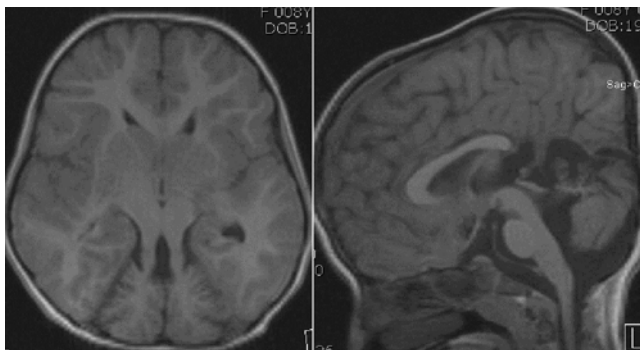
### Case Report

This female patient is the first child of healthy unrelated parents. She was born at term after an uneventful pregnancy and normal delivery. Abnormal breathing and wandering jerking eye movements were detected after delivery. She was referred to our clinic at 5 months of age with hyperpnea, hypopnea, axial hypotonia, and abnormal eye movements. Height was 62 cm (10<sup>th</sup> percentiles), weight was 5 kg (<3<sup>rd</sup> percentiles), head circumference was 43.8 cm (50<sup>th</sup> percentiles). She was diagnosed with Joubert syndrome by typical clinical manifestations and MRI findings: complete absence of cerebellar vermis, typical molar sign, and horizontal cerebellar peduncles. She was monitored on a regular basis in the outpatient clinic. Abnormal jerking eye movements and hyperventilation persisted until around 3 years of age. Her height (92.5 cm) and weight (12 kg) were retarded (<3<sup>rd</sup> percentiles), but head circumference kept 50<sup>th</sup> percentiles (51 cm) at the time of this report.

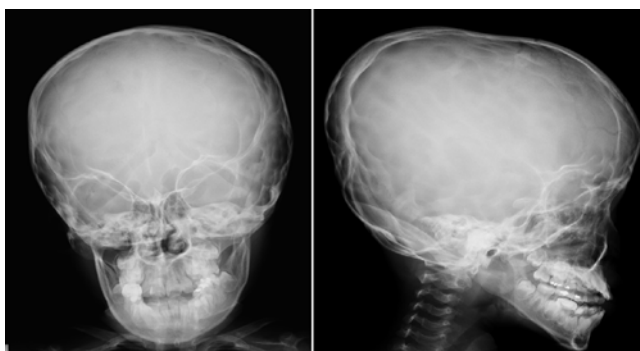
Her developmental milestones were delayed. She could sit alone at 28 months of age and walk alone at 6 years of age. Her development quotient score (by Korean development screening test) of gross motor, fine motor, personal-social, language, and cognitive-adaptation were 10, 100, 50, 12,

접수: 2007년 1월 2일, 승인: 2007년 2월 15일  
책임저자: 김선준, 전북대학교 의과대학 소아과학교실  
Correspondence: Sun Jun Kim, M.D.  
Tel: 063)250-1799 Fax: 063)250-1464  
E-mail: sunjun@chonbuk.ac.kr

and 32, respectively. During the follow-up, short stature, brachydactyly, and a broad forehead became prominent. Simple skull X-ray showed an enlarged skull with increased convolitional marking of skull and hypoplasia of facial bones. A follow-up MRI at 8 years of age revealed a persistent molar tooth sign, and absence of cerebellar vermis, but there was no evidence of hydrocephalus or space-occupying lesions. Skeletal X-ray revealed a generalized decreased bone density, coarse trabeculae, and resorption of the diaphysis on distal phalanges. The middle and proximal phalanges and metacarpal bones were widened and shortened. Bone age was compatible with about 6 years. The levels of 25-OH Vitamin D (80.7 ng/mL), thyroid hormones (T<sub>3</sub> 1.22 ng/mL, free T<sub>4</sub> 20.5 pmol/L, TSH 2.08 mIU/L), and IGF-1 (178 ng/mL) were within normal ranges for her age.



**Fig. 1.** This Brain MRI (T1 weighted image TR 1620.0, TE 3.9) represents complete absence of the cerebellar vermis. Elongation of the superior cerebellar peduncle and midbrain shows molar tooth appearance. Some dilatation and elongation of the 4<sup>th</sup> ventricle appears like bat-wing appearance (molar tooth sign).

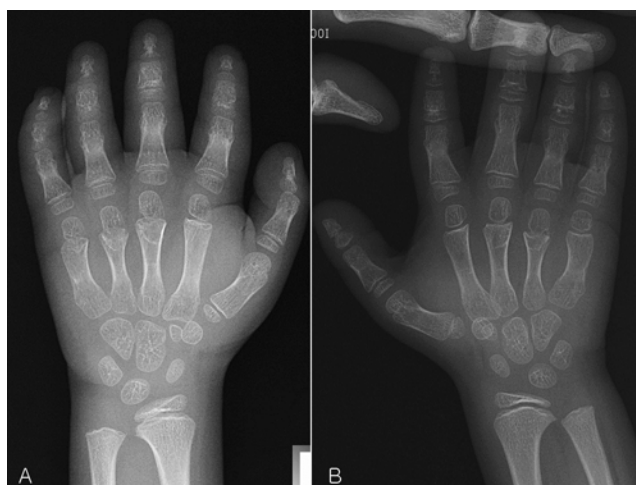

**Fig. 2.** These simple skull x-rays show enlarged skull with increased convolitional markings of skull and hypoplasia of facial bones.

## Discussion

Because of the absence of a biochemical or genetic marker for JS (Joubert Syndrome) and the fact that the phenotype of JS may vary, it is difficult to establish the exact diagnostic boundaries of JS<sup>5</sup>. However, after Maria<sup>6</sup> proposed a series of major criteria, i.e. hypotonia, ataxia, developmental delay, and MRI abnormalities, such characteristic features as ‘molar tooth sign’: elongated and thinning of the pontomesencephalic junction (superior cerebellar peduncles) with deepening of the interpeduncular fossa, the diagnosis of JS is clinically confirmed with these typical clinical and MRI findings<sup>6</sup>.

Several genes involved in JS were reported<sup>7-9</sup>, but Blair et al<sup>5</sup> excluded the candidate genes EN1, EN2, FGF8, and BARHL1, from involvement in JS. Recently, several genes such as AHI1<sup>8</sup> and deletion of NPHP1 gene<sup>9</sup> were suggested for the pathogenetic role of JS. AHI1 is most highly expressed in brain, particularly in neurons that give rise to the crossing axons of the corticospinal tract and superior cerebellar peduncles<sup>8</sup>. Comparative genetic analysis of AHI1 indicates that it has undergone positive evolutionary selection along the human lineage. Therefore, changes in AHI1 may have been important in the evolution of human-specific motor behaviors<sup>8</sup>. However, the genetic abnormality also suggests heterogeneity because of the varieties of JS clinical manifestations<sup>5</sup>. Further studies are needed to verify the



**Fig. 3.** Hand AP view of left (A) and right (B) show generally decreased bone density and coarse trabeculae and resorption of the diaphysis on distal phalanges. The middle and proximal phalanges and metacarpal bones are widened and shortened. Bone age is compatible with about 6 years.

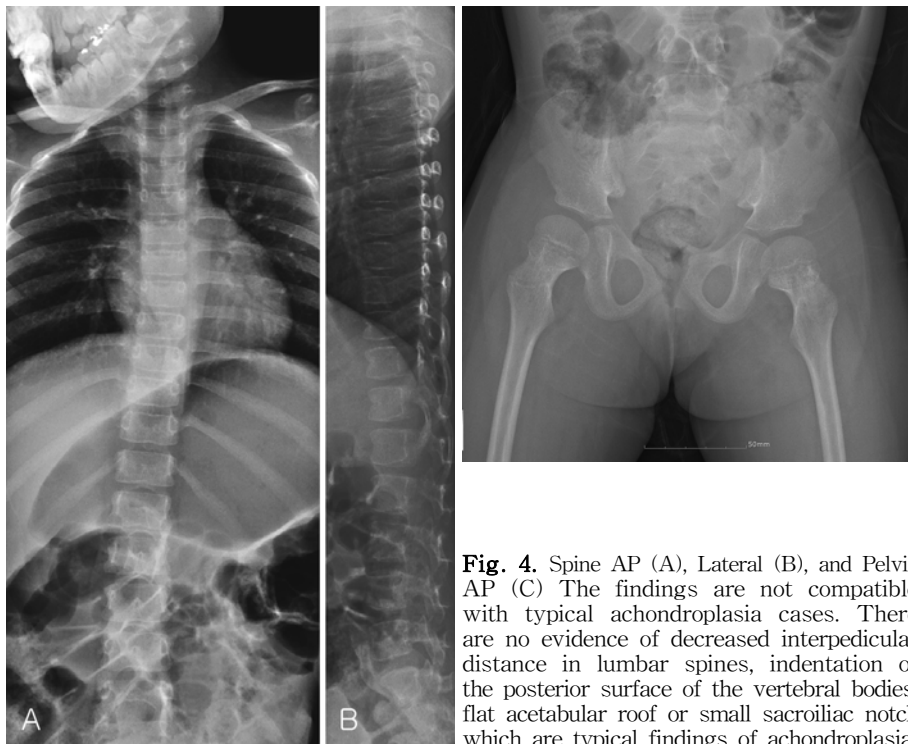
exact genes for pathogenesis of JS.

Recently, several reports<sup>2, 4, 10)</sup> allowed us to understand neurobehavioral development and associated minor manifestations. Supporting clinical features are oculomotor abnormalities, intermittent hyperpnea/hypopnea, abnormal retina, microcephaly, mouth-tongue-facial dyskinesias, ptosis, polydactyly, scoliosis, congenital heart disease, renal cyst, seizure. All patients have aplasia/hypoplasia of cerebellar vermis with molar tooth sign. Other cerebral malformations such as agenesis of corpus callosum and, meningoencephalocele have also been reported<sup>4)</sup>. Most patients could walk between 2 and 10 years of age. Around 15% of JS patients may die due to respiratory problems during early period of life<sup>2)</sup>. Ninety four percent of JS patients were severely impaired according to the Child Development Inventory, with age being positively correlated with the degree of neurobehavioral impairment<sup>10)</sup>.

Our case showed tachypnea/intermittent apnea, marked developmental delay, abnormal eye movements, hypotonia, ataxia, and typical MRI imaging abnormality with molar tooth sign. She underwent corrective operation for right side exotropia and both side ptosis, which were not responsive to anti-cholinesterase. Interestingly, unlike other cases, she showed short stature, brachydactyly, dolichocephaly with

broad forehead. Simple skull X-ray showed an enlarged skull with increased convolitional marking of skull and hypoplasia of facial bones. Skeletal X-ray revealed generally decreased bone density and coarse trabeculae and resorption of the diaphysis on distal phalanges. The middle and proximal phalanges and metacarpal bones were widened and shortened. Bone age was compatible with about 6 years. These findings were suggestive of peripheral dysostosis. Clinically, she looked like an achondroplasia sufferer. However, X-ray findings of spine and pelvis were not compatible with typical achondroplasia or rickets cases. There was no evidence of decreased interpedicular distances in lumbar spines, indentation of the posterior surface of the vertebral bodies, flat acetabular roof or small sacroiliac notch, which are typical findings of achondroplasia. And also there was no evidence of flaring or decreased bone mineral densities. The levels of 25-OH Vitamin D, thyroid hormones, and IGF-1 were within normal ranges.

To our knowledge, peripheral dysostosis has not been reported in children with JS. We report a case of JS with short stature and peripheral dysostosis including phalanges, face, metacarpal and metatarsal bones, which is different from achondroplasia or rickets.



**Fig. 4.** Spine AP (A), Lateral (B), and Pelvis AP (C) The findings are not compatible with typical achondroplasia cases. There are no evidence of decreased interpedicular distance in lumbar spines, indentation of the posterior surface of the vertebral bodies, flat acetabular roof or small sacroiliac notch which are typical findings of achondroplasia.

한글 요약

말초 이골증을 동반한 Joubert Syndrome 1례

전북대학교 의과대학 소아과학교실\*, 임상의학연구소†

김정태\* · 김선준\*<sup>†</sup> · 주찬웅\*<sup>†</sup> · 조수철\*<sup>†</sup> · 이대열\*<sup>†</sup>

본 증례 보고는 작은 키와 단지증을 가진 전형적인 Joubert Syndrome 환자의 10년간 장기 추적 관찰한 결과이다. 환아는 영아기 초기부터 저호흡이 동반된 빈호흡, 울동성 안구 운동, 근 긴장저하를 보였다. 생후 5개월에 Joubert Syndrome의 임상 증상과 전형적 MRI 소견을 보여 진단되었다. 비정상 호흡과 안구 운동은 4세경에 사라졌다. 두위는 정상 범위를 유지하였으나 키와 몸무게는 뚜렷히 정체되었다. 단순 방사선 소견 상 뇌압 상승 소견이 있는 커진 두개골과 안면골의 저형성, 손과 발의 비정상적 연골 형성을 보였다. 본 증례는 말초 이골증이 있는 Joubert Syndrome의 첫번째 보고이다.

References

1) Joubert M, Eisenring JJ, Robb JP, Andermann F. Familial agenesis of the cerebellar vermis: a syndrome of episodic hyperpnea, abnormal eye movements, ataxia, and retardation. *Neurology* 1969;19:813-25.

2) Hodgkins PR, Harris CM, Shawkat FS, Thompson DA,

Chong K, Timms C, et al. Joubert syndrome: long-term follow-up. *Dev Med Child Neurol* 2004;46:694-9.

3) Barreirinho MS, Teixeira J, Moreira NC, Bastos S, Goncalvez S, Barbot MC. Joubert syndrome: report of 12 cases. *Rev Neurol* 2001;32:812-7.

4) Kumandas S, Akcakus M, Coskun A, Gumus H. Joubert syndrome: review and report of seven new cases. *Eur J Neurol* 2004;11:505-10.

5) Blair IP, Gibson RR, Bennett CL, Chance PF. Search for genes involved in Joubert syndrome: evidence that one or more major loci are yet to be identified and exclusion of candidate genes EN1, EN2, FGF8, and BARHL1. *Am J Med Genet* 2002;107:190-6.

6) Maria BL, Boltshauser E, Palmer SC, Tran TX. Clinical features and revised diagnostic criteria in Joubert syndrome. *J Child Neurol* 1999;14:583-90.

7) Gould DB, Walter MA. Mutational analysis of BARHL1 and BARX1 in three new patients with Joubert syndrome. *Am J Med Genet* 2004;131:205-8.

8) Ferland RJ, Eyaid W, Collura RV, Tully LD, Hill RS, Al-Nouri D, et al. Abnormal cerebellar development and axonal decussation due to mutations in AHI1 in Joubert syndrome. *Nat Genet* 2004;36:1008-13.

9) Castori M, Valente EM, Donati MA, Salvi S, Fazzi E, Procopio E, et al. NPHP1 gene deletion is a rare cause of Joubert syndrome related disorders. *J Med Genet* 2005;42:e9.

10) Gitten J, Dede D, Fennell E, Quisling R, Marie BL. Neuro-behavioral development in Joubert syndrome. *J Child Neurol* 1998;13:391-7.