

## Epidural emphysema and pneumoscrotum caused by bronchial foreign body aspiration

Dong-Yeon Kim, M.D., Woo-Yeon Choi, M.D.  
Young-Kuk Cho, M.D. and Jae-Sook Ma, M.D.

Department of Pediatrics, Chonnam National University Medical School, Gwang-ju, Korea

Epidural emphysema and pneumoscrotum with subcutaneous emphysema are rare in a child past the neonatal period. Their most common causes are bronchial asthma and respiratory infection. Here, we report an 18-month-old boy who was presented with severe air leak, consisting of epidural emphysema, pneumoscrotum, subcutaneous emphysema, and pneumomediastinum, complicated by a bronchial foreign body. The air leak was resolved dramatically after removing the foreign body. (**Korean J Pediatr 2007;50:785-788**)

**Key Words :** Foreign body, Emphysema, Epidural space, Pneumoscrotum, Children

### Introduction

Epidural emphysema can occur with spontaneous pneumomediastinum, spontaneous pneumothorax, an asthma attack, coughing, forceful vomiting, strenuous exercise, and trauma<sup>1,2</sup>. And there have been cases of pneumoscrotum associated with colonoscopy, diagnostic peritoneoscopy, percutaneous liver biopsy, pneumothorax, and chest trauma<sup>3,4</sup>. But bronchial foreign body rarely causes epidural emphysema, and there is no report of pneumoscrotum caused by bronchial foreign body. So we report an 18 month-old boy who presented with epidural emphysema and pneumoscrotum caused by a bronchial foreign body.

### Case Report

An 18-month-old boy with dyspnea, cyanosis, and neck swelling was referred to Chonnam National University Hospital. Four days earlier, he abruptly developed nausea, cough, tachypnea, and chest retraction. At a private hospital, he was thought to have bronchial asthma and was treated with an inhaled  $\beta_2$ -agonist, aminophylline, and systemic steroids. However, the next day, neck swelling and

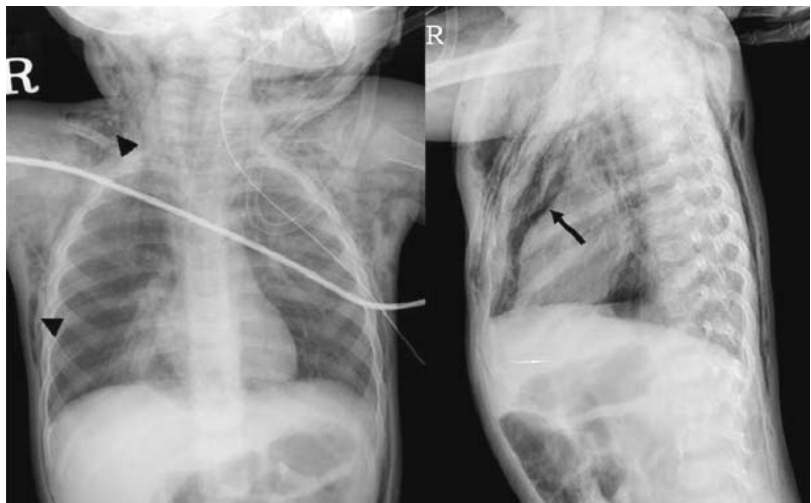subcutaneous emphysema developed, and the dyspnea and chest retraction worsened. Consequently, he was transferred to Chonnam National University Hospital.

He had tachycardia (142 beats/min), hypotension (systolic BP, 80 mmHg), and tachypnea (38 breaths/min) with subcostal chest retraction. Arterial blood gas analysis showed mild hypoxemia ( $\text{PaO}_2=71$  mmHg), and the oxygen saturation was 94%. He had severe swelling of the neck, chest, and scrotum bilaterally (Fig. 1). Palpable crepitus was present, especially in the neck and throughout the pectoral region. However, no wheezing was heard. There was no motor weakness or abnormal deep tendon reflexes. The chest radiograph showed subcutaneous emphysema, pneu-

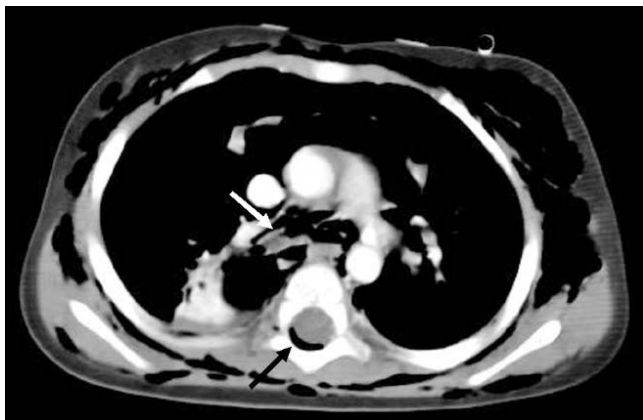


**Fig. 1.** Photograph showing the severe pneumoscrotum.

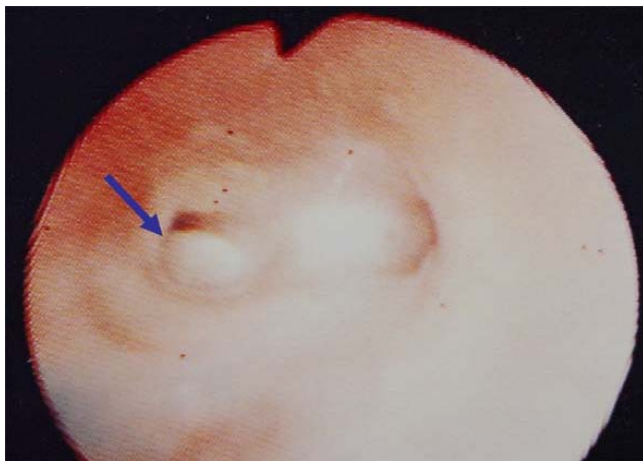
접수 : 2007년 4월 21일, 승인 : 2007년 6월 28일  
책임저자 : 마재숙, 전남대학교 의과대학 소아과학교실  
Correspondence : Jae-Sook Ma, M.D.  
Tel : 062)220-6646 Fax : 062)222-6103  
E-mail : gs00@jnu.co.kr



**Fig. 2.** Chest radiograph showing severe subcutaneous emphysema (arrowheads) and pneumomediastinum (arrows).



**Fig. 3.** Computed tomography showing pneumomediastinum, subcutaneous emphysema, a foreign body in the right main bronchus (white arrow), and epidural emphysema (black arrow).



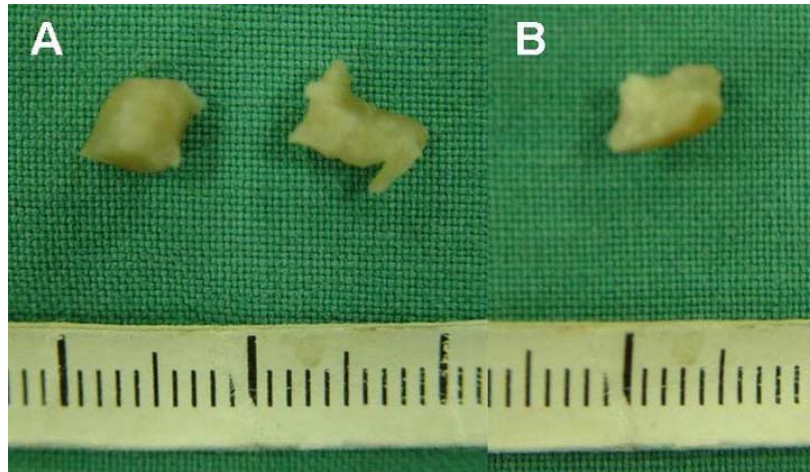
**Fig. 4.** At flexible bronchoscopy, a foreign body (arrow) was seen in the right main bronchus.

momediastinum, and pneumonic infiltration of the right lower lobe (Fig. 2). Computed tomography (CT) showed severe subcutaneous emphysema, pneumomediastinum, epidural emphysema (from C1 to T12), and a foreign body in the right main bronchus (Fig. 3). Testis sonography showed pneumoscutum with intact vascularities. On taking a careful history, the parents remembered that he started coughing abruptly after eating peanuts 4 days earlier. We confirmed the bronchial foreign body using flexible bronchoscopy (Fig. 4), and three fragments of peanut were removed at rigid bronchoscopy, two from the right bronchus and one from the left bronchus (Fig. 5).

After removing the bronchial foreign bodies, his respiratory symptoms and subcutaneous emphysema improved markedly. The pneumoscutum improved gradually. He was discharged after observation for 10 days to monitor signs of respiratory distress, neurologic changes, and pneumoscutum. At follow-up 2 weeks later, the pneumoscutum had resolved completely. The epidural emphysema was extended, but there were no neurologic signs and no compression of the spinal cord. Therefore, CT was not repeated.

## Discussion

In 1973, McSweeney and Stempel<sup>5)</sup> described 41 cases of non-iatrogenic pneumomediastinum in infants and children occurring in association with asthma, respiratory infection, cystic fibrosis, trauma, diabetes mellitus, and leukemia. Of these, asthma was most common cause (33%), followed by



**Fig. 5.** Photograph of the three peanut fragments (3×5, 6×4, and 7×4 mm) that were removed from the right (A) and left (B) main bronchi.

respiratory infection and injury (17% each). There was only one case of a bronchial foreign body. In 2001, Damore and Dayan<sup>6)</sup> retrospectively reviewed the medical causes of pneumomediastinum in children, over 10 years. In their study, the most common causes were asthma exacerbations (59%) and infections (28%). There was just one case associated with a bronchial foreign body. In a large retrospective review of 155 children with bronchial foreign body aspiration, only 10 patients had pneumomediastinum on the initial chest radiograph<sup>7)</sup>. Similarly, a bronchial foreign body is a rare cause of pneumomediastinum.

Epidural emphysema (pneumorachis) and pneumoscutum are even rarer complications of a bronchial foreign body. Epidural emphysema has been reported with spontaneous pneumomediastinum, spontaneous pneumothorax, asthma attacks, coughing, forceful vomiting, strenuous exercise, and trauma<sup>1,2)</sup>. In 2005, Tambe et al.<sup>8)</sup> reported epidural emphysema associated with a bronchial foreign body. In that case, a 1-year-old boy had epidural emphysema at the C6-8 level and subcutaneous emphysema, but he had no pneumomediastinum or pneumothorax. Our case had severe pneumomediastinum, subcutaneous emphysema, and pneumoscutum. The epidural emphysema extended further, from C1 to T12. Nevertheless, there were no neurologic signs and no compression of the spinal cord on CT. Therefore, CT was not repeated. Macklin et al.<sup>9)</sup> suggested that overdistended alveoli rupture into the pulmonary vascular interstitium and that the free air from the torn alveoli dissects proximally along the bronchovascular sheaths toward the mediastinum and pulmonary hilus. Then, this air enters the

visceral space in the neck through the fascial plane over the trachea and esophagus and goes either under the subcutaneous tissues of the neck or into the retroperitoneum. Air enters the epidural space through the fascial planes over the brachial plexus and axillary artery.

There have been cases of pneumoscutum associated with colonoscopy, diagnostic peritoneoscopy, percutaneous liver biopsy, pneumothorax, and chest trauma<sup>3,4)</sup>, but there is no report of pneumoscutum associated with a bronchial foreign body. In our case, the pneumoscutum was so severe that it required 2 weeks to resolve after removing the foreign body.

Although the most common causes of pneumomediastinum and subcutaneous emphysema in children are asthma and respiratory tract infection, it is important to consider the possibility of foreign body aspiration. As in this case, epidural emphysema, pneumoscutum, and pneumomediastinum may be associated with a bronchial foreign body.

## 한글 요약

### 기관지 이물에 의해 발생한 경막외기종 및 고환기종 1례

전남대학교 의과대학 소아과학교실

김동연 · 최우연 · 조영국 · 마재숙

경막외기종은 자발기종격, 자발기흉, 천식 발작, 기침, 심한 구토, 외상 등에 의해 발생할 수 있지만 기관지 이물에 의한 경우는 드물고, 고환기종 역시 대장내시경, 진단적 복강경, 간생검 등에 의해 발생하는 경우가 보고되고 있지만, 기관지 이물에 의

한 경우는 아직까지 국내·외에 보고된 적이 없다. 이에 본 저자들을 기관지 이물에 의해 심한 고환기종 및 경막외기종, 기종격, 기흉이 발생한 18개월된 남아에 대해 보고하는 바이다.

## References

- 1) Aribas OK, Gormus N, Aydogdu Kiresi D. Epidural emphysema associated with primary spontaneous pneumothorax. *Eur J Cardiothorac Surg* 2001;20:645-6.
- 2) Koelliker PD, Brannam LA. Epidural pneumatosis associated with spontaneous pneumomediastinum. *J Emerg Med* 1999;17:247-50.
- 3) Fu KI, Sano Y, Kato S, Fujii T, Sugito M, Ono M. Pneumoscrotum: a rare manifestation of perforation associated with therapeutic colonoscopy. *World J Gastroenterol* 2005;11:5061-3.
- 4) Akabayashi Y, Bush WH Jr. Pneumoscrotum after blunt chest trauma. *J Emerg Med* 1994;12:603-5.
- 5) McSweeney WJ, Stempel DA. Non-iatrogenic pneumomediastinum in infancy and childhood. *Pediatr Radiol* 1973;1:139-44.
- 6) Damore DT, Dayan PS. Medical causes of pneumomediastinum in children. *Clin Pediatr (Phila)* 2001;40:87-91.
- 7) Burton EM, Riggs W, Kaufman RA, Houston CS. Pneumomediastinum caused by foreign body aspiration in children. *Pediatr Radiol* 1989;20:45-7.
- 8) Tambe P, Kasat LS, Tambe AP. Epidural emphysema associated with subcutaneous emphysema following foreign body in the airway. *Pediatr Surg Int* 2005;21:721-2.
- 9) Macklin M, Macklin C. Malignant interstitial emphysema of the lung and mediastinum as an important occult complication in many respiratory diseases and other conditions: an interpretation of the clinical literature in the light of laboratory experiments. *Medicine* 1944;23:281-358.
- 10) Engelhard D, Ornoy A, Deckelbaum RJ. Pneumoscrotum complicating percutaneous liver biopsy. *Gastroenterology* 1981;80:390-2.
- 11) Stavem K, Hoivik B. Pneumoscrotum after air leak from tension pneumothorax. *Tidsskr Nor Laegeforen* 1996;116:1214-5.