

Stent implantation to relieve secondary pulmonary venous stenosis in total anomalous pulmonary venous connection: case report

Youn Ho Shin, M.D., Ki Eun Kim, M.D., Hae Sik Kwon, M.D.*
Byung Won Yoo, M.D.*, and Jae Young Choi, M.D.*

Department of Pediatrics, Pochon CHA University College of Medicine
Division of Pediatric Cardiology, Department of Pediatrics*
Severance Cardiovascular Center, Yonsei University College of Medicine, Seoul, Korea

Pulmonary venous stenosis may be congenital or acquired. Regardless of its origin, the prognosis for patients affected with PVS remains poor. There have been many attempts to palliate PVS with little success. This report describes two patients with PVS which became evident after repair of total anomalous pulmonary venous connection. Intravascular stents were successfully implanted, but progressive restenoses in the stents occurred and eventually both of the patients died. The pertinent literature is reviewed. (*Korean J Pediatr* 2007;50:919-924)

Key Words : Pulmonary veins, Stents

Introduction

Pulmonary venous stenosis (PVS), whether congenital or acquired after surgical repair of a total or partial anomalous pulmonary venous connection¹⁾, is a relatively rare disease. The prognosis is often poor with the development of progressive pulmonary venous congestion followed by pulmonary arterial hypertension and eventual death²⁾. Conventional balloon dilation angioplasty has been attempted with limited success³⁾. Balloon-expandable intravascular stents were then introduced⁴⁾. Compared with balloon dilation alone of pulmonary arterial narrowings, dilation with stent placement gave better results with regard to diameter increase and pressure gradient reduction⁵⁾. Although intravascular stent implantation for the treatment of arterial and venous stenoses in congenital heart disease has been highly successful, its use for congenital or acquired stenoses of the peripheral pulmonary veins has been frequently ineffective⁶⁾. In addition, the stimulating factors responsible for the mechanism underlying restenoses of vessels after stent implantation are not well

recognized^{7,8)}.

We present here two patients with total anomalous pulmonary venous connection (TAPVC) in whom PVS became evident after repair of TAPVC and who died due to progressive pulmonary venous stenoses following intravascular stent implantation.

Case Report

Case 1

A 1.3-year-old male patient had been referred to a tertiary referral cardiac center due to cardiac murmur detected at birth. He was diagnosed as having functional single ventricle with endocardial cushion defect, supracardiac TAPVC, and transposition of great arteries associated with right isomerism. After conventional therapy he underwent bilateral bidirectional cavopulmonary shunt and total correction of TAPVC at 3.9 years of age. Following the operation he had no clinical symptoms or signs. However, one year after the repair progressive stenosis at the right pulmonary venous draining site was noted on echocardiography. Right pulmonary venous balloon angioplasty was performed with little effect. Intravascular stents were then implanted in the right pulmonary vein (RPV)-right atrial (RA) anastomosis site

접수 : 2007년 7월 9일, 승인 : 2007년 8월 1일
책임저자 : 최재영, 연세대학교 의과대학 소아과학교실
Correspondence : Jae Young Choi, M.D.
Tel : 02)2228-8473 Fax : 02)312-9538
E-mail : cjoy0122@yumc.yonsei.ac.kr

because the RPV pressure was too high (mean pressure: 17 mmHg) and discrete severe stenosis was seen on angiography. Following the stent implantation, the RPV pressure declined from 19/15 (mean pressure 17: mmHg) to 9/5 (mean pressure: 7 mmHg) with clinical improvement (Fig. 1). At 5.5 years of age, he presented with facial edema and abdominal pain which persisted for 4 days. On physical examination, his blood pressure was 110/70 mmHg (75-90 percentiles), weight 16.1 kg (25-50 percentiles) and height 111 cm (25-50 percentiles). His pulse rate was 95/min, respiratory rate 22/min and body temperature 36.7°C. He was ill appearing with facial edema and mild perioral cyanosis and a grade 3/6 systolic murmur was heard on the left upper chest. Laboratory studies revealed hemoglobin of 15.2 g/dL with hematocrit of 53%, WBC of 12,990/mm³ (polymorphonuclear cell 46%, lymphocyte 43%, and monocyte 5%), platelet of 466,000/mm³, and oxygen saturation of 78.4%. Chest radiography showed cardiac enlargement and increased pulmonary vascular markings, electrocardiography showed right axis deviation and sinus tachycardia, and echocardiography showed mild restenosis of the RPV-RA communication. Heart electron beam tomograms (EBT) showed no evidence of any stenosis at the junction of superior vena cava and right and left pulmonary arteries. However, abundant mediastinal collateral veins were noted, mainly through azygos, hemiazygos and internal mammary veins. There was still mild degree of stenosis in the stent site (residual diameter: 3 mm). There were no remarkable

size changes in intrapericardial pulmonary arteries. His clinical symptoms improved with medications, such as aspirin, diuretics, digoxin, and angiotensin-converting enzyme inhibitors. He was discharged upon planning another elective surgery or redilation of stent obstruction. Two months after discharge, the patient was, well and further treatment was delayed due to his parents request. Six months following the procedure, he suddenly collapsed showing circulation dysfunction and died.

Case 2

A 10 day-old girl had been referred to a tertiary referral cardiac center due to cyanosis and severe tachypnea detected at birth. She had been diagnosed as having atrial septal defect, patent ductus arteriosus, and obstructive TAPVC which drained to coronary sinus. She had subsequently undergone total correction of TAPVC at 1 month of age. On follow-up echocardiography, stenoses of each pulmonary vein to left atrial communication were noted with resultant pulmonary hypertension, severe tricuspid regurgitation and RV dysfunction (Peak velocity at pulmonary orifice: 2.2-2.4 m/sec). She showed progressive respiratory difficulty with poor weight gain. Reoperation was performed at 9 months of age to palliate the stenoses with temporary improvement. Restenoses occurred within a few months. At 1 year of age, she was readmitted due to shortness of breath. Echocardiography showed increased peak velocity at each left pulmonary venous orifice (2.1-2.3 m/sec). Trido repair (patch en-

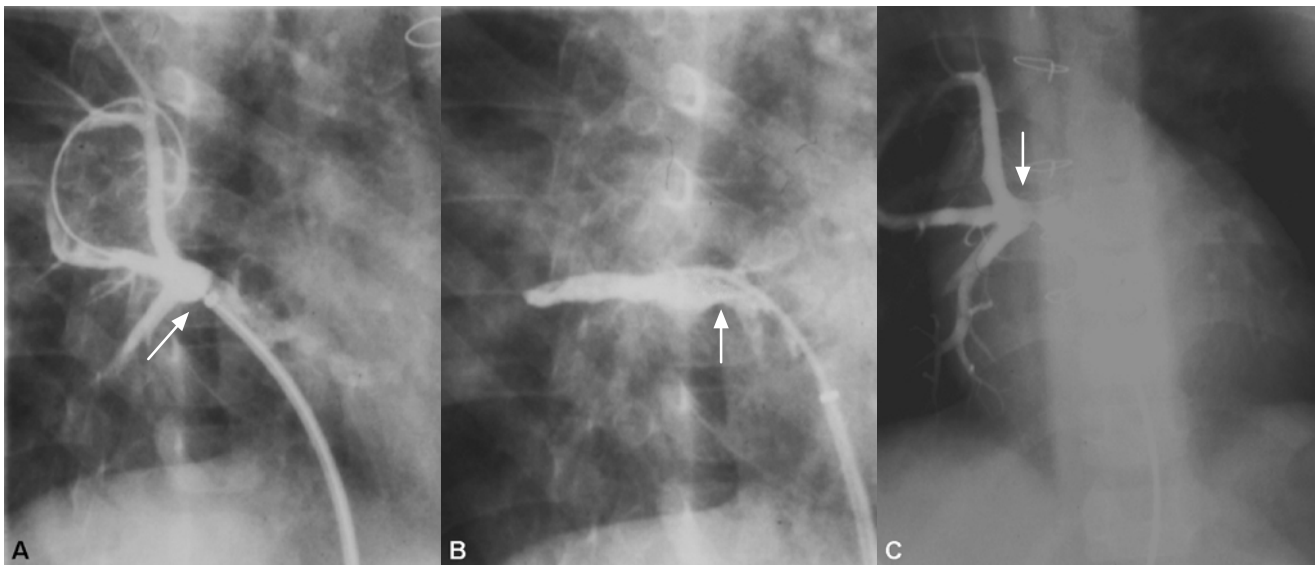


Fig. 1. Pulmonary angiograms of case 1 is shown. Initial discrete stenosis (A) is relieved by stent implantation (B). Six months after stent implantation restenosis occurred in the stent which extended proximally (C).

largement of left pulmonary veins) was performed and her clinical symptoms improved with a decline of the peak velocity at PV orifice to around 1.5 m/sec. However, PVS extended into the proximal pulmonary parenchyma. For the following 2 months, with a peak velocity in pulmonary venous orifices around 2.2 m/sec, three intravascular stents were implanted in the stenoses of right lower PV, and left upper and lower PVs (Fig. 2). Echocardiography performed shortly after the intravascular stents implantation demonstrated decreased pulmonary vascular hypertension with clinical improvement (Peak velocity on each pulmonary venous orifices: 1.0 m/sec). Upon the discharge, her clinical symptoms had improved significantly. Several months following the stents implantation, she presented with fever and cough. On physical examination, her blood pressure was 95/70 mmHg (50-75 percentiles), weight 6.5 kg (25-50 percentiles) and height 72 cm (25-50 percentiles). Her pulse rate

was 100/min, respiratory rate 25/min and body temperature 38.6°C. She was ill appearing with mild perioral cyanosis without cardiac murmur. Laboratory studies revealed hemoglobin of 11.5 g/dL with hematocrit of 33.5%, WBC of 12,000/mm³ (polymorphonuclear cell 43%, lymphocyte 46%, and monocyte 7%), platelet of 420,000/mm³, and oxygen saturation of 84.4%. Chest radiography showed cardiac enlargement and increased pulmonary vascular markings, electrocardiogram showed right axis deviation and right ventricular hypertrophy and echocardiogram showed pulmonary venous restenoses on the intravascular stents implantation sites and severe pulmonary arterial hypertension. Cardiac MRI showed diffuse connective tissue formation in the posterior to both atria which extended to pulmonary parenchyma. Heart EBT showed marked dilatation of right atrium and right ventricle, severe degree of enlargement of pulmonary artery due to pulmonary arterial hypertension, and extensive soft tissue

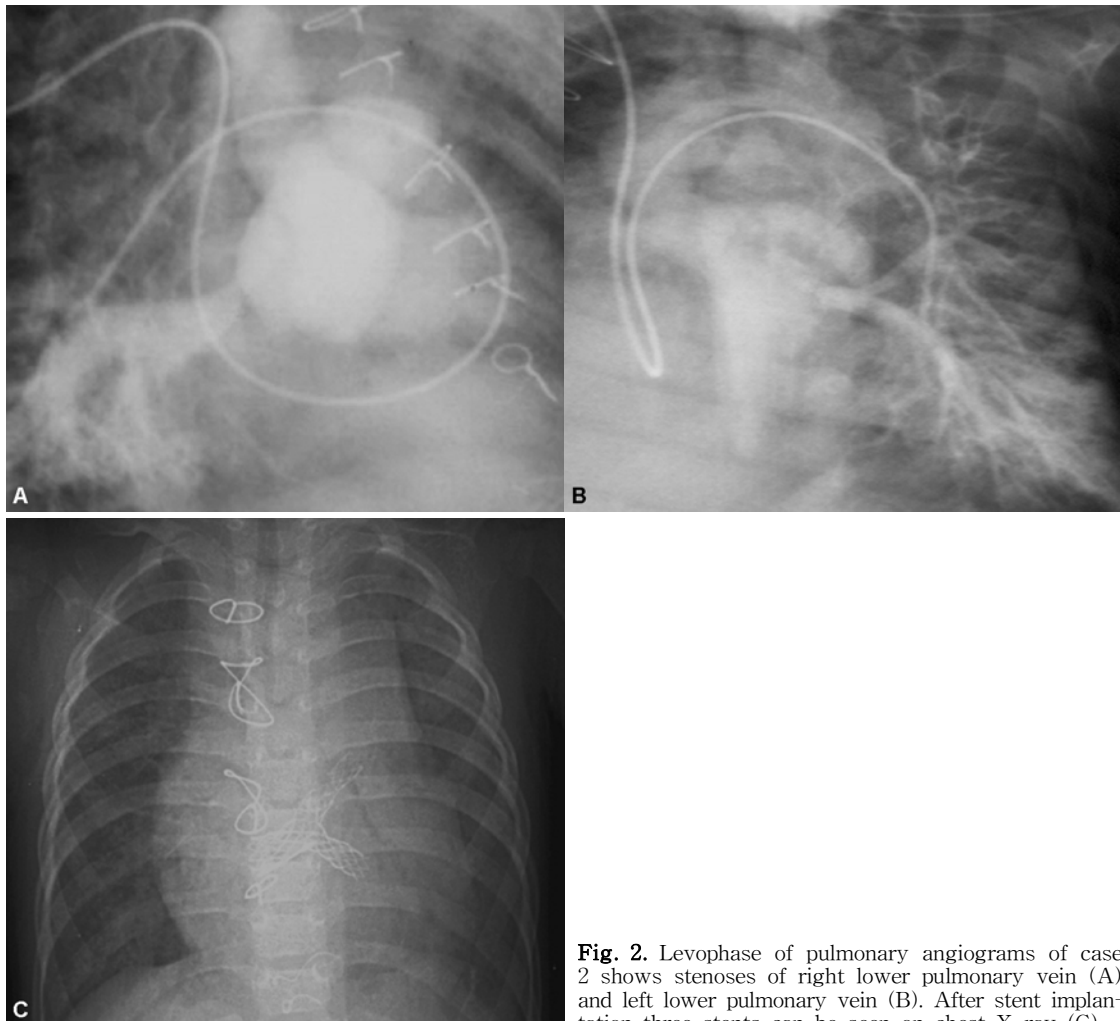


Fig. 2. Levophase of pulmonary angiograms of case 2 shows stenoses of right lower pulmonary vein (A) and left lower pulmonary vein (B). After stent implantation three stents can be seen on chest X-ray (C).

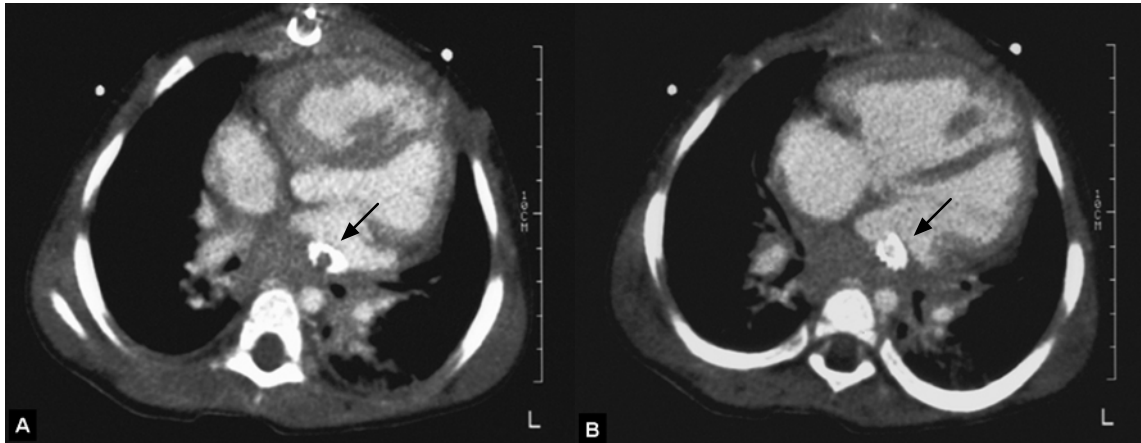


Fig. 3. Several months following stents implantation the patient s (case 2) clinical symptoms deteriorated. Electron beam tomogram shows stenosis of the right lower pulmonary vein due to neointimal proliferation inside the stent (A) and patency within the stent at the left lower pulmonary vein, supported by the presence of the same density of contrast inside the stent. (B) Massive fibrotic tissue around the stents also can be observed.

formation posterior to both atria and also to the right paratracheal area (Fig. 3). Despite all medical treatments, severe pulmonary vascular hypertension increased gradually, clinical signs deteriorated and she died 7 months following the stent implantation.

Discussion

Congenital or acquired stenosis of the pulmonary veins is a rare but frequently lethal cardiac abnormality⁹⁾. If the post-operative restenosis is related to surgical technique, it can be corrected by reoperation adopting new surgical techniques¹⁰⁻¹³⁾. If the stenosis is caused by tissue ingrowths often accompanied by extension to lung parenchyma, surgical correction is not an option. The results for conventional balloon angioplasty have been disappointing mainly due to recoil of the tissues³⁾. Intravascular stents have been introduced to support vessel walls after dilation in the coronary and peripheral circulation in adults in an attempt to inhibit the natural recoil of the tissues^{14, 15)}. In a study by O'Laughlin et al¹⁶⁾, 45 stents were placed in 30 patients, including 23 patients with branch pulmonary artery stenosis and 1 patient with PVS, who had areas of stenosis that were difficult to approach surgically. They concluded that balloon expandable stents are especially useful for patients with areas of stenosis that are difficult to approach surgically¹⁶⁾. However, stent-related early restenosis was noted in all studies, especially with PVS. Stent-related restenosis is of critical value in terms of hemodynamics when small-diameter stents were inserted in infants with pulmonary

artery and vein stenoses. Even after implantation of stent size as large as 16 mm stent-related pulmonary arterial obstruction developed⁶⁾. Coles et al⁶⁾ reported that in four of the five patients with PV stent implantation intractable obstruction developed, resulting in death in all three patients who had bilateral PV stent implantation. This result is compatible with another study by Mendelsohn et al¹⁷⁾ where in all 3 patients with pulmonary vein stent implantations pulmonary vein restenosis occurred. They postulated that the combination of small stent and vessel size, low velocity venous flow, and/or the underlying venous disease process may predispose to the early restenosis in these patients^{17, 18)}. Histological findings show that variable manifestation of neointimal proliferation leads to occlusion of the lumen of one or more of the pulmonary veins¹⁹⁻²²⁾. The precise stimuli that cause cellular proliferation and synthesis of intracellular matrix in the presence of metallic stents, as well as the potential for remodeling and regression, remain unknown^{23, 24)}. Recently, cutting balloon angioplasty (CBA) has been introduced for the treatment of stenosis which does not respond to balloon expandable endovascular stents²⁵⁾. With this technique, when the angioplasty balloon is inflated, three or four microblades incise the intima and media of the vessel. The technique was used successfully to treat coronary stenoses resistant to dilation with high-pressure balloons²⁶⁾ and resistant pulmonary artery stenoses²⁷⁾. However, CBA also failed to obtain promising long-term results for the treatment of PVS. Nevertheless, there are some reports demonstrating that CBA could be an alternative therapy for a selected group of patients²⁸⁾. Recently, there has been a

report suggesting that a combined approach of using cutting balloons followed by insertion of drug-eluting stents may, in the future, provide the best treatment for PVS²⁾.

These two cases showed disappointing results, consistent with previous studies. We speculate that more research and experience would be necessary to have long-lasting stents patency for PVS.

한 글 요약

총 폐정맥 환류 이상 완전교정술 후 이차적으로 발생한 폐정맥 협착에서 스텐트 삽입술 2례

포천중문 의과대학교 소아과학교실
연세대학교 의과대학 소아과학교실*
심장혈관병원 소아심장과

신운호 · 김기은 · 권혜식* · 유병원* · 최재영*

폐정맥 협착은 선천적 또는 총 폐정맥 환류 이상 완전교정술 후에 이차적으로 발생한다. 선천적, 후천적 폐정맥 협착은 많은 연구에도 불구하고 예후가 대단히 불량한 것으로 알려져 있다. 저자들은 총 폐정맥 환류 이상 완전교정술 후에 이차적으로 발생한 폐정맥 협착 환아 2명에게 풍선 혈관 성형술 후 협착부가 다시 좁아져서 스텐트 삽입술을 시행하여 증상이 호전되다가 다시 진행성 협착이 발생하여 사망한 2례를 보고하는 바이다.

References

- 1) van Son JA, Danielson GK, Puga FJ, Edwards WD, Driscoll DJ. Repair of congenital and acquired pulmonary vein stenosis. *Ann Thorac Surg* 1995;60:144-50.
- 2) Seale AN, Daubeney PE, Magee AG, Rigby ML. Pulmonary vein stenosis: initial experience with cutting balloon angioplasty. *Heart* 2006;92:815-20.
- 3) Lock JE, Bass JL, Castaneda-Zuniga W, Fuhrman BP, Rashkind WJ, Lucas RV, Jr. Dilation angioplasty of congenital or operative narrowings of venous channels. *Circulation* 1984;70:457-64.
- 4) Mullins CE, O'Laughlin MP, Vick GW, 3rd, Mayer DC, Myers TJ, Kearney DL, et al. Implantation of balloon-expandable intravascular grafts by catheterization in pulmonary arteries and systemic veins. *Circulation* 1988;77:188-99.
- 5) Rothman A, Perry SB, Keane JF, Lock JE. Early results and follow-up of balloon angioplasty for branch pulmonary artery stenoses. *J Am Coll Cardiol* 1990;15:1109-17.
- 6) Coles JG, Yemets I, Najm HK, Lukanich JM, Perron J, Wilson GJ, et al. Experience with repair of congenital heart defects using adjunctive endovascular devices. *J Thorac Cardiovasc Surg* 1995;110:1513-9; discussion 9-20.
- 7) Gordon PC, Gibson CM, Cohen DJ, Carozza JP, Kuntz RE, Baim DS. Mechanisms of restenosis and redilation within coronary stents--quantitative angiographic assessment. *J Am Coll Cardiol* 1993;21:1166-74.
- 8) Palmaz JC. Intravascular stents: tissue-stent interactions and design considerations. *AJR Am J Roentgenol* 1993;160:613-8.
- 9) Driscoll DJ, Hesslein PS, Mullins CE. Congenital stenosis of individual pulmonary veins: clinical spectrum and unsuccessful treatment by transvenous balloon dilation. *Am J Cardiol* 1982;49:1767-72.
- 10) Caldarone CA, Najm HK, Kadletz M, Smallhorn JF, Freedom RM, Williams WG, et al. Relentless pulmonary vein stenosis after repair of total anomalous pulmonary venous drainage. *Ann Thorac Surg* 1998;66:1514-20.
- 11) Najm HK, Caldarone CA, Smallhorn J, Coles JG. A sutureless technique for the relief of pulmonary vein stenosis with the use of in situ pericardium. *J Thorac Cardiovasc Surg* 1998;115:468-70.
- 12) Lacour-Gayet F, Zoghbi J, Serraf AE, Belli E, Piot D, Rey C, et al. Surgical management of progressive pulmonary venous obstruction after repair of total anomalous pulmonary venous connection. *J Thorac Cardiovasc Surg* 1999;117:679-87.
- 13) Hyde JA, Stumper O, Barth MJ, Wright JG, Silove ED, de Giovanni JV, et al. Total anomalous pulmonary venous connection: outcome of surgical correction and management of recurrent venous obstruction. *Eur J Cardiothorac Surg* 1999;15:735-40; discussion 40-1.
- 14) Levine MJ, Leonard BM, Burke JA, Nash ID, Safian RD, Diver DJ, et al. Clinical and angiographic results of balloon-expandable intracoronary stents in right coronary artery stenoses. *J Am Coll Cardiol* 1990;16:332-9.
- 15) Palmaz JC, Richter GM, Noeldge G, Schatz RA, Robison PD, Gardiner GA, Jr., et al. Intraluminal stents in atherosclerotic iliac artery stenosis: preliminary report of a multicenter study. *Radiology* 1988;168:727-31.
- 16) O'Laughlin MP, Perry SB, Lock JE, Mullins CE. Use of endovascular stents in congenital heart disease. *Circulation* 1991;83:1923-39.
- 17) Mendelsohn AM, Bove EL, Lupinetti FM, Crowley DC, Lloyd TR, Fedderly RT, et al. Intraoperative and percutaneous stenting of congenital pulmonary artery and vein stenosis. *Circulation* 1993;88:II210-7.
- 18) Nakib A, Moller JH, Kanjuh VI, Edwards JE. Anomalies of the pulmonary veins. *Am J Cardiol* 1967;20:77-90.
- 19) Bini RM, Cleveland DC, Ceballos R, Barger LM, Jr., Pacifico AD, Kirklin JW. Congenital pulmonary vein stenosis. *Am J Cardiol* 1984;54:369-75.
- 20) Haworth SG. Total anomalous pulmonary venous return. Prenatal damage to pulmonary vascular bed and extrapulmonary veins. *Br Heart J* 1982;48:513-24.
- 21) Shone JD, Amplatz K, Anderson RC, Adams P, Jr., Edwards JE. Congenital stenosis of individual pulmonary veins. *Circulation* 1962;26:574-81.
- 22) Edwards JE. Congenital stenosis of pulmonary veins. Pathologic and developmental considerations. *Lab Invest* 1960;9:46-66.
- 23) Roubin GS, King SB, 3rd, Douglas JS, Jr., Lembo NJ, Robinson KA. Intracoronary stenting during percutaneous transluminal coronary angioplasty. *Circulation* 1990;81:IV92-

- 100.
- 24) White CJ, Ramee SR, Banks AK, Mesa JE, Chokshi S, Isner JM. A new balloon-expandable tantalum coil stent: angiographic patency and histologic findings in an atherogenic swine model. *J Am Coll Cardiol* 1992;19:870-6.
- 25) Suda K, Matsumura M, Hayashi H, Nishimura K. Comparison of efficacy of medium-sized cutting balloons versus standard balloons for dilation of peripheral pulmonary stenosis. *Am J Cardiol* 2006;97:1060-3.
- 26) Unterberg C, Buchwald AB, Barath P, Schmidt T, Kreuzer H, Wiegand V. Cutting balloon coronary angioplasty--initial clinical experience. *Clin Cardiol* 1993;16:660-4.
- 27) Sugiyama H, Veldtman GR, Norgard G, Lee KJ, Chaturvedi R, Benson LN. Bladed balloon angioplasty for peripheral pulmonary artery stenosis. *Catheter Cardiovasc Interv* 2004; 62:71-7.
- 28) Rotzsch C, Wiener M, Henning B, Daehnert I. Stents for treatment of obstructed pulmonary venous return[abstract]. *Catheter Cardiovasc Interv* 2004;63:125.