

유방에 생긴 과립세포종양의 세포 소견

-1예 보고-

한국원자력의학원 원자력병원 병리과, 일반외과¹

정수영 · 노우철¹ · 진민선 · 이승숙 · 고재수

Fine Needle Aspiration Cytology of Granular Cell Tumor in Breast -A Case Report-

Soo-Young Chung, M.D., Wo Chul Noh, M.D.,¹
Min Sun Jin M.D., Seung-Sook Lee M.D., and
Jae Soo Koh M.D.

Department of Pathology, General Surgery,¹ Korea
Cancer Center Hospital, KIRAMS, Seoul, Korea

논문접수 : 2007 년 6월 26일
게재승인 : 2007 년 9월 5일

책임저자 : 고재수
주 소 : (139-706) 서울시 노원구 공릉동 215-4
한국원자력의학원 원자력병원 병리과
전 화 : 02-970-2545
팩 스 : 02-970-2430
E-mail address : jskoh@kcch.re.kr

Granular cell tumor (GCT) of the breast is a rare clinical entity, and is believed to be of schwannian origin and to follow a benign clinical course. A 50-year-old woman presented with a slowly growing mass in the right breast. Fine needle aspiration cytology revealed a cellular smear containing isolated or clustered cells showing round to oval nuclei with abundant oncocyctic granular cytoplasm. Nuclei showed a fine granular chromatin pattern and occasional small single nucleoli. Cell boundaries were poorly defined, and naked nuclei were frequently found. Histologically, the tumor showed features of typical GCT, and immunohistochemical staining findings strongly supported the diagnosis. The present study demonstrates that GCT of the breast can mimic malignant lesions of breast both clinically and radiologically. The recognition of its cytologic features and suspicion of this lesion would undoubtedly aid the correct diagnosis of mammary GCT.

(*Korean J Cytopathol* 2007;8(2):157-160)

Key Words : Granular cell tumor, Breast, Fine needle aspiration cytology

INTRODUCTION

Granular cell tumor (GCT) is an uncommon neoplasm and was first described in 1926 as myoblastic myomata by Abrikossoff.¹ It was later reported that it can occur anywhere in the body and suggested that it is of schwannian origin.^{2,3} GCT generally follows a benign clinical course, but can be clinically misdiagnosed as breast cancer, because patients present with an irregular marginated firm to hard painless mass, which can closely simulate a malignant lesion.²

However, GCT usually has a distinctive cytologic

appearance, and therefore fine needle aspiration cytology (FNAC) has been suggested as an effective and accurate diagnostic tool.^{4,6} In a survey of the literature, we found that the radiologic features of mammary GCT and FNAC findings of soft tissue GCT have been previously documented in Korea, but we were unable to find a report containing the FNAC findings of mammary GCT.⁷⁻⁹ Thus, here, we describe the FNAC findings of GCT in the breast, and discuss the differential diagnosis of this benign tumor.

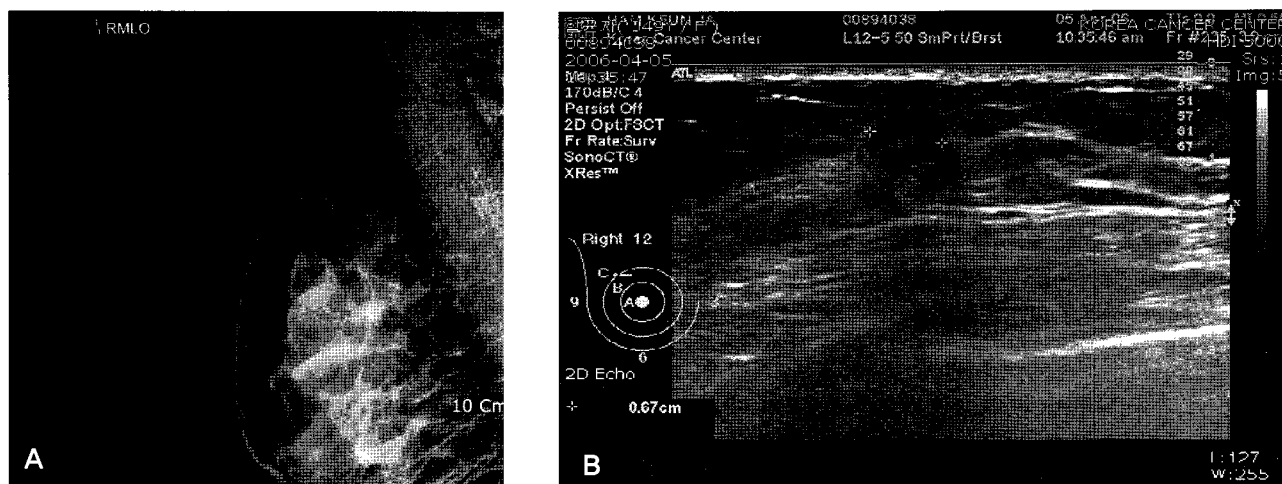


Fig. 1. (A) Mammography of right breast revealed 7mm nodule with speculated margin in 11 o'clock area (white arrow). (B) Ultrasonography demonstrated a 7mm-sized well defined, heterogeneous echoic nodule in the outer upper quadrant of right breast.

CASE

A 50-year-old woman presented with a slowly growing painless mass in her right breast. A physical examination revealed a firm, unmovable, small palpable mass in the outer upper quadrant of the right breast. No axillary lymphadenopathy was observed. Mammography and ultrasonography revealed a 7mm sized well-defined heterogeneous echoic nodule (Fig. 1 A and B). There was no associated calcification. Moreover, the mammographic and ultrasonographic appearances of the lesion were highly suggestive of an invasive carcinoma.

Cytological Findings

Smears were moderately cellular and contained small numbers of isolated cells and cellular syncytial clusters (Fig. 2A). Moreover, backgrounds were clear without necrotic materials or blood. These cells had round to oval nuclei, abundant oncocyctic granular cytoplasm, and low nucleocytoplasmic ratio. Nuclei were two to three times larger than red blood cells with evenly distributed chromatin and occasional small nucleoli. Cytoplasmic borders were poorly defined, numerous fine, evenly distributed, granular materials were observed in backgrounds (Fig. 2B), and naked nuclei

were frequently seen. Non-apocrine ductal cells and myoepithelial cells were not easily identified. The cells were interpreted as benign apocrine cells, and the initial diagnosis was of fibrocystic change accompanied by apocrine metaplasia.

Histological Findings

Excisional biopsy was performed for a definitive diagnosis due to the diagnostic radiologic and cytologic discrepancies. The cut-surface of the tumor showed a poorly circumscribed, grayish white solid lesion, measuring 0.7×0.6 cm. Microscopically the tumor showed an infiltrative growth pattern, and entrapped benign ducts and fat tissue (Fig. 2C). In addition, cellular sheets of round to polygonal cells with abundant finely eosinophilic granular cytoplasm were observed. Nuclei were round to oval and finely granular with occasional small nucleoli (Fig. 2D). However, nuclear atypia, mitosis, and necrosis were not observed. Cytoplasmic granules were positive to periodic acid-Schiff reagent, and tumor cells were strongly positive for S-100 protein, weakly positive for CD68, and negative for cytokeratin, vimentin, HMB45, smooth muscle actin (SMA), desmin, and epithelial membrane antigen (EMA). The histologic diagnosis was of GCT arising in the breast.

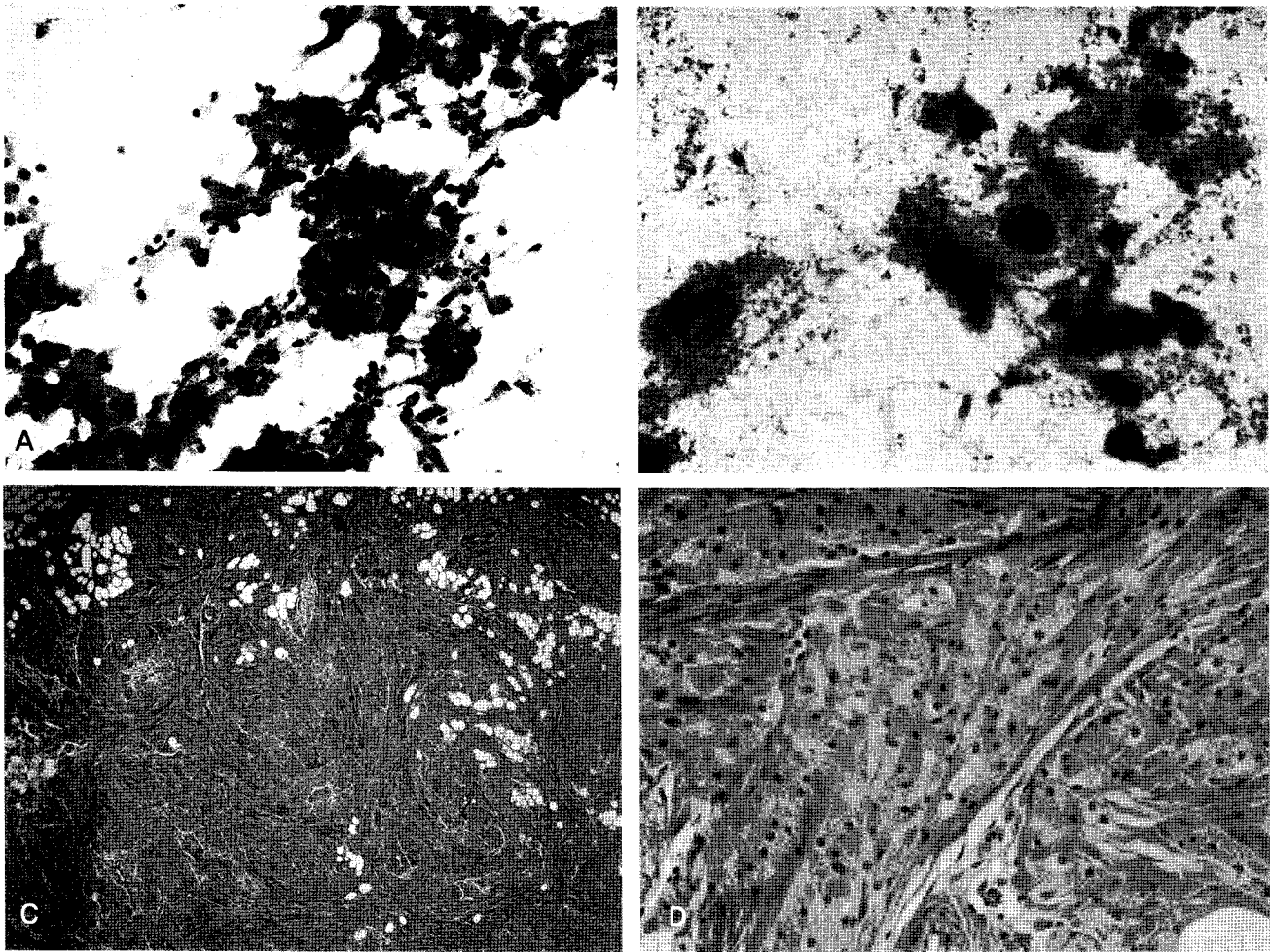


Fig. 2. (A) The cytologic smears are composed of a small number of scattered isolated cells and clusters of epithelial sheets, (Papanicolaou). (B) The tumor cells show round to oval nuclei with an abundant granular cytoplasm. Numerous fine granular materials are evenly distributed on the background. Nuclei are finely granular with small nucleoli, (Papanicolaou). (C) Histologic section shows infiltrative solid lesion with entrapped adipose tissue and ducts, (H&E). (D) The tumor cells show abundant eosinophilic finely granular cytoplasm, low nucleocytoplasmic ratio, and monotonous round to oval nuclei, (H&E).

DISCUSSION

GCT may occur in a variety of visceral and cutaneous locations.³ However, few reports describe the FNAC features of GCT arising in the breast.^{4,6,10-13} The cytological findings of this tumor include sheets of cells with abundant eosinophilic, finely granular cytoplasm, eccentrically located oval to round nuclei with fine nuclear chromatin, and occasional small inconspicuous nucleoli. Mild nuclear atypism can be present and naked nuclei are frequently found, and cytoplasmic granular materials are occasionally smeared in the background.

Various benign and malignant findings of breast lesions, such as, fibrocystic change with apocrine metaplasia, fat necrosis, and ductal carcinoma with apocrine metaplasia are considered in the differential diagnosis. Apocrine cells in fibrocystic change with apocrine metaplasia tend to have well-defined cytoplasmic borders in contrast to the indistinct cell borders of GCT. Moreover, cytoplasmic granularity is more distinct in GCT. Usually benign apocrine cells derived from cyst-lining cells are smeared in two dimensional sheets (based on personal experience) and are accompanied by myoepithelial cells, in contrast to the three dimensional syncytial cell clusters encountered in GCT.

Moreover, histiocytes are observed in regions of fat necrosis, in cystic fluid, and in chronic inflammatory conditions, which resembles that observed in GCT. However, histiocytes often contain indented nuclei and the cytoplasm tends to be foamy rather than granular and may contain pigment or cell debris.¹⁰ Malignant breast lesions accompanying apocrine change, such as, ductal carcinomas with apocrine change and pure apocrine carcinomas should be distinguished from granular cell tumors, and careful examination of nuclear features could identify these malignant lesions and avoid overdiagnosis. The cytologic features of most GCT cases include benign morphologic characteristics, such as, fine chromatin, smooth nuclear membranes, and low nucleocytoplasmic ratios.^{6,10,12} Although the cytologic features of soft tissue GCT have been well described, and the cytologic features of GCT occurring in breast are resemble those of soft tissue GCT, the lists of differential diagnosis of GCT in the breast differ from those of soft tissue GCT such as alveolar soft tissue sarcoma, rhabdomyosarcom, and fat necrosis.^{8,9}

In the described case, clinical and radiologic features suggested malignancy, but aspirate findings were of benign apocrine metaplasia in a background of fibrocystic change. This discrepancy between clinical and cytologic diagnosis is attributed to the mimicking of malignant lesions (both clinically and radiologically) and of an apocrine cell cytology due to the presence of eosinophilic cytoplasmic granules in GCT.^{2,10} However, suspicion of this entity should have resulted from the lack of naked myoepithelial cells and three dimensional cellular clusters in aspirate. In our literature review, some cases were not correctly diagnosed preoperatively as granular cell tumour,^{3,10,13} although in a small number of reported cases this diagnosis was correctly suggested by FNAC.^{5,6,12,14}

In conclusion, we emphasize that pathologists should be aware that GCT may occur in the breast, and that this diagnosis should be considered when an aspirate containing cells with abundant granular cytoplasm and benign nuclear features is encountered despite pre-

operative clinical and radiological features indicative of carcinoma.

REFERENCES

1. Abrikossoff A. Uber myome, ausgehend von der quergestreiften, willkurlichen muskulatur. *Virchows Arch Pathol Anat* 1926;260:215-33.
2. Adeniran A, Al-Ahmadie H, Mahoney MC, Robinson-Smith TM. Granular cell tumor of the breast: a series of 17 cases and review of the literature. *Breast J* 2004;10:528-31.
3. Lack EE, Worsham GF, Callihan MD, et al. Granular cell tumor: a clinicopathologic study of 110 patients. *J Surg Oncol* 1980;13:301-16.
4. Akatsu T, Kobayashi H, Uematsu S, et al. Granular cell tumor of the breast preoperatively diagnosed by fine-needle aspiration cytology: report of a case. *Surg Today* 2004;34:760-3.
5. Liu K, Madden JF, Olatidoye BA, Dodd LG. Features of benign granular cell tumor on fine needle aspiration. *Acta Cytol* 1999;43:552-7.
6. Hahn HJ, Iglesias J, Flenker H, Kreuzer G. Granular cell tumor in differential diagnosis of tumors of the breast. The role of fine needle aspiration cytology. *Pathol Res Pract* 1992;188:1091-7.
7. Kim EK, Lee MK, Oh KK. Granular cell tumor of the breast. *Yonsei Med J* 2000;41:673-5.
8. Kim SY, Hwang JS, Kwon HP, Yang JH, Roh JS, Yang WS. Fine needle aspiration cytology of granular cell tumor of the lower leg: report of a case. *Korean J Cytopathol* 2004;15:126-30.
9. Oh MH, Khang SK. Fine needle aspiration cytology of granular cell tumor of the thigh. A case report. *Korean J Cytopathol* 1993;4:66-9.
10. McCluggage WG, Sloan S, Kenny BD, Alderdice JM, Kirk SJ, Anderson NH. Fine needle aspiration cytology (FNAC) of mammary granular cell tumour. a report of three cases. *Cytopathology* 1999;10:383-9.
11. Gibbons D, Leitch M, Coscia J, et al. Fine needle aspiration cytology and histologic findings of granular cell tumor of the breast: review of 19 cases with clinical/radiologic correlation. *Breast J* 2000;6:27-30.
12. Jayaram G, Hoon PB, Har YC. Granular cell tumor of breast: diagnosis by fine needle aspiration cytology. *Acta Cytol* 2006;50:593-5.
13. Pieterse AS, Mahar A, Orell S. Granular cell tumour: a pitfall in FNA cytology of breast lesions. *Pathology* 2004;36:58-62.
14. Placidi A, Aversa A, Foggi CM, Foggi P, Ricci G, Salvatori V. Granular cell tumour of breast in a young man preoperatively diagnosed by fine needle aspiration (FNA) Cytology. *Cytopathology* 1995;6:343-8.