

## 초음파 유도 갑상샘 세침흡인 세포검사서 SurePath™ 액상세포검사의 유용성; 고식적 도말검사와 SurePath™ 액상세포검사와의 비교

성균관의대 강북삼성병원, 분당제생병원<sup>1</sup> 병리과

김 동 훈 · 김 민 경 · 채 승 완 · 이 경 분 · 한 은 미<sup>1</sup> · 강 성 희 · 손 진 희

### The Usefulness of SurePath™ Liquid-Based Smear in Sono- Guided Thyroid Fine Needle Aspiration; a Comparison of a Conventional Smear and SurePath™ Liquid-Based Cytology

Dong Hoon Kim, M.D., Min Kyung Kim, M.D.,  
Seoung Wan Chae, M.D., Kyoung Bun Lee, M.D.,  
Eun Mee Han, M.D.,<sup>1</sup> Sung Hee Kang, M.D., and  
Jin Hee Sohn, M.D.

Department of Pathology, Kangbuk Samsung  
Hospital, Sungkyunkwan University School of  
Medicine, Seoul and Pundang Jesaeng General  
Hospital,<sup>1</sup> Sungnam, Gyeonggi-do, Korea

논문접수 : 2007 년 5월 2일  
게재승인 : 2007 년 9월 11일

책임저자 : 손 진 희  
주 소 : (110-746) 서울특별시 종로구 평동 108,  
강북삼성병원  
전 화 : 02-2001-2391  
팩 스 : 02-2001-2398  
E-mail address: idavidkim@yahoo.co.kr

Sono-guided fine needle aspiration (FNA) of the thyroid is widely used, but the aspirated samples are typically not well preserved and low cellularity makes diagnosis difficult in many cases. The object of the current study is to evaluate the adequacy and diagnostic accuracy of the use of SurePath™ liquid-based cytology (SP-LBC) in the sono-guided fine needle aspiration of the thyroid nodule and to compare its use with that of the use of a conventional smear (CS). A total of 172 sono-guided FNAs of thyroid nodules from April to June, 2006 were prepared by the use of the split method with either SP-LBC or CS; the samples were stained with the use of hematoxylin-eosin (H&E) and Papanicolaou (Pap) stains. A cyto-histological correlation was performed in 69 (30 SP and 39 CS) cases that had been histologically confirmed. The rate of producing unsatisfactory slides by the use of the SP-LBC method (9.3%) was less than that of the use of the CS method (20.9%). The diagnostic accuracy of the SP method (93.3%) was better than that of the CS method (85.3%). The sensitivity and specificity of the SP method (94.4% and 92.3%) was better than that of the CS method (83.3% and 70%), respectively ( $p < 0.05$ ). The CS of sono-guided aspirated specimens had some unavoidable limitations related to inadequate sampling such as a bloody background, low cellularity and an indication that some clinicians smeared many useless slides (averaging four to ten slides), and that most slides showed only blood that included few follicular cells. The SP method resulted in more thinly smeared slides and showed cleaner background and greater cellularity than the use of the CS method. Each follicular cell shows superior nuclear detail, and more distinct cytoplasmic features than with the use of the CS method. SP-LBC appears to be an easy, highly accurate, and reliable cytological method for employ for a diagnostic approach of thyroid disease and thyroid nodules. The SP-LBC method is a suitable alternative to the CS method to overcome diagnostic difficulties.

(*Korean J Cytopathol* 2007;8(2):143-152)

**Key Words** : SurePath™, Fine-needle aspiration, Thyroid

## INTRODUCTION

Fine-needle aspiration (FNA) of the thyroid gland is considered the best method and the first step in the management of patients with a thyroid nodule. A conventional smear (CS) of sono-guided aspirated specimens has some limitations related to inadequate sampling such as a bloody background and low cellularity. In the case of a CS, some clinicians typically smear many useless slides (averaging four to ten slides) and most slides show only blood that included a few follicular cells. Although thyroid FNA is widely accepted as the primary diagnostic procedure for thyroid nodules, very few studies have been published on the use of liquid-based techniques.<sup>1-6</sup>

MonoPrep™(MP), ThinPrep™ (TP), and SurePath™ (SP) methods have been recently used as liquid-based cytology (LBC) techniques and the SP method has been used in gynecological specimens in our laboratory since June 2005. The SurePath™ liquid-based cytology (SP-LBC) system is a slide-preparation device that recently has become widely available as a technique for the collection and preparation of gynecological specimens. SP-LBC prepares a monolayer of cells on a glass slide from cells collected in a SP collection vial containing a preservative solution. Several studies have suggested that the SP method has an improved diagnostic sensitivity than conventional preparation methods for gynecological specimens.<sup>7-9</sup>

Several methods using liquid-based thin-layer preparations for non-gynecological cytology specimens have shown improved diagnostic accuracy, and the liquid-based methods have been used increasingly. However, reported pathological studies of the use of LBC techniques in thyroid disease and thyroid nodule using FNA technique are limited.<sup>1-6</sup> There are still concerns about the use of SP-LBC methods for non-gynecological cytological examinations and FNAs.

We investigate here the efficacy of the SP-LBC method on sono-guided FNA of thyroid nodules.

## MATERIALS AND METHODS

### 1. Patient population and Procedures

A total of 344 consecutive thyroid FNAs were examined during the study period. One hundred seventy-two (50%) samples were prepared by the SP method and 172 (50%) samples by the CS method. These samples were aspirates and were prepared by the same radiologist with both the SP and CS methods. We were unable to divide a single same sample into a simple that could be prepared by either the SP or CS method as the amount of the aspirates was small and we were worried about an inadequate division of the sample. A histological correlation was available for 69 (20.1%) samples (30 SP and 39 CS).

#### 1) SP method

Cytology slides prepared by SP methods from 172 patients that underwent a sono-guided thyroid FNA at Kangbuk Samsung Hospital from April to June 2006 were reviewed. Those cases were diagnosed as follows: being positive for a papillary carcinoma, suspicious for a papillary carcinoma, indeterminate findings, follicular neoplasm, chronic lymphocytic thyroiditis and nodular hyperplasia. A histological examination was performed for 30 cases among the 172 samples.

Radiologists performed the sono-guided aspirations and the aspirates were immediately placed into a Blue Max™ 50 ml polypropylene conical tube with 30 ml CytoRich® red preservative, which was capped, labeled, and was sent with the appropriate paperwork to the laboratory for processing. In the laboratory, the preserved cellular sample was mixed by vortexing to homogenize the sample. The mixed specimen with was centrifuged at 1800 rpm for 10 min to obtain a precipitate. Non-diagnostic debris and cells were removed from the sample. After centrifugation, the pelleted cells were placed into a 15 ml centrifuge tube with 5 ml TBS (tris-buffered saline). The mixed specimen was centrifuged at 1800 rpm for 5 min. Non-diagnostic debris and cells were removed from the sample. After cen-

trifugation, the pelleted cells were vortexed to homogenize the sample. The sample was transferred to a 13mm diameter PrepStain settling chamber mounted on a microscope slide. The slides were coated with a PrepStain slide coat to enhance cell adhesion. The cells were sedimented by gravity. The slides were then stained on the PrepStain slide processor using an hematoxylin-eosin (H&E) and a Papanicolaou (Pap) staining procedure. The slide was cleared with xylene and coverslipped. The slides prepared by the SP methods exhibit a well-preserved population of stained cells present within a circle measuring 13 mm in the greatest dimension. We prepared one Pap stained slide and one H&E stained slide for each sample prepared by the SP method.

2) CS method

Cytology slides prepared by the CS method from 172 patients that underwent thyroid sono-guided FNA at Kangbuk Samsung Hospital obtained from October 2005 to February 2006 were reviewed. A histological examination was performed for 39 cases among all of the samples. Individual cytological features were evaluated and cytological and histological diagnoses on the thyroidectomy specimens were correlated.

The FNAs were taken with a 23-gauge needle on a 10ml syringe. FNAs were performed on patients that were referred to the Department of Radiology for cytological evaluation of thyroid lesions. The same radiologist under continuous real-time sonographic guidance obtained the FNAs. The material from the first two passes was expelled directly onto the slides and was directly smeared, and was quickly fixed with alcohol for the CS method in accordance with a previously described technique.<sup>5</sup> Slides were sent to the Pathology Department for processing.

The radiologists smeared an average of four to ten slides, and most slides were smeared only with blood that included a few follicular cells. Half of the slides were Pap stained slides and half were H-E stained slides.

Table 1. Cytologic Diagnoses in SP and CS Methods

Cytologic diagnosis	No. in SP (%)	No. in CS (%)
Inadequate	16 ( 9.3)	36 (20.9)
Nodular hyperplasia	105 (61.0)	68 (39.5)
Chronic lymphocytic thyroiditis	5 ( 2.9)	6 (3.5)
Follicular neoplasm	10 (5.8)	21 (12.2)
Indeterminate	12 (7.0)	14 (8.1)
Suspicious papillary carcinoma	7 (4.1)	4 (2.3)
Papillary carcinoma	17 (9.9)	23(13.4)
Total	172 (100)	172 (100)

SP : SurePath™

CS : Conventional smear

2. Cytological diagnosis

Several different cytological features were evaluated including background, cellularity, chromatin pattern, nuclear features, size of nucleoli, the presence of nuclear enlargement and molding, sheets or papillary structures and calcifications. The reviewer was blinded to the histological findings at the time of assessment of these cytological features.

The cytological results were divided into seven categories: unsatisfactory, nodular hyperplasia, chronic lymphocytic thyroiditis, a follicular neoplasm, indeterminate, suspicious for a papillary carcinoma, and a papillary carcinoma (Table 1).

RESULTS

1. Adequacy of the specimens

In each group of 172 FNAs, 16 samples prepared by the SP method were considered unsatisfactory for diagnosis (9.3%) as compared with 36 samples prepared by the CS method (20.9%) (Table 1). In all of the samples prepared by the SP method, an insufficient quantity of cells was the only cause for an unsatisfactory classification. A moderate to high degree of cellularity was

Table 2. Correlation of FNAs and Histologic Diagnoses of 30 Cases in SP methods

Histologic diagnosis \ FNAs diagnosis	PC*	SPC †	Indeterminate	FN ‡	CLT§	NH#	Inadequate	Total
PC	11	6	1	0	0	0	0	18
Follicular adenoma	0	0	1	1	0	1	0	3
NH	0	0	3	0	0	5	0	8
CLT	0	0	0	0	1	0	0	1
Total	11	6	5	1	1	6	0	30

\* : Papillary carcinoma

† : Suspicious papillary carcinoma

‡ : Follicular neoplasm

§ : Chronic lymphocytic thyroiditis

# : Nodular hyperplasia

Calculation for statistics(histologically confirmed cases)

Sensitivity for neoplasm = (PC)+(SPC)/(PC)-(inadequate) = (11+6)/(18-0) × 100=94.4%

Specificity for neoplasm = (Benign)/(Benign)-(inadequate) = (12)/(13-0) × 100=92.3%

Diagnostic accuracy = (Correct cases)/ (Total cases excluding inadequate) = (28)/(30-0) × 100=93.3%

observed in all other samples prepared by the SP method. In samples prepared by the CS method, a thick bloody smear, poor fixation and an insufficient quantity of cells were causes for being unsatisfactory. A lower level of cellularity was also observed in the satisfactory samples prepared by the CS method.

## 2. Diagnostic accuracy

### 1) SP method

There were 105 (61.0%) nodular hyperplasia lesions, 5 (2.9%) chronic lymphocytic thyroiditis lesions, 10 (5.8%) follicular neoplasms, 12 (7.0%) indeterminate lesions, 7 (4.1%) suspicious papillary carcinomas, and 17 (9.9%) papillary carcinomas (Table 1). Among the 172 FNAs, it was possible to compare the cytology results with thyroidectomy specimens in only 30 cases (18 papillary carcinomas, 3 follicular adenomas, 8 nodular hyperplasias and 1 chronic lymphocytic thyroiditis). There were no false negative and no false positive samples. Among the seven lesions suspicious for a papillary carcinoma, six samples were available for a histological examination and all six lesions were identified as papillary carcinomas. Among the seventeen papillary carcinoma lesions, eleven cases were avail-

able for a histological examination and all eleven lesions were identified as a papillary carcinoma. Among the twelve lesions that were indeterminate, five cases were histologically evaluated and one lesion was identified as a papillary carcinoma, one lesion was identified as a follicular adenoma and three lesions were identified as nodular hyperplasias (Table 2).

### 2) CS method

A total of 172 samples were prepared by the CS method, including 68 nodular hyperplasia lesions (39.5%), 6 chronic lymphocytic thyroiditis lesions (3.5%), 21 follicular neoplasms (12.2%), 14 indeterminate lesions (8.1%), 4 suspicious papillary carcinomas (2.3%) and 23 papillary carcinomas (13.4%) (Table 1). Among the samples, it was possible to compare the cytology results with thyroidectomy specimens in only 39 cases (twenty-five papillary carcinomas, six follicular adenomas and eight nodular hyperplasias). There were two false negative cases for the samples prepared by the CS method (two benign cytologies-a nodular hyperplasia, a chronic lymphocytic thyroiditis, that were confirmed as a papillary carcinomas). There were no false positive cases. Among the four lesions suspicious for a papillary carcinoma, a histological correlation was avail-

**Table 3.** Correlation of FNAs and Histologic Diagnoses of 39 Cases in CS methods

FNAs diagnosis \ Histologic diagnosis	PC	SPC	Indeterminate	FN	CLT	NH	Inadequate	Total
PC	19	1	2	0	1	1	1	25
Follicular adenoma	0	0	3	0	0	0	3	6
NH	0	0	2	1	0	4	1	8
CLT	0	0	0	0	0	0	0	0
Total	19	1	7	1	1	5	5	39

Calculation for statistics(histologically confirmed cases)

Sensitivity for neoplasm = (PC)+(SPC)/(PC)-(inadequate) = (19+1)/(25-1) × 100=83.3%

Specificity for neoplasm = (Benign)/(Benign)-(inadequate)= (7)/(14-4) × 100=70%

Diagnostic accuracy = (Correct cases)/ (Total cases excluding inadequate) =(29)/(39-5) × 100=85.3%

able in one case and the lesion was identified as a papillary carcinoma. Among the twenty-three papillary carcinoma lesions, histological correlations were available for nineteen cases and all nineteen lesions were identified as papillary carcinomas. Among the fourteen indeterminate lesions, histological correlations were available for seven cases and two lesions were identified as papillary carcinomas, three lesions were identified as follicular adenomas and two cases were identified as nodular hyperplasias (Table 3).

### 3. Morphological diagnostic criteria for the SP slides

Concerning benign lesions (nodular hyperplasias and follicular adenomas), we were able to observe cell clusters, in smaller or in larger quantities, with round and regular nuclei, mild anisokaryosis, dense chromatin and basophilic cytoplasm. Nodular hyperplasia lesions show mono-layered sheets of follicular cells that exhibit well spaced small dark nuclei on a clean background. Some follicular cells had voluminous pale cytoplasm, enlarged nuclei delineated by a thick nuclear membrane and included clumped chromatin, suggesting reactive changes. In the background, there were occasional dense droplets of colloid and often some dispersed colloidophages and degenerate follicular cells (Fig. 1).

There are some distinctive cytological criteria

between follicular adenomas and nodular hyperplasia lesions. The colloidophages and reactive cells were seen more often in nodular hyperplasia lesions. In the follicular adenomas, more crowded cellularity of mono-layered follicular cell clusters and small follicular arrangements were noted. However, the presence or absence of colloid was not a decisive factor for the identification of a follicular adenoma and nodular hyperplasia lesion.

For papillary carcinomas, the features were quite similar but were more clear than the features observed on slides prepared by the CS method: small cells arranged in three dimensional clusters or mono-layered flat sheets or syncytial fragments with mild anisokaryosis, angulated nuclear membranes, nuclear cytoplasmic inclusions, nuclear grooves and ground glass nuclei with an underlined membrane were noted (Fig. 2).

For chronic lymphocytic thyroiditis, the smears show a mixture of follicular cells with a few oncocyctic cells in the background of lymphoid cells (Fig. 3). However, it is very difficult to distinguish lymphocytes from degenerating follicular cells. This made it very difficult to distinguish chronic lymphocytic thyroiditis lesions from benign follicular proliferating lesions. The presence of evenly distributed lymphoid cells, scattered follicular cells and some oxyphilic cells can be helpful in making a diagnosis of chronic lymphocytic thyroiditis, as seen on the samples prepared by the SP method.

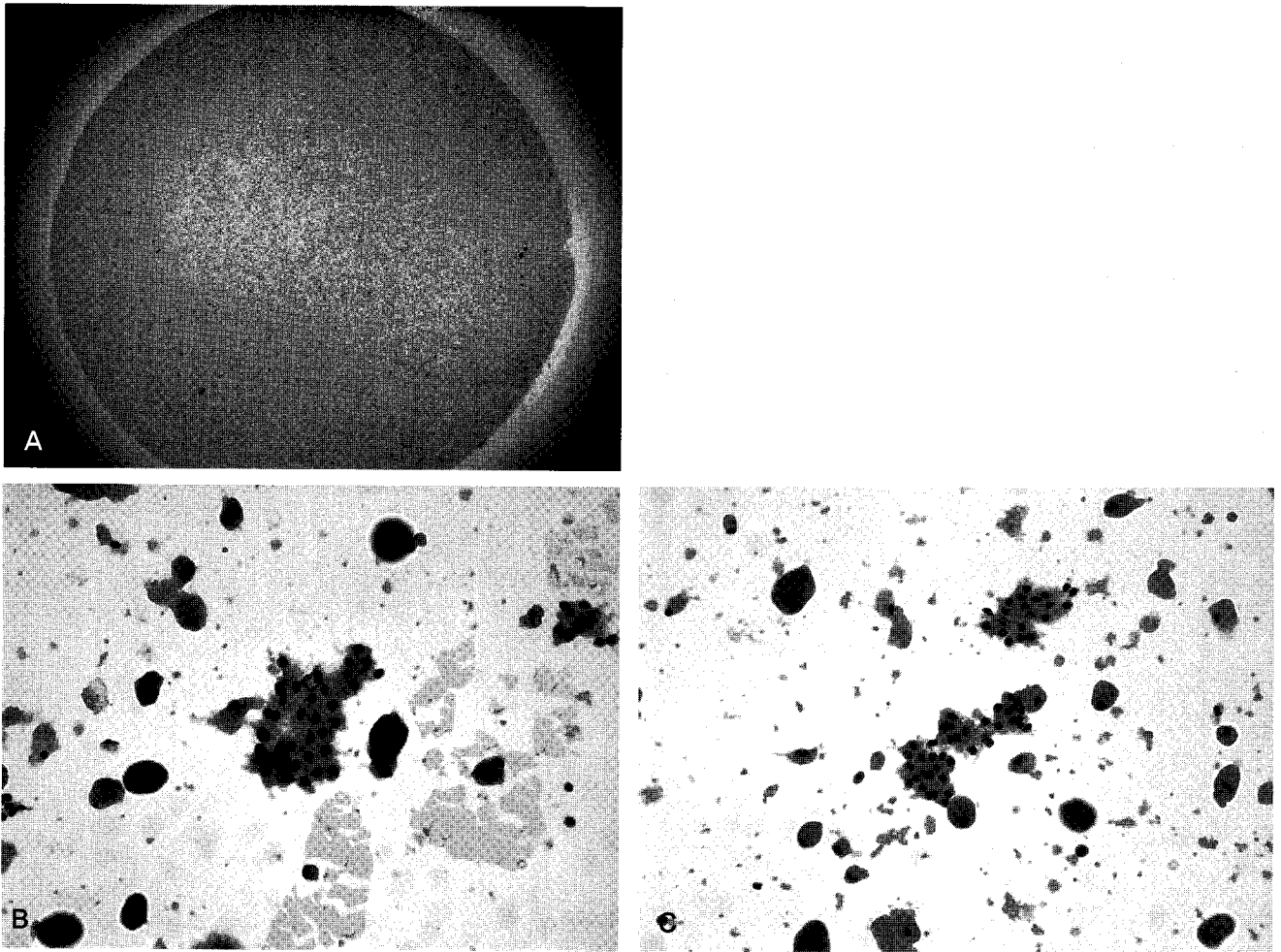


Fig. 1. Cytologic finding of SurePath™ method with nodular hyperplasia. A to C: Nodular hyperplasia shows mono-layered sheet of follicular cells with well-spaced nuclei in clean background. (A&B; Papanicolaou, C; H&E).

#### 4. Benefits of SP method in comparison to the CS method

The CS method is restrictive in evaluating cytological slides because of many useless smeared slides, low cellularity, drying artifacts and poor fixation. The CS method requires more effort and time consumption and has a decreased rate of accuracy.

The rate of producing unsatisfactory slides by the use of the SP method (9.3%) was less than that of the use of the CS method (20.9%). The diagnostic accuracy of the SP method (93.3%) was better than that of the CS method (85.3%). The sensitivity and specificity of the SP method (94.4% and 92.3%) was also better than that of the CS method (83.3% and 70%), respectively (Table 2 and Table 3) ( $p < 0.05$ ). The SP method produced thin-

ner smears than the CS method. In addition, the SP method produced slides with a cleaner background and greater cellularity than the CS method. Each follicular cell shows superior nuclear detail, and more distinct cytoplasmic features than with the use of the SP method. The advantages of the use of the SP method are the clear cellular features seen on the slides from adequate and rapid fixation and a decrease in the number of red blood cells, inflammatory cells, non-diagnostic debris and cells and the saving in time and effort for diagnosis. However, awareness of the cytomorphological features seen in the samples prepared with the SP method is essential for avoiding misinterpretations.

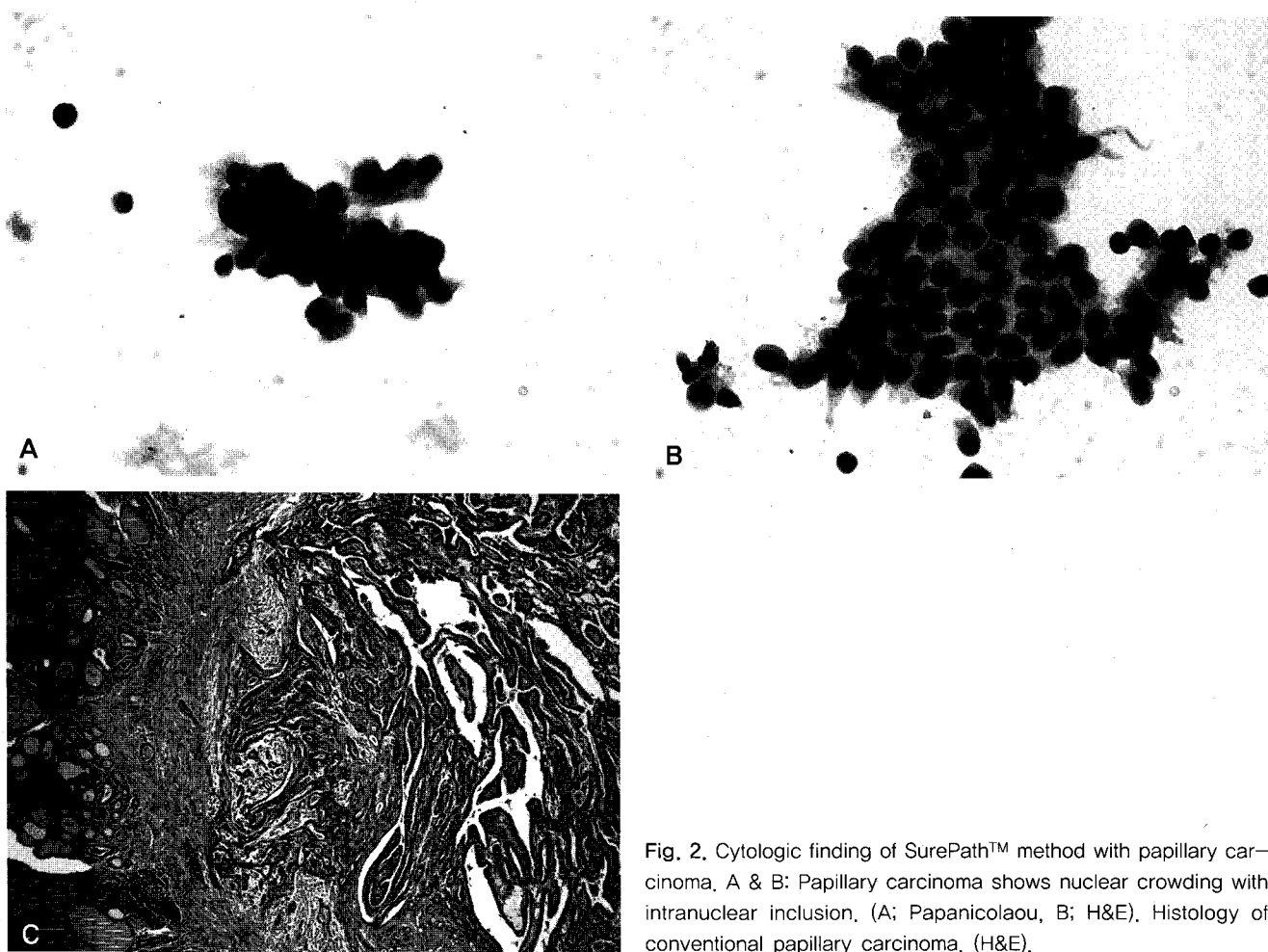


Fig. 2. Cytologic finding of SurePath™ method with papillary carcinoma. A & B: Papillary carcinoma shows nuclear crowding with intranuclear inclusion. (A; Papanicolaou, B; H&E). Histology of conventional papillary carcinoma. (H&E).

## DISCUSSION

LBC is a relatively new technique in the field of diagnostic cytopathology. However, an increased number of applications in gynecological and non-gynecological cases have been reported in the literature.<sup>1-9</sup> This technique offers the possibility of accurate transportation, fixation, and reproducible preparation of cytological smears. Moreover, the material is safe to use and the prepared slides are of improved quality relative to those prepared with CS methods. Most of the previously published studies about LBC have evaluated the use of the ThinPrep® (TP) method.<sup>1-6</sup> Since June, 2005, SP-LBC has become a routine diagnostic procedure for producing gynecological smears in our department and we decided to evaluate the diagnostic accuracy of this tech-

nique for thyroid disease and thyroid nodules to improve preoperative diagnosis rates, as the CS method is restrictive in evaluating cytological slides due to many useless smeared slides, thick bloody smears, low cellularity, drying artifacts and poor fixation. As there are no previous studies on the use of the SP method of FNAs on thyroid disease, so we compared our SP study with previously reported TP method.

Frost et al,<sup>2</sup> compared the use of direct smear and thin layer methods in 135 patients. In that study, the rate of unsatisfactory cases was 1.5%. According to Cochand et al.<sup>5</sup> the rate of unsatisfactory cases was 3.8%. In our study, the rate of unsatisfactory cases was 9.3% for slides prepared by the SP method, which was lower than for slides prepared by the CS method (20.9%). The rate of unsatisfactory cases in our study is higher than in previous studies,<sup>2,5</sup> but, it is very difficult

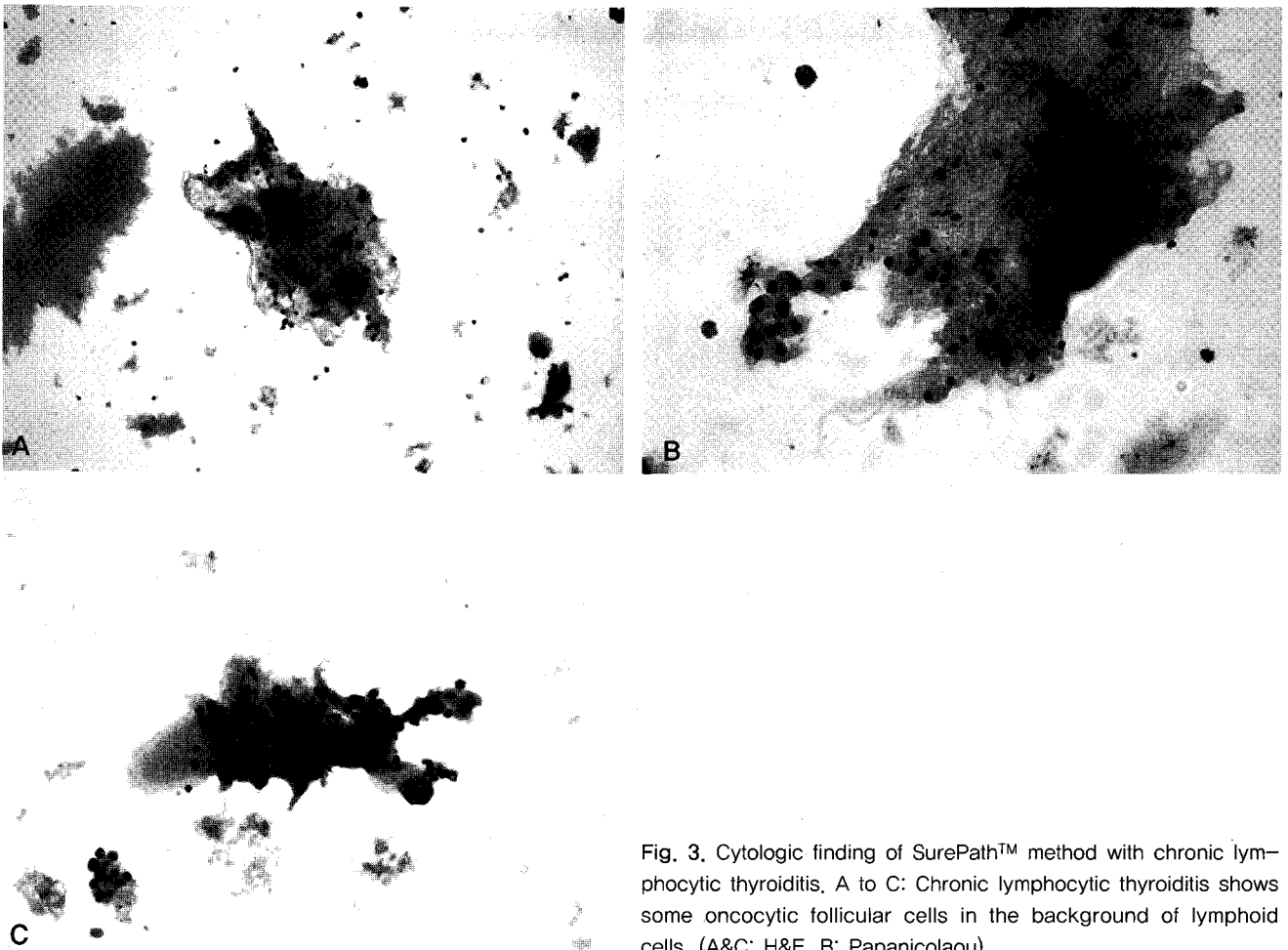


Fig. 3. Cytologic finding of SurePath™ method with chronic lymphocytic thyroiditis. A to C: Chronic lymphocytic thyroiditis shows some oncocytic follicular cells in the background of lymphoid cells. (A&C: H&E, B; Papanicolaou).

to interpret the previous study results, as the majority of the lesions were benign and only a limited number of patients underwent surgery.

Some studies show high rates of unsatisfactory cases. According to Scurry et al,<sup>4</sup> the rate of unsatisfactory cases for the TP method was 40.9%. The present study has a lower rate of unsatisfactory specimens than the study of Scurry and colleagues. Reasons for obtaining unsatisfactory specimens may include incorrect aspiration of a suspicious lesion that leads to a sampling error or an inadequate number of collected cells, or inappropriate dilution of material in the SP sampling tube. To decrease further the number of unsatisfactory specimens, performance of the aspiration technique should be improved with training that is more expensive.

In the present study, the diagnostic accuracy was 93.3% for samples prepared by the SP method and

89.7% for samples prepared by the CS method. Cochand et al<sup>5</sup> compared the use of direct smear and thin layer methods for samples from 132 patients. In that study, the diagnostic accuracy was 89% for samples prepared by the TP method. Frost et al<sup>2</sup> compared the use of direct smear and thin layer methods for samples for 113 patients, and the diagnostic accuracy was 85% for samples prepared by the TP method. The present study shows a better diagnostic accuracy than the previously reported studies that employed the TP method and the CS method.

The sensitivity of the use of LBC methods in previously reported studies for thyroid FNAs ranged from 80% to 95%, with a specificity that ranged from 60% to 87.7%.<sup>1,5,6</sup> In the present study, the sensitivity and specificity of the use of the SP method was 94.4% and 92.3%, which were higher than in previous studies



using the TP method. The cause of this difference is unknown and there may be many factors involved; a comparison between the use of the SP method and the TP method may be required.

Afify et al<sup>1</sup> described that the nuclear cytoplasmic inclusions were rarely observed in the cytomorphological features of a papillary carcinoma using the LBC method. Zhang et al<sup>3</sup> described that many nuclear grooves and powdery chromatin were significantly associated with the presence of a papillary carcinoma. However, in the present study, the presence of ground glass nuclei with an underlined folded nuclear membrane was frequent, and papillae, nuclear cytoplasmic inclusions and nuclear grooves were also frequently noted.

Five cases of chronic lymphocytic thyroiditis were recognized on slides prepared by the SP method in our series. According to Frost et al,<sup>2</sup> a diagnostic error of chronic lymphocytic thyroiditis on slides prepared by a LBC method are caused by the presence of atypical cells. Making the distinction between degenerated naked follicular cells and lymphocytes of chronic lymphocytic thyroiditis may be difficult on slides, especially in bloody smears, because of the presence of dispersed lymphocytes. However, even with the distribution and large amounts of lymphocytes, oxyphilic changes of follicular cells are helpful in a differential diagnosis. In addition, some follicular cells can exhibit anisokaryosis and nuclear atypism, which should be an indication of chronic lymphocytic thyroiditis. These atypical follicular cells should not be mistaken as the malignant cells. The SP method does offer some more advantages in evaluation of nuclear details.

As in previously published studies,<sup>1-6</sup> particular morphological features were observed in slides prepared by the LBC method: the amount of colloid was diminished and often occurred in small dense droplets rather than as observed with the CS method. Nuclei tended to appear smaller but the nuclear details, especially the nuclear membrane, the chromatin and the nucleoli were more easily observed. This is because of the use

of the ethanol and methanol fixative. Single epithelial cells were equally visible in slides prepared by both methods. Therefore, training and experience about the cytological features observed with use of the SP method are needed.

The SP method produces good quality slides with H-E staining, which is familiar staining method for most pathologists. It is very helpful to make a diagnosis by evaluating slides stained with Pap stains combined with H&E stain.

## CONCLUSION

For the SP-LBC method, a decreased rate of inadequate samples was observed when compared with the use of the CS method in our study. However, to further decrease the level of inadequate sampling, the use of a direct to vial technique and an improved aspiration technique is needed.

The use of the SP method improves the diagnostic accuracy of thyroid FNAs rather than the use of the CS method. The SP method is easier and to perform and less time consuming to screen and interpretate the slides. However, an awareness of the cytomorphological features observed with the use of the SP method is essential to avoiding misinterpretation. SP-LBC is available as an alternative method to CS to overcome the diagnostic difficulties.

## REFERENCES

1. Afify AM, Liu J, Al-Khafaji BM. Cytologic artifacts and pitfalls of thyroid fine-needle aspiration using ThinPrep: a comparative retrospective review. *Cancer* 2001;93:179-86.
2. Frost AR, Sidawy MK, Ferfelli M, et al. Utility of thin-layer preparations in thyroid fine-needle aspiration: diagnostic accuracy, cytomorphology, and optimal sample preparation. *Cancer* 1998;84:17-25.
3. Zhang Y, Fraser JL, Wang HH. Morphologic predictors of papillary carcinoma on fine-needle aspiration of thyroid with ThinPrep preparations. *Diagn Cytopathol* 2001;24:378-83.

4. Scurry JP, Duggan MA, Thin layer compared to direct smear in thyroid fine needle aspiration. *Cytopathology* 2000;11:104-15.
5. Cochand-Priollet B, Guillausseau PJ, Chagnon S, et al. The diagnostic value of fine-needle aspiration biopsy under ultrasonography in nonfunctional thyroid nodules: a prospective study comparing cytologic and histologic findings. *Am J Med* 1994;97:152-7.
6. Cochand-Priollet B, Prat JJ, Polivka M, et al. Thyroid fine needle aspiration: the morphological features on ThinPrep® slide preparations. Eighty cases with histologic control. *Cytopathology* 2003;14:343-9.
7. Park JM, Jang JW, Lim SY, Lee JG, Suh IS. Evaluation of the manual method of liquid-based uterine cervicovaginal cytology - by the manual method based on SurePath™ methodology. *Korean J Cytopathol* 2004;15:86-91.
8. Colgan TJ, McLachlin CM, Cotterchio M, Howlett R, Seidenfeld AM, Mai VM. Results of the implementation of liquid-based cytology-SurePath in the Ontario screening program. *Cancer* 2004;102:362-7.
9. Fremont-Smith M, Marino J, Griffin B, Spencer L, Bolick D. Comparison of the SurePath liquid-based Papanicolaou smear with the conventional Papanicolaou smear in a multisite direct-to-vial study. *Cancer* 2004;102:269-79.

