

# The clinical features of the infratemporal fossa abscess and their significances

Horatiu Rataru<sup>1</sup>, Michael Cho<sup>2</sup>, Yong-Chan Lee<sup>3</sup>, Byoung-Eun Yang<sup>3</sup>, Seong-Gon Kim<sup>3,\*</sup>,  
Jwa-Young Kim<sup>3</sup>, Jin-Cheol Kim<sup>3</sup>, Young-Hee Kim<sup>3</sup>

<sup>1</sup>Department of Craniomaxillofacial Surgery, "Iuliu Hatieganu" University of Medicine and Pharmacy, Cluj-Napocca, Romania

<sup>2</sup>Dept. of Plastic and Reconstructive Surgery, The Children's Hospital of Philadelphia, Pennsylvania, USA

<sup>3</sup>Department of Oral and Maxillofacial Surgery, Sacred Heart Hospital, Hallym University, Kyoungkido, Republic of Korea

## Abstract

**Objective.** The objective of this international comparative study was to investigate the clinical features and outcome of the treatment of infratemporal fossa abscess (IFA).

**Study design.** This retrospective study was conducted at the Department of Oral and Maxillofacial Surgery of Hallym University and "Iuliu Hatieganu" University of Medicine and Pharmacy. Ten-year records of patients were reviewed in Romania and six-year records were reviewed in Korea. The collected data was then analyzed.

**Results.** A total of 36 cases were found to be IFA (12 males and 24 females: average age;  $36.3 \pm 15.5$  yrs: 34 cases from Romania and 2 cases from Korea). The annual frequency of IFA in Romanian and Korean hospitals was 3.40 and 0.33 respectively ( $P < 0.001$ ). The etiology was septic anesthesia (33.3%), infection occurring after extraction (30.6%), periapical lesion (13.9%), impacted third molar (8.3%), post-extraction alveolitis (5.6%), and unknown (8.3%). A successful outcome was seen in 27 patients (75.0%) after initial treatment. The main complication after initial treatment was restricted movement of the mouth (9 cases).

**Conclusion.** The etiology of IFA was various and minimal swelling hampered early diagnosis. To prevent IFA, preoperative painting with antiseptic agent must be stressed and proper drainage proved important to relieve pain and to prevent further complications.

## INTRODUCTION

The infratemporal space is a deep facial space where the syringe needle is inserted frequently during block anesthesia<sup>1)</sup>. It consists of two compartments as follows: an upper-internal compartment, named as the pterygo-maxillary space, which is in fact the true infratemporal space, and a lower-external compartment, named as pterygomandibular space, localized between the internal side of the ascending ramus and the internal pterygoid muscle (Fig. 1). These two compartments are incompletely separated by the external pterygoid muscle. The above-mentioned spaces communicate in principal with

the buccal space, with the masseteric and temporal spaces following a medial way under and above the zygomatic arch<sup>2,3)</sup>.

Infratemporal fossa abscess (IFA) is not common, because most dental infections spread through the buccal space, submandibular space, or sublingual space. In advanced cases, the infection will spread through the neck space. From these reasons, IFA is rarely case-reported<sup>4-6)</sup>. IFA has been seen as secondary to maxillary sinus fracture<sup>4)</sup>, temporomandibular arthroscopy<sup>5)</sup> and infections involving the maxillary molars<sup>6)</sup>. It also appears as an unusual complication after tooth extraction<sup>7)</sup>.

The clinical symptoms of IFA included restricted movement of the mouth, severe pain, and fever. The swelling in the involved site was not usually severe (Fig. 2A) except for far advanced cases (Fig. 2B). The objective of this study was to investigate the international difference in clinical features and the outcome of treatment of IFA.

\* Corresponding author

Seong-Gon Kim

Dept. of OMFS, Sacred Heart Hospital, Hallym University  
#896, Pyungchon-Dong, Dongan-Gu, Anyang-city, Kyungki-do,  
431-070, Korea

Tel: 82-31-380-3873 Fax: 82-31-387-2475

E-mail: epker@chollian.net

## Patients and Methods

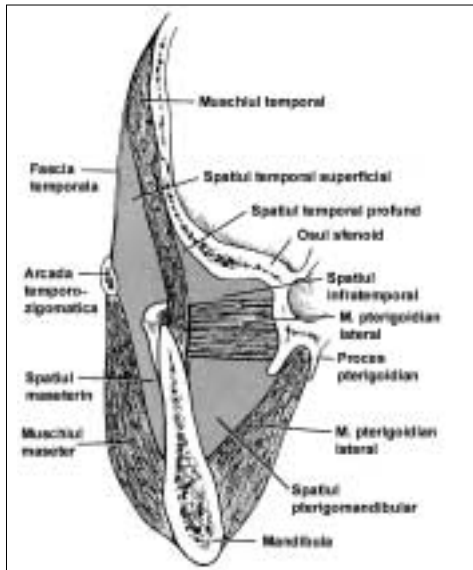
This retrospective study was conducted at the Department of Oral and Maxillofacial Surgery of Sacred Heart Hospital, Hallym University, Korea and "Iuliu

Hatieganu" University of Medicine and Pharmacy, Cluj-Napoca, Romania. The records of all patients with IFA (seen from March 1992 to March 2001 in Romania and from March 1999 to March 2005) were evaluated and analyzed according to age, sex, cause, clinical symptoms, and treatment. For the analysis of cause, the previous history of the patient was closely examined.

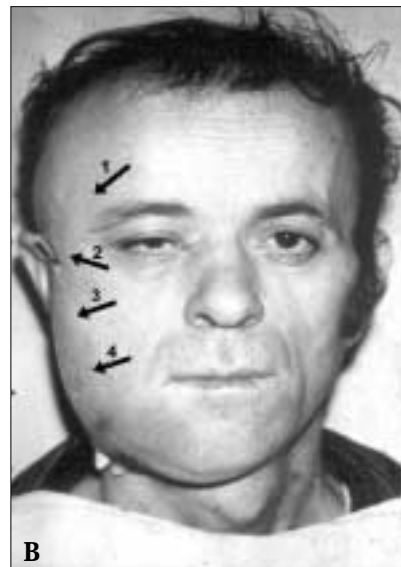
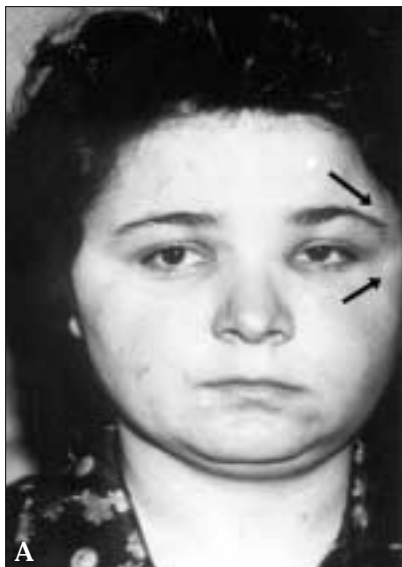If the patient received a dental procedure under nerve block anesthesia within 1 week, and there was no other infection site in the oral or peri-oral structures, and the abscess was formed in the injection site, then the cause of abscess was written as septic anesthesia.

The patient variables recorded for analysis included the following: sex, age, cause, symptoms, systemic disease, surgical techniques, microbiology of the infection, length of patient follow-up, and clinical and radiographic findings.

The minimum length of follow-up was 1 year. The cure rate was evaluated at follow-up. Outcome criteria for successful treatment were determined by analyzing the relief of pain and the measurement of maximum mouth opening. The annual frequency of each country was compared with the independent sample t-test. The significance level was set as  $P < 0.05$ .



**Fig. 1.** The anatomy of the infratemporal space. It consists of the pterygomaxillary space and the pterygomandibular space.



**Fig. 2.** Clinical presentation of the infratemporal fossa abscess. A. Mild facial swelling was seen in the left temporal area (arrows). B. Advanced case with involvement in both spaces (arrows).

## RESULTS

### Clinical features and etiology

This retrospective study involved 36 patients, 12 males (33.3%) and 24 females (66.7%), 11 to 73 years of age (Table 1). Thirty-four cases were from Romania and 2 cases from Korea. The average age of patients was  $36.3 \pm 15.5$  years-old. All cases from both countries were referred from local clinics. The annual frequency of IFA in "Iuliu Hatieganu" University, Romania was 3.40 cas-

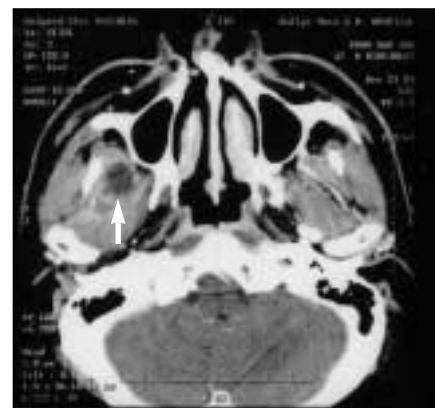es/ year and it was 0.33 cases/ year in Sacred Heart Hospital, Korea. The annual frequency of IFA was significantly different ( $P < 0.001$ ).

Solitary IFA developed in 23 of the 36 cases (63.9%) and occurred in all age groups. Twenty-two cases were from Romania and 1 case from Korea. The annual frequency of solitary IFA in "Iuliu Hatieganu" University, Romania was 2.30 cases/ year and it was 0.17 cases/ year in Sacred Heart Hospital, Korea. The annual frequency of solitary IFA was significantly different between the hospitals ( $P < 0.001$ ).

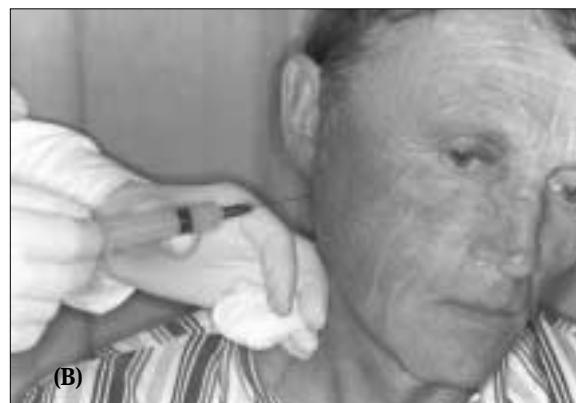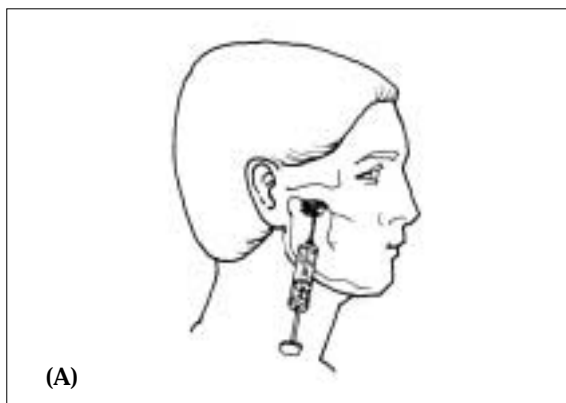
**Table 1.** Characteristics of study patients.

Patients	36
Mean age (yr)	36.3
Age range (yr)	11-73
Female	24 (66.7%)
Male	12 (33.3%)
Solitary IFA	23 (63.9%)
Involvement	
Right	19 (52.8%)
Left	17 (47.2%)
Cause	
Septic Anesthesia	12 (33.3%)
Post-extraction infection	11 (30.6%)
Periapical lesion	5 (13.9%)
Impacted third molar	3 (8.3%)
Post-extraction alveolitis	2 (5.6%)
Unknown	3 (8.3%)

(IFA: infratemporal fossa abscess)



**Fig. 3.** CT scan demonstrating abscess formation in the right infratemporal fossa (arrow). The morphology was a round shape and closely approximate to the lingula of the mandible.



**Fig. 4.** The aspiration technique. A. diagrammatic view. B. It can be used for diagnostic purposes and for the relieving of pressure that can induce pain.

Nineteen cases (52.8%) were involved in the right side and 17 cases (47.2%) in the left side. In 12 cases (33.3%), the disease was most directly associated with septic anesthesia. 11 cases (30.6%) were associated with infection occurring after extraction. Five cases (13.9%) were associated with periapical lesion. Three cases (8.3%) were associated with impacted third molar and 2 cases (5.6%) were associated with post-extraction alveolitis (dry socket). In 3 cases (8.3%), it was impossible to determine the cause of the disease.

The clinical symptoms of patients at admission were as follows (Table 2): 30 presented a severe pain, no one had intraoral pus discharge or skin fistulas, and all cases had restricted movement of the mouth. The average measurement of the mouth opening was  $9.65 \pm 5.76$  mm before treatment. Twenty-nine cases showed swelling around the zygomatic arch area, which was varied according to the duration of disease. Twenty-one cases (58.3%) involved the pterygomaxillary space and 7 cases (19.4%) involved the pterygomandibular space. Eight cases

(22.2%) involved both spaces and systemic diseases were documented in only 1 case (diabetes mellitus).

In the routine radiographs, non-specific findings were usually reported. For the exact diagnosis, Computerized Tomograms (CT) or Magnetic Resonance Imaging (MRI) were more helpful. In the case of solitary IFA, a cystic mass filled with fluid in the medial side of the mandibular ramus was usually found (Fig. 3).

### Microorganisms, Treatment, and Prognosis

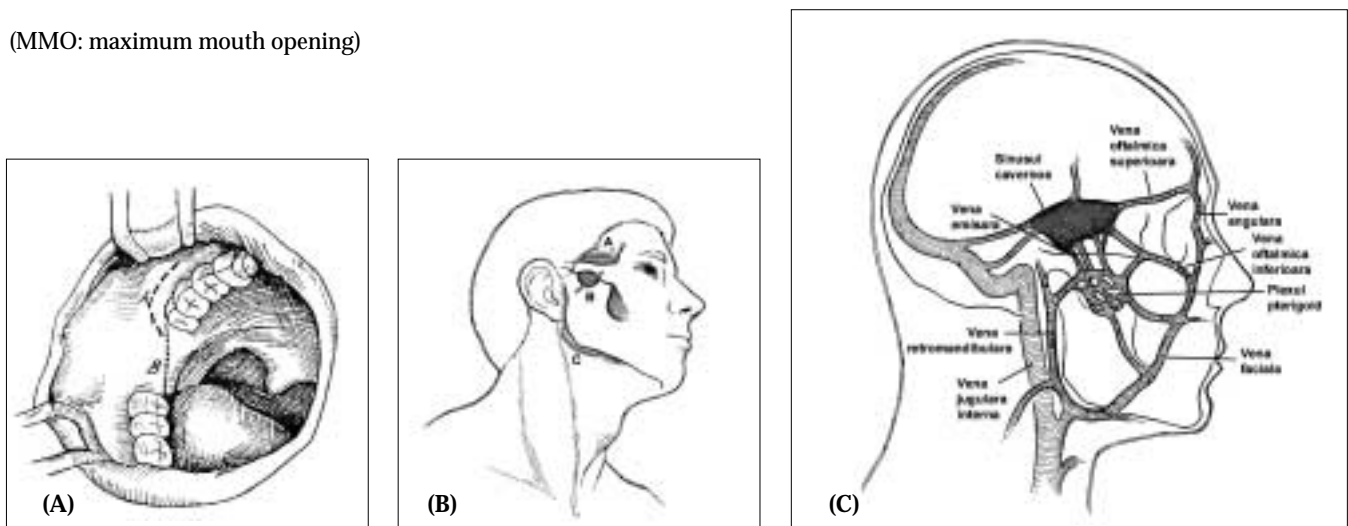
For the differential diagnosis and the assessment of the pathogen, the aspiration technique was administered at the initial phase of the diagnosis (Fig. 4). From 10 cases, we could get the data of the cultured microorganisms. The most commonly cultured microorganisms were *Staphylococci* species. *Staphylococcus aureus* was cultured in 6 cases,  $\alpha$ -hemolytic *Streptococcus* in 2 cases,  $\beta$ -hemolytic *Streptococcus* in 1 case, *Pseudomonas aeruginosa* in 1 case, methicillin-resistant *Staphylococcus aureus* in 1 case, *Enterococcus faecium* in 1 case, and *Streptococcus viridans* in 1 case. More than two species were cultured in 4 cases.

Three (8.3%) cases underwent only extraoral surgery, 21 (58.3%) cases underwent only intraoral drainage and 11 (30.6%) cases underwent both intra and extraoral drainage (Fig. 5A, B). One case underwent a coronoidectomy to improve the surgical vision and to relieve the restriction of the mouth opening. In addition, extraction

**Table 2.** Clinical symptoms and space involvements.

Clinical Symptoms	
Severe Pain	30 (83.3%)
Limitation of opening mouth	36 (100.0%)
Average MMO	$9.65 \pm 5.76$ mm
Space involvements	
Pterygomaxillary space	21 (58.3%)
Pterygomandibular space	7 (19.4%)
Both space	8 (22.2%)

(MMO: maximum mouth opening)



**Fig. 5.** The drainage and the complication. A. Intraoral drainage site. B. Extraoral drainage sites. C. When the infratemporal fossa abscess is not treated properly, the infection can be spread to the cavernous sinus because of anatomical proximity and may be fatal.

of the involved teeth, debridement, and fistulectomy were performed as required.

The parenteral antibiotics given were Augmentin and an aminoglycoside; the oral antibiotics were Augmentin and Roxythromycin. Clindamycin and Metronidazole were used when dictated by the results of bacteriologic culture and antibiotic sensitivity tests. During the medication period, antibiotics were administered parenterally for 2 weeks and orally for 6 weeks.

A successful outcome was seen in 27 patients (75.0%). All patients showed the relief of pain. The restriction of the mouth opening (maximum mouth opening < 40mm) was persistent in 9 cases after treatment, but most patients were treated successfully with a second physical therapy. One patient showed persistent limited movement (maximum mouth opening <30mm).

## DISCUSSION

In the pre-antibiotic era, IFA was commonly associated with dental abscesses and maxillary sinus involvement. The widespread use of prophylactic and therapeutic antibiotics has decreased the incidence of the infratemporal fossa involvement in odontogenic infections<sup>8</sup>. In contrast to the direct spread from dental infection, solitary IFA is difficult to evaluate clinically. This is further hampered by trismus which is a common finding following masticator muscle involvement.

IFA is infrequently observed as a post-extraction complication<sup>7</sup>. In our study, 2 cases (5.6%) from Romania were related to post-extraction alveolitis. As the swelling of IFA is not severe and the parotid gland is anatomically close, the differential diagnosis with the pathology in the parotid gland must be stressed<sup>9</sup>. For this purpose, the CT scan may be the most effective imaging system (Fig. 3)<sup>10</sup>.

Solitary IFA can be observed after the extraction of an uninfected tooth. Considering that there has been no studies of IFA arising after the extraction of an uninfected tooth<sup>11</sup>, it is an important feature of solitary IFA and it makes it more difficult to differentiate from other pathologies. The probable cause of solitary IFA in this study was the direct insemination of infratemporal space by the syringe needle<sup>1</sup>. The etiology of septic anesthesia was only found in solitary IFA in this study (data not shown). In the dental department of the general hospital, cases of needle infection were quite rare because disposable needles were used, and routine scrubs with antiseptics were administered before procedure. That might

explain the reason why all patients in this study were referred cases from local clinics. The economic status of the country also seemed to be influential. The annual frequency of solitary IFA in "Iuliu Hatieganu" University, Romania was 2.30 cases/ year and it was 0.17 cases/ year in Sacred Heart Hospital, Korea. When comparing the incidence of solitary IFA in Romania to that of Korea, there were significant differences ( $P < 0.001$ ). The repeated usage of a dental needle for several patients and the improper state of oral hygiene increased the risk of needle infection in some countries and local clinics. When block anesthesia was performed on the posterior superior alveolar nerve, the pterygomaxillary space was usually involved and when performed on the inferior alveolar nerve, the pterygomandibular space was usually involved. The anesthetic infiltration at the tuberosity level or internal side of the ascending ramus can be a severe septic threat in the following situations; puncturing of the oral mucosa in the conditions of a neglected septic cavity, performing the anesthetic puncture without antiseptically wiping the mucosa in order to eliminate the septic deposits, and the use of an unsterile or desterilized needle or anesthetic solutions.

Moreover, there can be more probable causes of IFA. Among them include maxillary sinus infections<sup>4</sup>, the bone infections of mandible or maxilla and the progression of the infection from the neighborhood superficial or deep facial spaces. Pericoronitis sometimes spreaded into the infratemporal fossa and led to abscess formation<sup>12</sup>. As the abscess increases its size, it gives pressure to adjacent structures. Among the adjacent structures, the pressure or tension to the mandibular or the maxillary nerve results in severe pain. In some cases, this kind of pain was not relieved by the usage of an opioid. Direct drainage may be the best choice to relieve pain. When access to the abscess cavity is hindered by the mandibular ramus, coronoidectomy should be considered. The advantages of coronoidectomy for solitary IFA are as follows. First, it can make easier access to the abscess cavity, and second, it can help to open the mouth as reducing the tension from the temporal muscle. When the coronoid was removed for therapeutic reasons, the functional problems are reported as minimal<sup>13</sup>.

Unfortunately, there were cases, and not few, in which the clinical features were not recognized in the local clinics. Some dental practitioners, especially those involved in the onset of this infection, kept these cases and administered only an antibiotic treatment. Therefore the clini-

cal condition of the patient worsened and the pus extended in both compartments of the infratemporal space. The orbit could be involved through the infra-orbital fissure and the cavernous sinus could be involved through the pterygoid plexus (Fig. 5C). If the pus eroded the great vessels, surgical maneuvers would become risky and vital threat be imminent<sup>14</sup>.

In conclusion, one of the main causes of IFA was septic anesthesia. When the patient involves IFA, early diagnosis and proper drainage will be very important to relieve pain and to prevent further complications. Treatment by medication only seemed not to be helpful to resolve patients' symptoms.

## REFERENCES

1. Rotaru AI: Dental practitioner implication in the infratemporal space infection. *Transilvania Stomatologica* 2001;4:4-11.
2. Popescu V, editors. *Chirurgie Buco-Maxilo-Faciala*. Bucuresti: Didactica si Pedagogica; 1967. p.370-378.
3. Peterson LJ: Complex Odontogenic Infections. In: Peterson LJ, Ellis III E, Hupp J R, Tucker MR, editors. *Contemporary Oral and Maxillofacial Surgery*. St. Louis: Mosby; 1993. p.436-451.
4. Weiss BR: Infratemporal fossa abscess. Unusual complication of maxillary sinus fracture. *Laryngoscope* 1977;87:1130-1133.
5. Chossegros C, Cheynet F, Conrath J: Infratemporal space infection after temporomandibular arthroscopy: An unusual complication. *J Oral Maxillofac Surg* 1995;53:949-951.
6. Schwimmer AM, Roth SE, Morrison SL: The use of computerized tomography in the diagnosis and management of temporal and infratemporal space abscess. *Oral Surg Oral Med Oral Pathol* 1986;60:207-212.
7. Simon E, Matee M: Post-extraction complications seen at a referral dental clinic in Dar Es Salaam, Tanzania. *Int Dent J* 2001;51:273-276.
8. Flood TP, Braude LS, Jampol LM, Herzog S: Computerized tomography in the management of orbital infections associated with dental disease. *Br J Ophthalmology* 1982;66:269-274.
9. Leu Y S, Lee J C, Chang K C: Submasseteric abscess: report of two cases. *Am J Otolaryngol* 2000;21:281-283.
10. Nishizaki K, Ogawa T, Akagi H, Sato K, Masuda Y: Computed tomographic findings in two cases of cellulitis of the infratemporal fossa with abscess formation. *Ann Otol Rhinol Laryngol* 1998;107:807-809.
11. Gallagher J, Marley J: Infratemporal and submasseteric infection following extraction of a non-infected maxillary third molar. *Br Dent J* 2003;194:307-309.
12. Chong VF, Fan YF: Radiology of the masticator space. *Clin Radiol* 1996;51:457-465.
13. Choung PH, Kim SG: The coronoid process for paranasal augmentation in the correction of midfacial concavity. *Oral Surg Oral Med Oral Pathol Oral Radiol Endod* 2001;91:28-33.
14. Burlibasa C, editor. *Chirurgie Orala si Maxilo-Faciala*. Bucuresti: Medicala; 1999. p.323-329.