

## A case of acute respiratory distress syndrome treated with surfactant and low dose methylprednisolone

Bo Yeon Choi, M.D., Kyong Mo Kim, M.D.  
Jong Seo Yoon, M.D. and Joon Sung Lee, M.D.

*Department of Pediatrics, College of Medicine, The Catholic University of Korea, Seoul, Korea*

The major pathogenesis of acute respiratory distress syndrome (ARDS) is an inflammatory process that results from a diversity of injuries to the body. Due to the various cytokines and vasoactive peptides released from the endothelium, the vascular permeability is increased; the migration of inflammatory cells and the leakage of plasma proteins then occur and edema develops in the alveolus. There is a hypothesis that the impairment of alveolar recruitment in ARDS is caused by a defect of the surfactant system and the resultant increase of alveolar surface tension. This has been studied in pediatric patients in ARDS; after the administration of surfactant, hypoxia, respiratory symptoms and survival chances were improved. To alleviate the major pathogenic mechanism in this disease, that is to say, inflammation of the lung, steroids have been used and studied as another treatment modality for ARDS, and it has been concluded that the administration of low dose methylprednisolone may improve patients' symptoms and survival rates. We report here on a case of a young infant admitted with ARDS, who, after the intratracheal administration of 120 mg/kg surfactant, on PaO<sub>2</sub>/FiO<sub>2</sub> was elevated. Subsequent low doses of methylprednisolone were given, and the symptoms did not recur, and no fibrotic change was shown during the follow-up period of 2 months. (**Korean J Pediatr** 2006;49:455-459)

**Key Words :** Acute respiratory distress syndrome, Surfactant, Methylprednisolone Introduction

### Introduction

Acute respiratory distress syndrome (ARDS) is the pulmonary manifestation of a systemic inflammatory process that is triggered by various events. Because of the various cytokines and vasoactive peptides secreted by the damaged endothelium, the vascular permeability is increased and this results in the migration of neutrophils, eosinophils, macrophages and other inflammatory cells, and also the leakage of protein-rich fluid. Edema consequently develops in the alveolus, and respiratory distress and hypoxia are then induced. Various attempts have recently been reported as conservative treatments for ARDS, but most of these treatments are at the experimental stage, and the mortality still reaches up to 40-60%<sup>1-3)</sup>.

One hypothesis for the pathogenesis of ARDS is that the impairment of alveolar recruitment and a ventilation-perfusion mismatch occur due to a defect of the lung surfactant system, and there have been several reports that supplying surfactant to the ARDS lung may improve the hypoxia and other respiratory symptoms<sup>4,5)</sup>. To alleviate the inflammatory process in the ARDS lung, several attempts have been made to introduce steroid as treatment, and it has recently been concluded that in the late stage of ARDS, low dose methylprednisolone may improve the symptoms and the survival. However, these two studies are still at the experimental stage and they require the larger scale assessment. We report here on a case of a young infant in ARDS who showed improvement of signs and symptoms with the administration of surfactant and steroid.

### Case Report

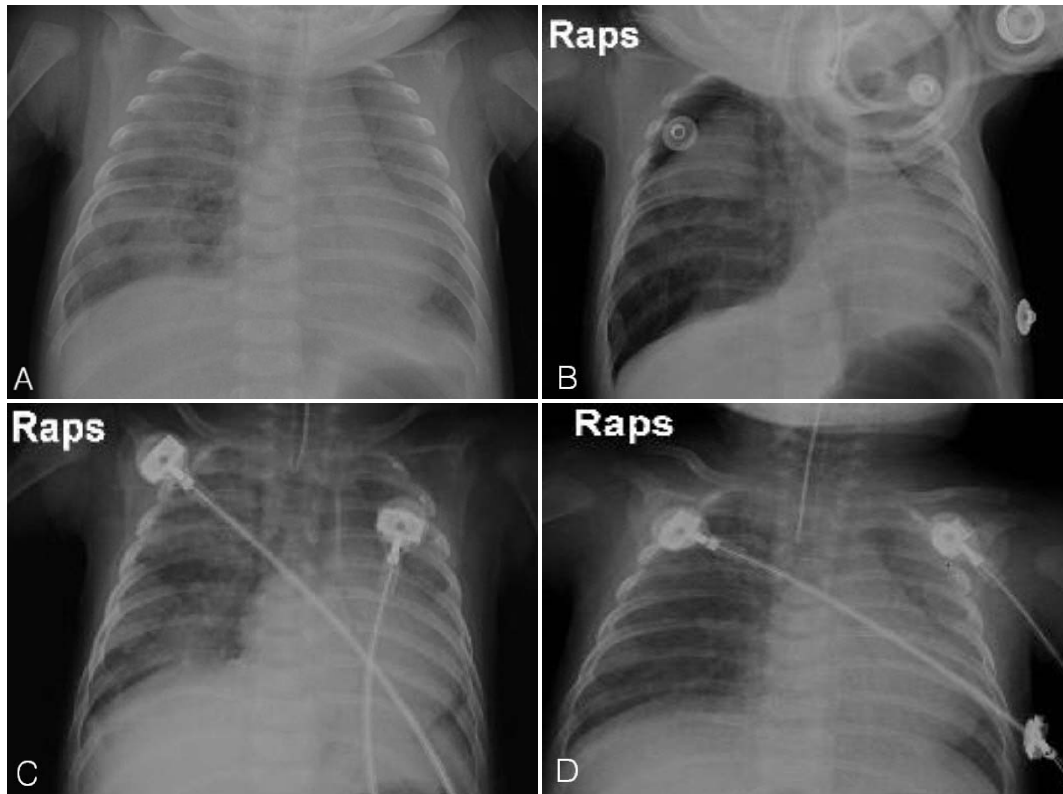
A 61-day-old female infant was admitted to our hospital

접수 : 2005년 9월 29일, 승인 : 2005년 12월 9일  
책임저자 : 이준성, 가톨릭의대 강남성모병원 소아과  
Correspondence : Joon Sung Lee, M.D.  
Tel : 02)590-1472 Fax : 02)537-4544  
E-mail : jslee@catholic.ac.kr

for dyspnea for 3 days. She had cough, sputum, rhinorrhea without fever for a week and intermittent perioral cyanosis that developed a few days later, and symptoms are gradually worsened. She was admitted to a local clinic, but the frequency of cyanosis was increased, and the tachypnea as well as the dyspnea were aggravated; she was then transferred to our hospital. For her birth history, her gestation age was 39 weeks, her birth weight 3.1 kg, it was normal vaginal delivery and the hepatitis B and bacille Calmette-Guerin (BCG) vaccination were administered. Her accurate family history and social history could not be obtained since she was born to an unmarried mother and was being raised in an orphanage. The vital signs at the time of admission were a blood pressure of 80/50 mmHg, pulse rate 160/min, respiratory rate 36/min, body temperature 36.7°C and she had an acutely ill appearance. On the chest examination, the breathing sound was coarse without wheezing or rale, the heart beat was regular without murmur and mild subcostal retraction was detected. The bowel sound was normal and organomegaly was not detected. For the laboratory tests at admission, the complete blood count (CBC) was total white blood cell (WBC) 13,620/mm<sup>3</sup>, neutrophils 43.8%, lymphocytes 48.2%, monocytes 5.6%, eosinophils 2%, hemoglobin (Hb) 9.8 g/dL, hematocrit (Hct) 29.1%, platelets 425,000/mm<sup>3</sup>, ESR 7 mm/hr, C-reactive protein (CRP) 0.46 mg/dL; on the arterial blood gas analysis (ABGA), the pH was 7.45, PaCO<sub>2</sub> 34 mmHg, PaO<sub>2</sub> 44.4 mmHg, HCO<sub>3</sub> 22.4 mmol/L, and SaO<sub>2</sub> 89.8% in room air, and any abnormal result wasn't detected on the blood chemistry and urinalysis. On the immunologic tests, the immunoglobulin (Ig) G was 1,020 mg/dL, Ig A was 26 mg/dL, Ig M was 330 mg/dL, complement C3 was 77 mg/dL, C4 was <5.8 mg/dL, total hemolytic complement activity (CH<sub>50</sub>) was 2.1 U/mL, the percentage of the clusters of differentiation (CD) 19 lymphocytes were 34.1%, CD3 were 24.6%, CD4 were 19.5% and CD8 were 13.4%. On the microbiological study, the serum cytomegalovirus (CMV) Ig G was 1:8,400, CMV Ig M was negative, and *Chlamydia trachomatis* Ig M was negative, and influenza, parainfluenza, adenovirus and respiratory syncytial virus (RSV) were not detected from nasopharyngeal aspirate by immunofluorescent-antibody (IFA) test for the virus culture in Hep-2 cell, and the *Bordetella pertussis* culture from the nasopharyngeal aspirate was negative. The chest PA at the time of admission showed increased patchy or streaky infiltration in both lungs (Fig. 1A).

On the 4<sup>th</sup> day of admission, the dyspnea and hypoxia were aggravated and the patient was transferred to the intensive care unit. She was administered intravenous immunoglobulin (IVIG) 400 mg/kg/d iv for 5 days; however, the symptoms did not improve. Any abnormal results were not detected on the echocardiography and electrocardiogram. On the 6<sup>th</sup> day, pneumothorax developed and then 100% oxygen was supplied and methylprednisolone 1 mg/kg q 6 hr for 3 days IV was started, but her symptoms were not improved and the pneumothorax waxed and waned repeatedly.

On the 12<sup>th</sup> day, the pneumothorax was aggravated (Fig. 1B) and on the ABGA, the pH was 7.26, PaCO<sub>2</sub> 47.9 mmHg, PaO<sub>2</sub> 38.3 mmHg, HCO<sub>3</sub> 21 mmol/L and SaO<sub>2</sub> 64% with 10 L/min oxygen supplied through a head hood; in addition, respiratory acidosis was detected. After thoracentesis and a ventilator was applied with the continuous positive airway pressure (CPAP) mode and positive end expiratory pressure (PEEP) of 5 mmHg (Fig. 1C), 400 mg/kg/d IVIG was administered again for 5 days, but the respiratory distress symptoms continued. No evidence of bronchial anomaly, congenital cyst or congenital lobar emphysema was detected on the chest computed tomography (CT). On the 16<sup>th</sup> day, the ABGA repeatedly showed the evidence of ARDS with in FiO<sub>2</sub>=0.4, pH 7.45, PaCO<sub>2</sub> 42 mmHg, PaO<sub>2</sub> 56 mmHg, HCO<sub>3</sub> 29 mmol/L and SaO<sub>2</sub> 90.6% (PaO<sub>2</sub>/FiO<sub>2</sub>=140). We administered 120 mg/kg surfactant (Newfactan, Yuhan, Seoul, Republic of Korea) intratracheally, and 2 hours later, the ABGA was improved to pH 7.49, PaCO<sub>2</sub> 33.9 mmHg, PaO<sub>2</sub> 65 mmHg, HCO<sub>3</sub> 25 mmol/L and SaO<sub>2</sub> 94.6% (pO<sub>2</sub>/FiO<sub>2</sub>=163), and also the improvement of the bilateral infiltration was shown on the radiological study (Fig. 1D). On the 18<sup>th</sup> day, the surfactant was supplied for the second time, and 2 hours later, the ABGA was improved to pH 7.5, PaCO<sub>2</sub> 30.3 mmHg, PaO<sub>2</sub> 130 mmHg, HCO<sub>3</sub> 25 mmol/L, and SaO<sub>2</sub> 98.9% (PaO<sub>2</sub>/FiO<sub>2</sub>=325). From the 19<sup>th</sup> day, methylprednisolone (Predisol, Reyon Pharmaceutical Co., Seoul, Republic of Korea) treatment was started at 2 mg/kg/d for 14 days, then 1 mg/kg/d for 7 days, 0.5 mg/kg/d for 7 days, 0.25 mg/kg/d for 2 days and finally 0.125 mg/kg/d for 2 days. On the 20<sup>th</sup> day, extubation of endotracheal tube was performed and she was discharged on the 27<sup>th</sup> day. At the follow-up during 2 months, she is doing well without dypnea and no fibrotic change was shown on the follow-up X-ray.



**Fig. 1.** Serial chest PA. **(A)** On admission, streaky and patchy increased densities were seen in both lungs with focal aeration in the right lower medial lungs. **(B)** On day 12, right air trapping and pneumothorax were noted. An endotracheal tube is inserted. **(C)** After thoracentesis, the amount of bilateral pneumothorax was decreased. **(D)** After surfactant was use, there was mild improvement of the haziness of the both lungs.

## Discussion

ARDS was reported for the first time in 1976 by Ashbaugh et al. in 12 adult patients and it was termed as adult respiratory distress syndrome<sup>6)</sup>. It was subsequently found that the symptoms could be developed at all ages, and so it was termed as the current name. In children, this disease is often preceded by sepsis, pneumonia, malignancy, shock, trauma over a wide area, burns and intoxication. The risk groups are premature infants with chronic lung disease who develops respiratory syncytial viral infection or other viral pneumonia, and the risk group for older children are immunocompromised hosts or the cases with underlying diseases such as malignancy<sup>3, 7)</sup>. In ARDS, the onset is characteristically acute and pulmonary edema develops via the increased vascular permeability. On X-ray, the bilateral pulmonary infiltration is specific and symptoms such as tachypnea, hypoxia and rapidly progressing dyspnea are in-

cluded in diagnostic criteria<sup>8)</sup>.

There have been reports of improvement of symptoms and the reduction of mortality with such conservative treatments as controlled mechanical ventilation based on a low tidal volume<sup>2, 9)</sup>, PEEP<sup>10, 11)</sup>, permissive hypercapnea, the use of high frequency ventilator, the inhalation of nitric oxide (NO) gas, the introduction of extracorporeal membrane oxygenation (ECMO), and  $\beta$ -agonist. Nevertheless, the death rate of ARDS is still high for children<sup>1-3, 7)</sup>.

In ARDS patients, the synthesis of lipid surfactant components such as phosphatidylcholine, dipalmitoyl phosphatidylcholines and phosphatidylglycerol and the surfactant proteins SP-A, SP-B, SP-C and SP-D is decreased. In addition, their biochemical properties are changed and the function is inactivated by the leakage of serum proteins<sup>12)</sup>. In addition, the surface tension of the alveolus of ARDS lungs is higher than that of normal lungs. Surfactant acts as an important factor in alveolar recruitment and a defect of the surfactant system is a decisive etiology for devel-

oping ARDS. Thus, supplying surfactant to patients may contribute to the improvement of hypoxia and it can be an important treatment modality. In addition, surfactant has the function of suppressing inflammatory reaction, and it forms a protective system for the lung against bacterial or viral infection<sup>13</sup>. Surfactant can also facilitate the spreading of drugs such as antibiotics and immunoglobulin on the alveolar surface<sup>14</sup>.

Based on such reports, in 1989 the hypothesis was proposed that the administration of surfactant may be effective for respiratory distress syndrome not only in premature infants, but also in adults. It has been reported several times that in ARDS/pneumonia adult patients, the administration of 300-500 mg/kg bovine-extract surfactant improved the oxygenation. It was concluded in many randomized controlled studies that the bolus administration of bovine-extract surfactant at low concentrations can improve oxygenation and patient survival<sup>14</sup>. Yet spraying synthetic surfactant as an aerosol form was ineffective<sup>15</sup>.

In several prospective randomized controlled trials on the use of surfactant in children, it has been reported that oxygenation and the ventilator-associated measurements were improved after the administration of the surfactant. The most recently performed large scale randomized controlled study proved that the administration of 80 mL/m<sup>2</sup> surfactant can improve the oxygenation and reduce patient mortality<sup>5</sup>. With appropriate conversion, this dosage was same as that used in our case (120 mg/kg) and PaO<sub>2</sub>/FiO<sub>2</sub> was increased from 140 to 163 after the first administration of surfactant. But this increment was not sufficiently and the patient remained tachypneic. PaO<sub>2</sub>/FiO<sub>2</sub> was not increased dramatically to 325 until the second booster was administered 48 hours after the first dose. Even in the recent large scale studies, the optimal dosage, timing and the frequency of surfactant have not been established yet. The problems to be solved prior to the introduction of surfactant as a treatment for ARDS in children are not only to determine the optimal time and the dosage of surfactant administration and but also to consider economic aspect. In other words, producing synthetic surfactant that is safe, not expensive, and more resistant to the inactivation mechanism within the alveolus is expected in the future.

Another important treatment modality for ARDS is the administration of low dose steroid. Steroid suppresses the body reaction to inflammation such as fever and tachypnea, it reduces serum epinephrine, CRP and tumor necrosis fac-

tor (TNF)- $\alpha$ , and it stimulates the release of interleukin (IL)-1, sTNF-R, IL-10 and other anti-inflammatory cytokines. Based on such principles, high dose of corticosteroids (30 mg/kg/day) was administered to patients with severe sepsis or ARDS for a short time. However, in the late 1980s, it was established that this treatment failed to improve the survival<sup>16</sup>, and in addition, it has been reported that high dose of corticosteroids may induce sepsis as a result from adrenal insufficiency<sup>17</sup>, and systemic inflammation can be caused by glucocorticoid resistance in the peripheral tissues<sup>18</sup>. Therefore, high dose steroid treatment was discontinued.

Low dose of methylprednisolone was reported to reduce the aminoterminal propeptide of procollagen type I and type III in the serum and bronchoalveolar lavage fluid from the ARDS lung<sup>19</sup>. In the late stage of ARDS or sepsis, the use of low dose methylprednisolone (1-8 mg/kg/day) for longer times (3-150 days) was shown to improve the survival. Such an effect was proven in 1998 in the randomized controlled trial performed by Meduri et al<sup>20</sup>. However, the effect of supplemental glucocorticoid treatment during the early stage of ARDS has not yet been assessed. In Meduri's study, they reported that after the administration of 2 mg/kg/day methylprednisolone for 2 weeks, then 1 mg/kg/day for one week, 0.5 g/kg/day for one week, 0.25 mg/kg/day for 2 days and 0.125 mg/kg/day for 2 days, the hospital stay in the intensive care unit was shortened and the mortality was reduced. The identical protocol was applied in our case study, and no specific complication has appeared in our patient during this administrations. She improved easily and no fibrotic change was shown on the follow-up X-rays in 2 months - period after discharge. However, for children, a large scale clinical trial for ARDS has not been performed, so the safety and efficacy of this treatment are unproven. Therefore, prior to its application, it may be essential to perform a study for children.

**한글 요약**

**포면활성제와 저용량 methylprednisolone으로 치료하였던 급성 호흡 곤란 증후군 1례**

가톨릭대학교 의과대학 소아과학교실

최보연 · 김경모 · 윤중서 · 이준성

급성 호흡곤란 증후군은 다양하게 유발되는 신체의 손상에 대

한 방어기전으로 염증반응이 유발되어 생성되는 폐포 내의 부종으로 인해 호흡곤란과 저산소증이 초래되는 질환이다. 이 질환에서 표면활성제의 결핍과 폐포 표면 장력의 증가로 인해 폐포 동원에 장애가 오는 것이 결정적인 병인이고 표면활성제의 보충이 저산소증을 개선시킴으로써 중요한 치료 방안이 될 수 있다는 가설이 제시되었고 실제로 소아 환자들에서 저산소증을 개선시키고 증상의 호전을 얻었던 보고들이 여러 차례 있었다. 또한 이 질환의 주요 병인인 폐에서의 염증 반응에 주안점을 두고 스테로이드를 투여해 본 연구들에서 저용량 methylprednisolone으로 증상이 호전되고 생존율이 향상되었다는 결론을 얻은 바 있으나 두 치료 모두 ARDS에서 일반적인 적용은 확립되어 있지 않은 실정이다. 저자들은 급성 호흡곤란 증후군으로 진단받은 61일된 소아가 인공 호흡기 등의 보존적인 치료에 반응하지 않고 지속적으로 증상의 악화를 보이다가 표면활성제 120 mg/kg를 기도 내로 주입한 후 호흡곤란 증상과 저산소증 호전되고 PaO<sub>2</sub>/FiO<sub>2</sub> 상승, 이후 저용량 methylprednisolone을 투여(2 mg/kg 14일간, 1 mg/kg 7일간, 0.5 mg/kg 7일간, 0.25 mg/kg 2일간, 0.125 mg/kg/d 2일간)한 후 2개월간의 추적 관찰에서 증상의 재발없고 방사선학적 검사상 섬유화 등의 합병증을 보이지 않았던 1례를 보고하는 바이다.

References

- 1) Zilberberg MD, Epstein SK. Acute lung injury in the medical ICU: co-morbid conditions, age, etiology, and hospital outcome. *Am J Respir Crit Care Med* 1998;157:1159-64.
- 2) Kallet RH, Jasmer RM, Pittet JF, Tang JF, Campbell AR, Dicker R, et al. Clinical implementation of the ARDS network protocol is associated with reduced hospital mortality compared with historical controls. *Crit Care Med* 2005;33:925-9.
- 3) MacCallum NS, Evans TW. Epidemiology of acute lung injury. *Curr Opin Crit Care* 2005;11:43-9.
- 4) Gregory TJ, Steinberg KP, Spragg R, Gadek JE, Hyers TM, Longmore WJ, et al. Bovine surfactant therapy for patients with acute respiratory distress syndrome. *Am J Respir Crit Care Med* 1997;155:1309-15.
- 5) Willson DF, Thomas NJ, Markovitz BP, Bauman LA, DiCarlo JV, Pon S, et al. Effect of exogenous surfactant (carfactant) in pediatric acute lung injury: a randomized controlled trial. *JAMA* 2005;293:470-6.
- 6) Ashbaugh DG, Bigelow DB, Petty TL, Levine BE. Acute respiratory distress in adults. *Lancet* 1967;2:319-23.
- 7) Ware LB, Matthay MA. The acute respiratory distress syndrome. *New Engl J Med* 2000;342:1334-49.
- 8) Bernard GR, Artigas KL, Carlet J, Falke K, Hudson L,

- Lamy M, et al. Report of the American-European Consensus conference on acute respiratory distress syndrome: definition, mechanism, relevant outcomes, and clinical trial coordination. Consensus Committee. *J Crit Care* 1994;9:72-81.
- 9) The Acute Respiratory Distress Syndrome Network. Ventilation with low tidal volume as compared with traditional tidal volume. *N Engl J Med* 2000;342:1301-8.
- 10) Falke KJ, Pontoppidan H, Kumar A, Leith DE, Geffin B, Laver MB. Ventilation with end-expiratory pressure in acute lung disease. *J Clin Invest* 1972;51:2315-23.
- 11) Gattinoni L, Presenti A, Bombino M, Baglioni S, Rivolta M, Rossi F, et al. Relationships between lung computed tomographic density, gas exchange, and PEEP in acute respiratory failure. *Anesthesiology* 1988;69:824-32.
- 12) Gunther A, Ruppert C, Schmidt R, Markart P, Grimminger F, Walmrath D, et al. Surfactant alteration and replacement in acute respiratory distress syndrome. *Respir Res* 2001;2:353-64.
- 13) Wright JR. Immunomodulatory functions of surfactant. *Physiol Rev* 1997;77:931-62.
- 14) Herting E, Gan X, Rauprich P, Jarstrand C, Robertson B. Combined treatment with surfactant and specific immunoglobulin reduces bacterial proliferation in experimental neonatal group B streptococcal pneumonia. *Am J Respir Crit Care Med* 1999;159:1862-7.
- 15) Anzueto A, Baughman R, Guntupalli KK, Weg JG, Wiedermann HP, Raventos AA, et al. Aerosolized surfactants in adults with sepsis induced acute respiratory distress syndrome. *N Engl J Med* 1996;334:1417-21.
- 16) Luce JM, Montgomery AB, Markers JD, Turner J, Metz CA, Murray JF. Ineffectiveness of high-dose methylprednisolone in preventing parenchymal lung injury and improving mortality in patients with septic shock. *Am Rev Respir Dis* 1988;138:62-8.
- 17) Rothwell PM, Udwardia ZF, Lawler PG. Cortisol response to corticotropin and survival in septic shock. *Lancet* 1991;337:582-3.
- 18) Molijn GJ, Spek JJ, van Uffelen JC, de Jong FH, Brinkmann AO, Bruining HA, et al. Differential adaptation of glucocorticoid sensitivity of peripheral blood mononuclear leukocytes in patients with sepsis or septic shock. *J Clin Endocrinol Metab* 1995;80:1799-803.
- 19) Meduri GU, Tolley EA, Chinn A, Stentz F, Postlethwaite A. Procollagen types I and III aminoterminal propeptide levels during acute respiratory distress syndrome and in response to methylprednisolone treatment. *Am J Respir Crit Care Med* 1998;158:1432-41.
- 20) Meduri GU, Headley AS, Golden E, Carson SJ, Umberger RA, Kelson T, et al. Effect of prolonged methylprednisolone therapy in unresolving acute respiratory distress syndrome: a randomized controlled trial. *JAMA* 1998;280:159-65.