

A case of recurrent hepatoblastoma : lung, heart and brain metastasis

Sun Mi Park, M.D., Byung Kyu Choe, M.D., Yeo Hyang Kim, M.D.
Heung Sik Kim, M.D., Tae Chan Kwon, M.D. and Hee Jung Lee, M.D.*

Department of Pediatrics and Radiology, Keimyung University School of Medicine, Daegu, Korea*

Hepatoblastoma is a hepatic tumor predominantly occurring in children. The usual site of metastasis is the lung. There are only several reports worldwide on the distant metastasis of hepatoblastoma to the central nervous system in children. Only one reported case showed survival of a patient after multiple resections of a recurrent brain lesion. Involvement of the cardiovascular system has been reported in the medical literature. Lesions almost always involve the right-side of the heart. We report a case of recurrent hepatoblastoma at multiple sites, including brain, left atrium of the heart and lung in a 6-year-old girl who was partially treated in the past at the age of 1.5 years; the patient had been event-free for four and a half years. (*Korean J Pediatr* 2006;49:691-695)

Key Words : Hepatoblastoma, Metastasis, Left atrium, Brain

Introduction

Hepatoblastoma is a primary tumor of the liver occurring predominantly in children¹⁾. The usual site of metastasis in hepatoblastoma is the lung. Metastasis of hepatoblastoma to brain and/or heart is quite rarely reported and we could not find a prior case of hepatoblastoma invading the left atrium of the heart. We report a case of hepatoblastoma in a 6-year-old orphan girl who had recurrent disease at multiple sites including brain, left atrium of the heart and lung after the initial treatment 4 years earlier. Preoperative chemotherapy and tumor resection was performed initially; however, postoperative chemotherapy was refused by the legal guardian of the child. She remained alive after the cessation of the treatment for over 6 months.

Case Report

A 6-year-old orphan girl was admitted for the evaluation of an abnormal mass-like lesion noted on a plain

chest film. The patient had coughing for about 10 days, and had no improvement of symptoms despite treatment at a private clinic. A chest X-ray revealed a mass-like lesion occupying the entire right lower lung field (Fig. 1A). The patient was immediately transferred to Keimyung University Dongsan Medical Center. On admission, she was pale with ill-looking appearance. Her body temperature was 37.4 °C, pulse rate was 80/min, and respiratory rate was 36/min. Her body weight was 18 kg (10-25th percentile) and her height was 108 cm (3-10th percentile). Breathing sound was markedly decreased on right lower chest. There was no palpable mass on her abdomen. She had a history of treatment of hepatoblastoma diagnosed about four years prior to presentation. At that time, four cycles of preoperative chemotherapy consisting of cisplatin, 5-fluorouracil, and vincristine were administered and right lobectomy of the liver was performed. Alpha fetoprotein level was decreased from over 65,000 ng/mL on admission to 6,810 ng/mL after chemotherapy. The patient missed the final 2 cycles of chemotherapy. The patient returned to our hospital with another problem one year after the completion of the surgery, but again, the remaining two cycles of chemotherapy was refused. Alpha-fetoprotein was measured at that point and was found to be normal. The patient remained stable for the following 4 years, until cough developed and a large mass was identified in the right chest on standard

접수 : 2005년 11월 14일, 승인 : 2006년 1월 20일

책임저자 : 김홍식, 계명대 동산의료원 소아과

Correspondence : Heung Sik Kim, M.D.

Tel : 053)250-7516 Fax : 053)250-7783

E-mail : kimhs@dsmc.or.kr

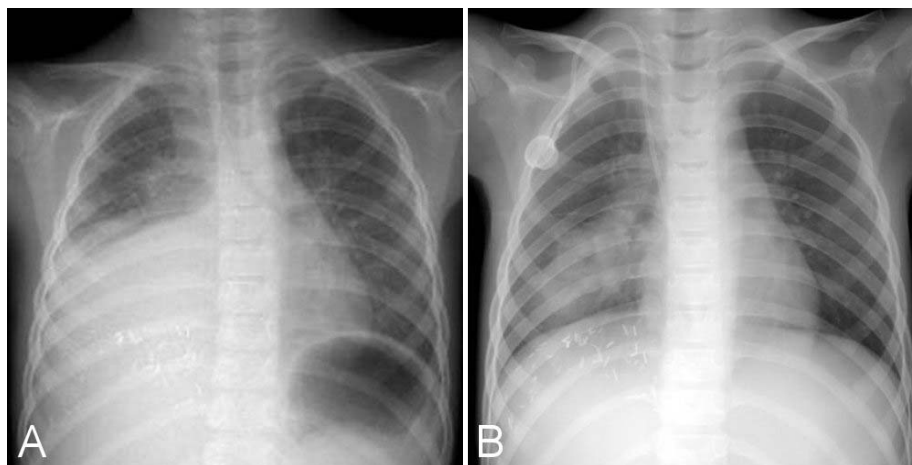


Fig. 1. Chest PA on admission revealed a large mass-like lesion in the lower half of right lung (A). Follow up chest PA taken after 4th cycle of chemotherapy showed improvement (B).

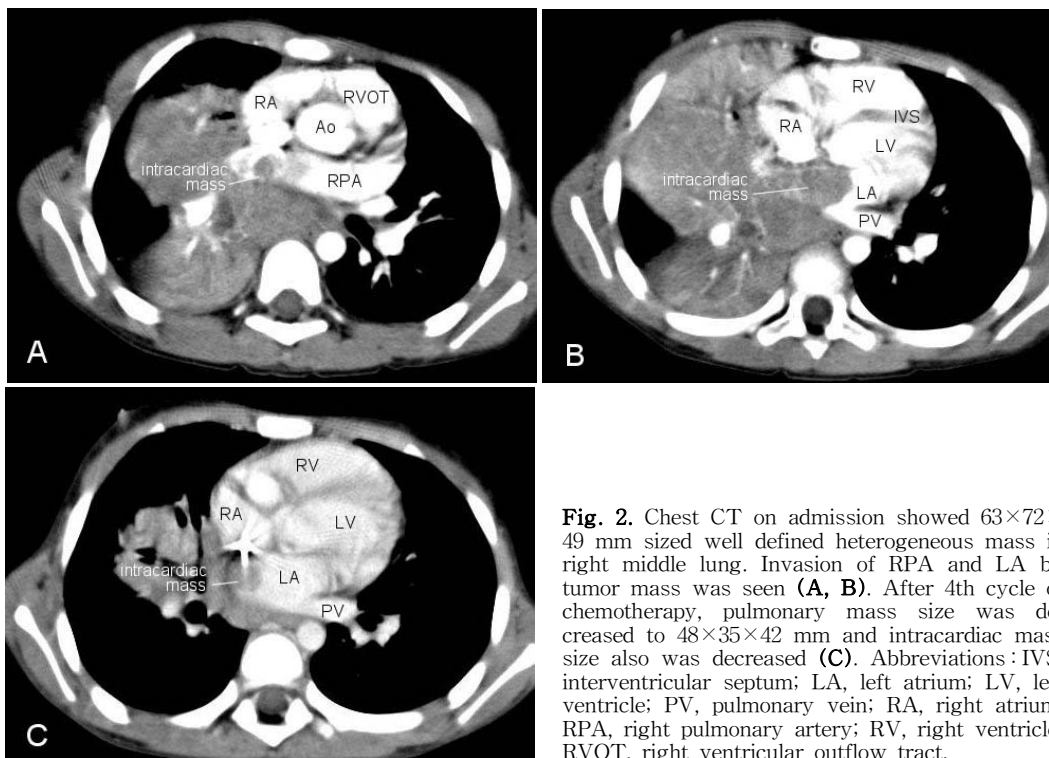


Fig. 2. Chest CT on admission showed 63×72×49 mm sized well defined heterogeneous mass in right middle lung. Invasion of RPA and LA by tumor mass was seen (A, B). After 4th cycle of chemotherapy, pulmonary mass size was decreased to 48×35×42 mm and intracardiac mass size also was decreased (C). Abbreviations: IVS, interventricular septum; LA, left atrium; LV, left ventricle; PV, pulmonary vein; RA, right atrium; RPA, right pulmonary artery; RV, right ventricle; RVOT, right ventricular outflow tract.

X-ray evaluation. A recurrence of the hepatoblastoma was immediately suspected. A chest CT was performed and showed a well defined heterogeneous mass measuring 63×72×49 mm in the right middle lobe of the lung with direct invasion into the left atrium through the right pulmonary artery (Fig. 2A, 2B). There was no abnormal lesion identified in the liver. The Alpha fetoprotein was elevated over 65,000 ng/mL. A needle aspiration of the mass revealed an

epithelial histology consistent with the diagnosis of hepatoblastoma; which was different from the prior report that showed a mixed type of tumor (both epithelial and mesenchymal components). The results of the whole body bone scan and the bone marrow aspiration were unremarkable. Chemotherapy was started with CCG 8881B protocol consisting of cisplatin and continuous infusion of adriamycin. An echocardiogram was performed and the left ventricular

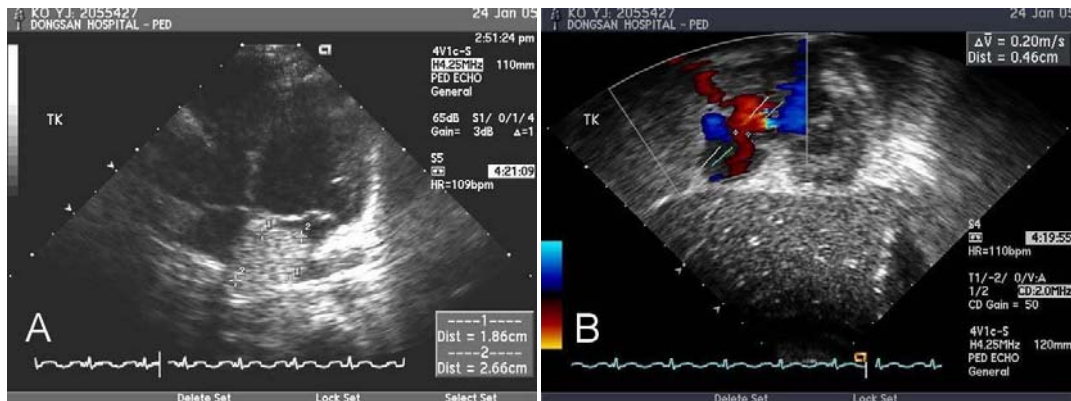


Fig. 3. Echocardiogram on admission showed left atrial mass of 2.6×1.8 cm (A) and atrial septal defect of 4.6 mm (B).

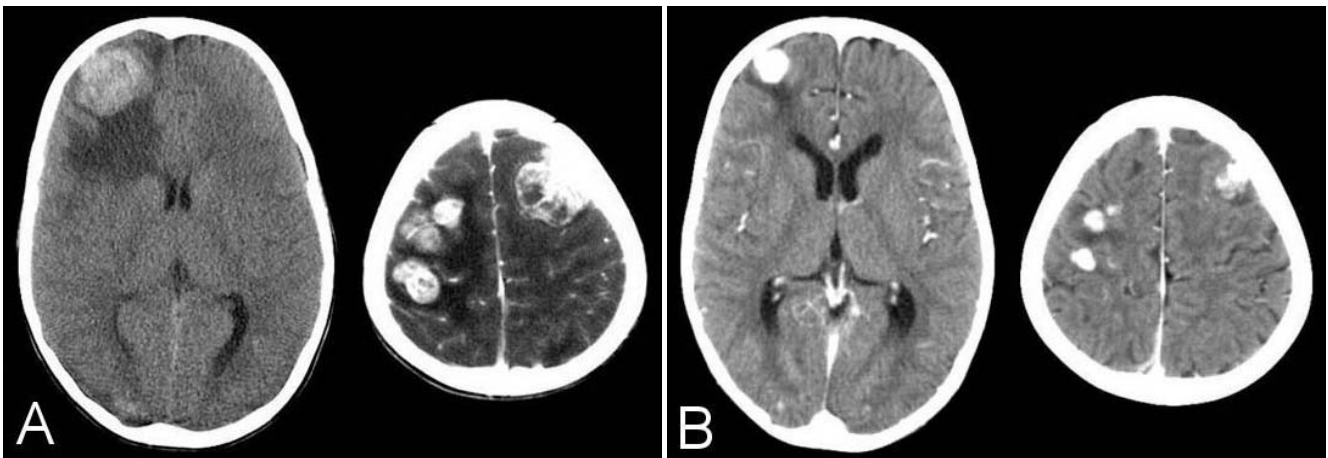


Fig. 4. Brain CT on 6th day of the chemotherapy showed multiple, variable sized heterogeneous, highly enhancing masses in the gray-white matter junction sites of both cerebral hemispheres (A). Follow up brain CT after 4th cycle of chemotherapy showed decreased size and numbers of multiple variable sized hemorrhagic metastases in both cerebral hemispheres (B).

function was found to be normal. An atrial septal defect of 4.6 mm and a mass measuring 2.6×1.8 cm in the left atrium were identified (Fig. 3). Surgical biopsy of the intracardiac mass was not performed. At the 6th day of chemotherapy, the patient had 2 episodes of generalized tonic-clonic convulsions each lasting less than 1 minute. A brain CT performed immediately revealed multiple heterogeneous lesions bilaterally in each hemisphere (Fig. 4A). There were no further seizures, and the EEG remained normal. The patient underwent four cycles of chemotherapy with febrile neutropenia and mucositis but without serious complications. The serum alpha-fetoprotein gradually decreased from over 60,500 ng/mL at the start of chemotherapy to 28,000 ng/mL at the completion of the 4th cycle. Follow up chest PA (Fig. 1B) and chest CT (Fig. 2C) showed a decreased size of the mass in the lung mea-

suring $48 \times 35 \times 42$ mm. A small residual mass but markedly decreased size measuring 1×1 cm, in the left atrium was observed in the follow up chest CT (Fig. 2C); echocardiogram also showed decreased size of the intracardiac mass. The brain CT, after the 4th cycle of chemotherapy, showed decreased size and number of multiple heterogeneous metastases in both cerebral hemispheres (Fig. 4B). According to the treatment protocol, surgical resection of the lung mass was the next step. However, at that point, the legal guardian of the child declined further treatment. The patient remained alive in fair condition 6 months after the interruption of the treatment.

Discussion

The usual site of metastasis of hepatoblastoma is the

lung. Lung metastases identified on diagnosis is one of the most reliable prognostic indicators of an unfavorable outcome for patients diagnosed with hepatoblastoma²⁾. Extrapulmonary metastatic sites in patients with hepatoblastoma, including brain as well as abdomen and bone, are uncommon. The prognosis for children with hepatoblastoma with distant metastasis is poor at diagnosis and even worse with relapse³⁾. In cases with multiple site metastases, surgical treatment of pulmonary lesions has not been effective⁴⁾. Brain metastases are rare in children with hepatoblastoma; there are only several case reports worldwide. There was a case report of a 12-month-old male who presented with a large liver mass and a pulmonary nodule⁵⁾. The boy underwent chemotherapy and resection of the tumor with poor response. He died shortly after development of multiple intracranial hemorrhagic masses. There are some other reports of brain metastasis of hepatoblastoma^{3, 4, 6-9)}. There is only one case with long-term survival³⁾. The patient was a 17-month-old girl who had pulmonary and brain metastasis of hepatoblastoma. Multiple surgical resections combined with radiotherapy and chemotherapy resulted in event-free survival over 10 years. The authors of the article attributed prolonged survival to the absence of primary tumor relapse, and an aggressive approach to therapy. The outcome of a patient presented by Miyagi et al⁷⁾ was not reported. The remaining patients described in the literatures have all died^{4, 6-8)}. The age distribution of reported cases spanned from the newborn period⁶⁾ to 10 years of age⁴⁾. The number of brain metastases did not seem to affect the outcome. Two out of three patients with solitary brain metastases died^{8, 9)}.

Malignant hepatic tumors can invade the cardiovascular system. Wang et al¹⁰⁾ reported in their series that two of five patients with hepatoblastoma and one of seven patients with hepatocellular carcinoma had intracardiac metastasis. All patients with cardiac involvement had pulmonary metastases, as in our patient. However, all previously reported cases showed involvement of the right atrium; this differed from our case with invasion of tumor into the left atrium of the heart. Although we couldn't confirm the histologic diagnosis of the intracardiac mass, we thought metastatic hepatoblastoma was the most probable explanation about the mass because the size of the mass was reduced after the chemotherapy.

Histologic diagnosis was different when present samples were compared to previous histologic diagnosis. However,

considering the small amount of the sample obtained with the needle aspiration, it seemed reasonable to conclude that the findings represented a recurrence of the original hepatoblastoma.

Our patient lived in an orphanage, and the initial treatment was interrupted for no apparent reason. Although the patient was disease-free for several years, we thought the interruption of the planned therapy might be a contributing factor to disease recurrence. In addition, there was lack of monitoring of the alpha-fetoprotein levels. If the patient had been followed for the serum alpha-fetoprotein more frequently, the recurrence might have been detected earlier.

Although the high-dose chemotherapy followed by autologous stem cell rescue could be an option to treat this relapsed case as Nishimura et al¹¹⁾ have reported the efficacy of such modality, we chose a conventional approach because the financial considerations limited access to other approaches. There was partial response to conventional therapy until the interruption of the treatment this time.

한 글 요약

폐, 심장, 뇌에 전이되어 재발된 간모세포종 1례

계명대학교 의과대학 소아과학교실, 방사선과학교실*

박선미 · 최병규 · 김여향 · 김홍식 · 권태찬 · 이희정*

간모세포종은 15세 이하 연령에서 발생하는 간암 중 가장 흔하며 대부분 5세 미만에 발병된다. 진단시 폐전이가 동반되는 경우가 약 10%가 되나 심장이나 중추신경계에 전이된 보고는 상당히 드물며 예후도 좋지 못한 것으로 알려져 있다. 저자들은 약 4년 반 전 간모세포종으로 진단 받고 항암화학요법과 수술적 절제 후 추가 항암치료를 마치지 않고 추적관찰이 소실되었으나 그동안 무병 상태로 지내오다 폐와 좌측 심장, 중추신경계에 다발적으로 재발되어 다시 항암화학요법으로 치료를 시작한 후 호전을 보였으나 사정상 치료가 중단되어 있는 6세 여아에 대해 보고하는 바이다.

References

- 1) Bellani FF, Massimino M. Liver tumors in childhood: epidemiology and clinics. *J Surg Oncol* 1993;3:119-21
- 2) Brown J, Perilongo G, Shafford E, Keeling J, Pritchard J, Brock P, et al. Pretreatment prognostic factors for children with hepatoblastoma—results from the International Society of Paediatric Oncology (SIOP) Study SIOPEL 1. *Eur J Cancer* 2000;36:1418-25.

- 3) Robertson PL, Muraszko KM, Axtell RA. Hepatoblastoma metastasis to brain : prolonged survival after multiple surgical resections of a solitary brain lesion. *J Pediatr Hematol Oncol* 1997;19:168-71.
- 4) Feusner JH, Krailo MD, Haas JE, Campbell JR, Lloyd DA, Ablin AR. Treatment of pulmonary metastases of initial stage I hepatoblastoma in childhood. *Cancer* 1993;71:859-64.
- 5) Begemann M, Trippett TM, Lis E, Antunes NL. Brain metastases in hepatoblastoma. *Pediatr Neurol* 2004;30:295-7.
- 6) Endo EG, Walton DS, Albert DM. Neonatal hepatoblastoma metastatic to the choroid and iris. *Arch Ophthalmol* 1996; 114:757-61.
- 7) Miyagi J, Kobayashi S, Kojo N, Watanabe M, Kuramoto S, Hirose F. Brain metastasis of hepatoblastoma : A case report and review of literature. *No Shinkei Geta* 1984;12:753-8.
- 8) Nagle SB, Deolekar MV, Dhamnaskar P. Hepatoblastoma with complete regeneration of liver and with metastasis to lungs and brain within six months after partial hepatectomy : A case report. *Indian J Pathol Microbiol* 1996;39:147-9.
- 9) Curless RG, Toledano SR, Ragheb J, Cleveland WW, Falcone S. Hematogenous brain metastasis in children. *Pediatr Neurol* 2002;26:219-21.
- 10) Wang JN, Chen JS, Chuang HY, Yang YJ, Chang KC, Wu JM. Invasion of the cardiovascular system in childhood malignant hepatic tumors. *J Pediatr Hematol Oncol* 2002;24: 436-9.
- 11) Nishimura S, Sato T, Fujita N, Yamaoka H, Hiyama E, Yokoyama T, et al. High-dose chemotherapy in children with metastatic hepatoblastoma. *Pediatr Int* 2002;44:300-5.