

## Congenital central hypoventilation syndrome combined with Hirschsprung disease diagnosed in the neonatal period

Jin Hyun Choi, M.D., Jin Hee Oh, M.D., Jong-Hyun Kim, M.D.  
Dae Kyun Koh, M.D. and Seung-Chul Hong, M.D.\*

*Departments of Pediatrics and Psychiatry\*, College of Medicine,  
The Catholic University of Korea, Seoul, Korea*

Congenital central hypoventilation syndrome (CCHS) or Ondine's curse is a very rare sleep disorder that is the result of a congenital failure of the autonomic control of ventilation caused by insensitivity of the chemoreceptor to hypercapnea during sleep. Gastrointestinal motility disorders, particularly a congenital megacolon (Hirschsprung disease) is often combined with CCHS. This combination can be explained by a defect in the migration of neuronal cells from the neural crest (neurocristopathy) during the intrauterine period. A diagnosis of CCHS is made by confirming the failure of adequate ventilation in response to hypercapnea and hypoxia during sleep and the exclusion of other diseases. Young infants frequently show atypical clinical courses, and their conditions are frequently complicated with the long-term sequela of hypoxemic episodes. Therefore, a high index of suspicion and active treatment with mechanical ventilation are important for reducing recurrent hypoxemic episodes in the neonatal period. This paper reports the follow up of a case of CCHS in a neonate who showed frequent intractable apnea and cyanosis and was given artificial mechanical ventilation during sleep. (**Korean J Pediatr** 2006;49:446-450)

**Key Words :** Congenital, Central, Hypoventilation, Neonate, Polysomnography

### Introduction

Congenital central hypoventilation syndrome (CCHS) or Ondine's curse is a very rare non-progressive congenital sleep disorder involving the failure of the autonomic control of breathing, which causes life-threatening hypoxic episodes beginning in the neonatal period. The first case of CCHS was reported by Mellins et al. in 1970<sup>1)</sup>. Since then, a few cases have been reported where most of all were fatal. Gastrointestinal motility disorders, particularly a congenital megacolon or Hirschsprung disease (HD) is often combined with CCHS. This pathological combination was reported first by Haddad et al. in 1978 and is called Haddad syndrome<sup>2)</sup>. CCHS with HD is considered to be a form of neurocristopathy caused by a defect in the migration of

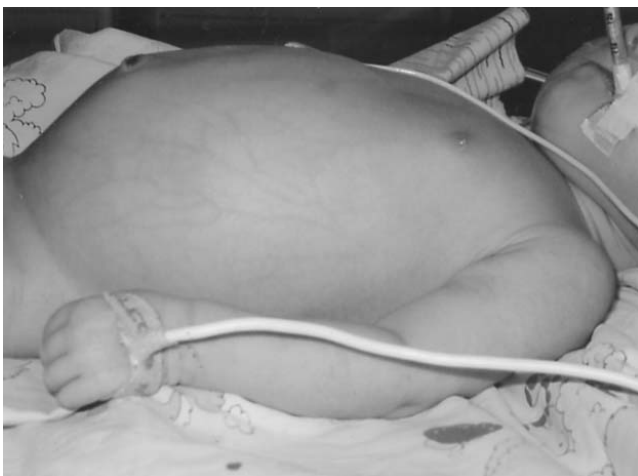ganglioneuronal cells from the neural crest. Ahn et al. reported the first case in Korea in 1993 and there have been no other reports until now<sup>3)</sup>. This very rare syndrome of CCHS has a broad spectrum of clinical features ranging from a mild form of apnea during deep sleep to a severe form causing apnea also on arousal. A diagnosis is generally made mainly by exclusion i.e. ruling out other pulmonary, cardiac, metabolic or neurological causes of the hypoventilation, and by showing hypoventilation despite hypercapnea or hypoxia with polysomnography. The treatment depends only on respiratory care with life-long assisted mechanical ventilation, and the prognosis depends on preventing the hypoxic insults with adequate ventilatory support and management of the complications. Early diagnosis and therapeutic intervention to prevent a hypoxic insult using a mechanical ventilation system is very important for the survival of a CCHS patient. We report a case of CCHS with HD diagnosed in the neonatal period, who required adjuvant synchronized intermittent mandatory ventilation (SIMV) during sleep, and was followed up at home for 9

접수 : 2005년 10월 12일, 승인 : 2005년 11월 18일  
책임저자 : 오진희, 가톨릭대학교 의과대학 소아과학교실  
Correspondence : Jin Hee Oh, M.D.  
Tel : 031)249-7320 Fax : 031)257-9111  
E-mail : Jeany@catholic.ac.kr

months.

### Case Report

A female neonate was transferred to our hospital on the second day after birth with complaints of frequent apneic and cyanotic episodes. The patient was born as a full term baby via a normal vaginal delivery and weighed 2,930 g. Fetal monitoring showed no perinatal history of dystocia or antenatal fetal distress. The Apgar scores were 8 at 1 minute after birth and 9 at 5 minutes. There was no maternal history of polyhydramnios, premature rupture of the amniotic membrane or meconium staining. There was no family history of congenital anomalies, neuromuscular disorders or maternal exposure to drugs during pregnancy. The physical examination showed that the patient had a mild abdominal distension (Fig. 1). The body temperature was 36.8°C, heart rate 150/min, respiration rate 30/min, body weight 2,930 grams (10–25 percentile), height 50 cm (50–75 percentile), and head circumference 30 cm (0–3 percentile). Auscultations of the patient did not reveal any murmur or abnormal breathing sounds. The anterior fontanel was not bulged and palpated soft. No abnormal mass or organomegaly were suspected upon the palpation of the abdomen. The neurological examination revealed that the patient had a normal symmetric Moro reflex. The initial laboratory findings showed the following: Hemoglobin 13.1 g/dL, WBC 31,630/mm<sup>3</sup> (segment neutrophils 60%, lymphocytes 36% and meta-myelocytes 3%), platelets 269,000/mm<sup>3</sup>. The blood chemistry results were within the normal

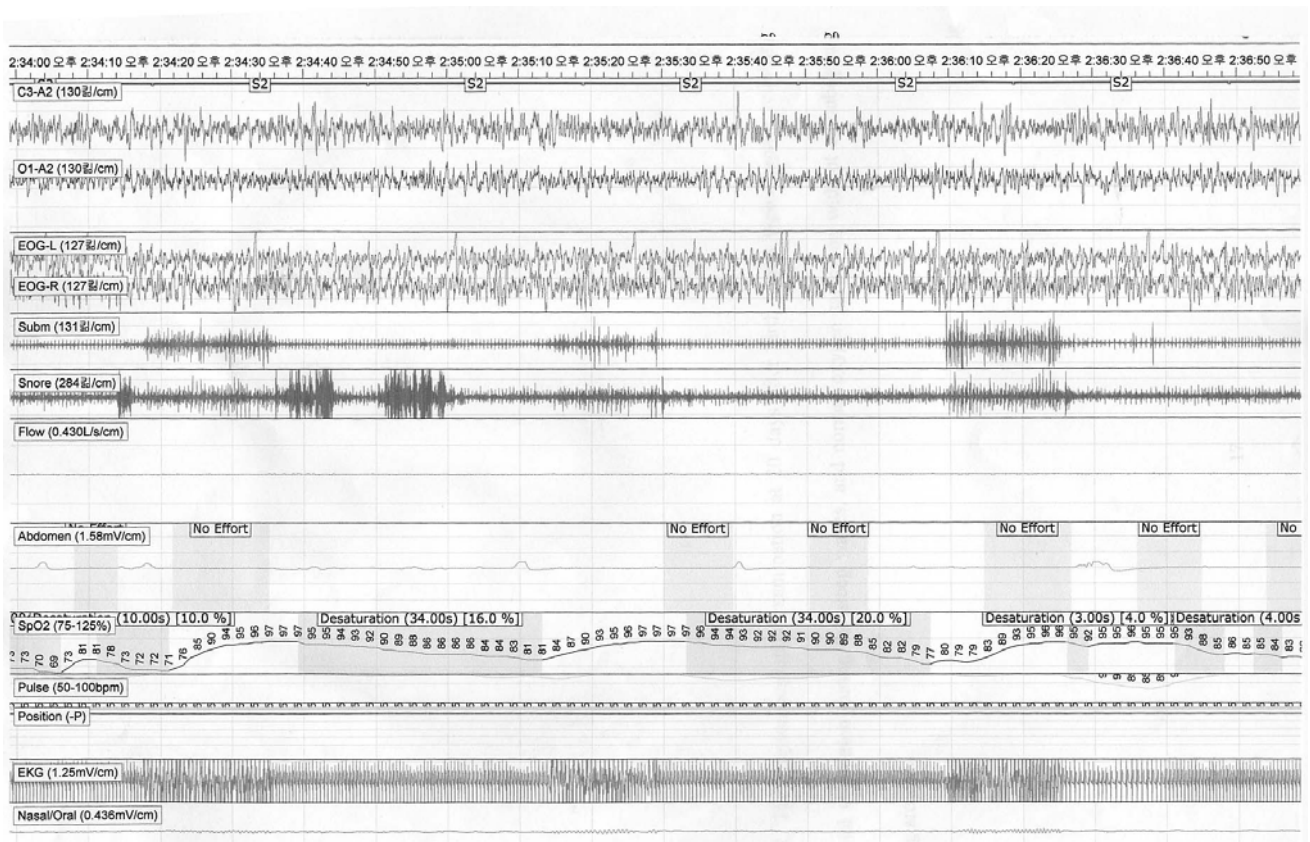


**Fig. 1.** The patient's general appearance shows a markedly distended abdomen.

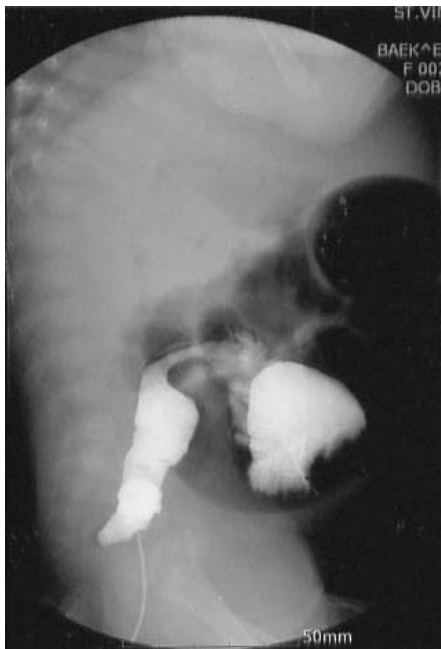
limits and the serum C-reactive protein (CRP) was negative. On the third day of admission, the WBC counts were 15,410/mm<sup>3</sup>. The result of the neonatal metabolic screening test was normal. The roentgenography and computed tomographic scan of the chest showed non-specific findings. She was examined by echocardiography, which ruled out congenital heart diseases that might have caused the cyanosis. Magnetic resonance imaging (MRI) of the brain also showed non-specific findings. The patient did not suffer a neonatal seizure but the frequent apneic and cyanotic episodes recurred, which required mechanical ventilation. With time, it was found that the apnea and cyanosis developed only while the patient was asleep, and few symptoms were observed while the patient was awake. Despite these efforts over a one-month period, weaning of the mechanical ventilation was impossible due to the cyanosis and hypercapnea during sleep. EEG showed infrequent spikes but the apnea during sleep was not improved by anticonvulsants. Therefore, the patient underwent polysomnography, which showed typical hypoventilation (hypercapnia and hypoxia) coincident with the fasting asleep confirming the diagnosis of CCHS (Fig. 2). The other abnormal clinical manifestations of an abdominal distension did not improve for several months, and she underwent a barium enema study, which revealed a congenital megacolon (Fig. 3). The suction biopsy of the descending colon was performed under general anesthesia and the pathological findings showed a congenital megacolon (Hirschsprung disease). Consequently, the patient received a colostomy. The patient required a tracheostomy as well as adjuvant synchronized intermittent mandatory ventilation (SIMV) during sleep. She needed a tube feeding due to swallowing difficulties and six months later bottle feeding was possible. She was discharged at 6 months after birth and is now at home depending on SIMV during sleep, and is currently undergoing physical therapy. Nine months after birth, the patient was able to control her neck and roll over but shows a delay in sitting. However, weaning of the mechanical ventilator during the awakening period is now possible (Fig. 4).

### Discussion

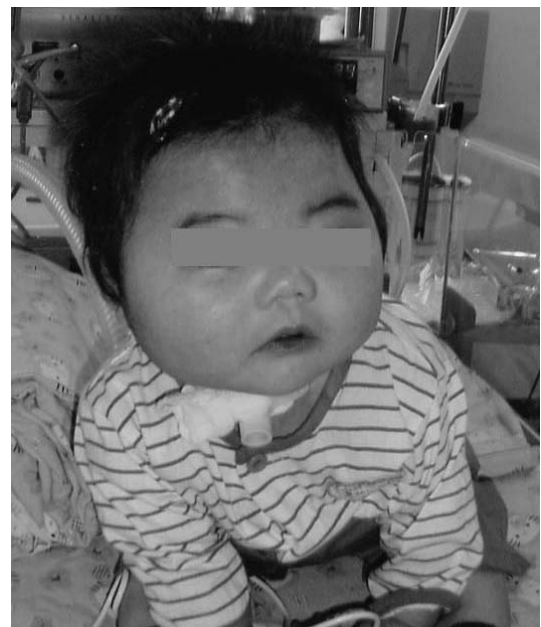The patients with CCHS have a decreased sensitivity to hypercapnea and hypoxia with the symptoms usually developing during sleep. However, symptoms can present while awake<sup>4, 5)</sup>. Patients do not exhibit signs of respiratory dis-



**Fig. 2.** The polysomnography examination at 20 days after birth shows typical apnea requiring artificial ventilation during the sleep waves, and normal oxygen saturation without ambubagging during arousal.



**Fig. 3.** The barium enema show segmental narrowing and dilatation of the sigmoid and descending colon that is compatible with a congenital mega colon.



**Fig. 4.** Follow up photos of the patient at 8 months of age shows the ability to control her neck, to sit by herself without assistance and to breathe without mechanical ventilator assistance while awake.

truss when challenged with hypercarbia or hypoxia. Ondine's curse, which is the other name for CCHS is derived from the Greek myth, in which Poseidon placed a curse upon a knight to lose his automatic body function unless he is conscious and to forget to breathe while he was asleep. The symptoms are aggravated during deep sleep and non-rapid eye movement (NREM) sleep, and is less likely while awake or during rapid eye movement (REM) sleep<sup>6)</sup>. One infant reported underwent a near miss for sudden infant death syndrome and became significantly symptomatic after the establishment of delta (stage 3-4 non-rapid eye movement) sleep, which normally develops between 2 and 4 months of age<sup>7)</sup>. The pathophysiology of CCHS is unclear. Although it had been explained by a defect in the central chemoreceptor before, a component of both the central and peripheral chemoreception appear to be partially intact in CCHS causing the respiratory rates to increase during hypoxia and decrease during hyperoxia<sup>5)</sup>. Macey et al. reported that unlike the control subjects, the breathing rates did not increase as a result of the hypoxic challenge, and the heart rates responded almost normally<sup>8)</sup>. They explained that deficits of some component of the respiratory control circuit and the rapid adjustment of heart rates to hypoxia further indicates an adequate afferent input from the periphery, and the successful integration of inputs within the neural cardiovascular system pathways. Therefore, they suggested that the brainstem or the even more rostral brain regions, which relay the processes for integrative respiratory activity are most affected in CCHS. Most cases reported were sporadic. However, there was a report of a family in which a mother and daughter were affected, and another case involving monozygotic twin girls<sup>9, 10)</sup>.

Cyanosis can be the only symptom and sign in CCHS patients without a monitor due to the lack of respiratory distress signs of tachypnea, retraction of the chest wall, flaring of the alae nasi, etc. Gastrointestinal symptoms including swallowing difficulties, poor feeding, abdominal distension can occur simultaneously<sup>11)</sup>.

A diagnosis of CCHS depends on documenting the hypoventilation during sleep in the absence of primary cardiovascular, pulmonary, neuromuscular, brain or metabolic disorders, and variables including asphyxia, infection, trauma, tumor or infarction must be absent. A patient suspected of having CCHS should have a detailed recording on the evaluation of spontaneous breathing during REM

sleep, NREM sleep and the awake period<sup>12)</sup>. The recording montage should include the movements of the chest and abdomen, SpO<sub>2</sub>, end-tidal pCO<sub>2</sub> and an electrocardiogram. Non-invasive monitoring of the oxygenation and ventilation levels are preferred, because intermittent blood gas sampling would cause arousal. While there is no established diagnostic value, those with CCHS generally have end-tidal pCO<sub>2</sub> readings persistently above 60 torr while asleep<sup>12)</sup>. Our patient underwent polysomnography with intubation but without being connecting to an ambubag. The oxygen saturation of the extremities was checked using a non-invasive pulse oxymeter. During arousal, she showed good self respiration and normal oxygen saturation. However, definite apnea developed as soon as the patient was asleep during polysomnography requiring oxygen and ambubagging to maintain normal oxygen saturation. Total sleep study time was 314.8 minutes but total sleep time was only 222.5 minutes due to multiple awakening by ambubagging with breathing problem. The polysomnography was done twice, 2 months apart and the same results were reproduced.

The treatment of CCHS is to provide adequate ventilation with mechanical assisted ventilation. Pharmacological treatment is not known to be effective. A chronically elevated level of end-tidal pCO<sub>2</sub> can result in pulmonary hypertension<sup>13)</sup>. Most patients require a tracheostomy and positive pressure ventilation and need a home mechanical ventilator. As the patient grows from a neonate to an infant and child, with the duration of sleep being shortened, the weaning of the mechanical ventilation can be made possible with non-invasive modalities including negative pressure ventilation, a diaphragmatic pacemaker, continuous positive airway pressure (CPAP), and a bi-level positive airway pressure (BiPAP)<sup>14)</sup>.

Recently, both the CCHS and HD are classified as a form of neurocristopathy, which is also responsible for other diseases including pheochromocytoma, neuroblastoma, medullary carcinoma of thyroid and carcinoid tumors. Actually there are reports of cases of CCHS with HD or with HD and neuroblastoma<sup>15, 16)</sup>. These reports emphasize the importance of screening CCHS patients for any associated with illnesses such as neuroblastoma and ganglioneuroblastoma. Abnormalities of the eye and autonomic nervous system are also common. Croaker et al. reported 10 out of 46 patients (21.7%) had abnormalities of the pupils, extraocular muscles or eyelids and abnormalities in swal-

lowing and hearing. In addition, 15.2% of the 46 patients reviewed were confirmed to have a neuroblastoma or ganglioneuroma<sup>16)</sup>. Acceptable survival rates can be achieved with the development of appropriate therapeutic options. The decision to treat will generally be unanimous. Although there is no curable therapeutic modality, the patient's quality of life can be improved with a mechanical home ventilator, monitoring, nutritional support and communication between medical staff and the patient's family<sup>12, 17, 18)</sup>.

**한 글 요약**

**신생아에서 진단된 Hirschsprung 병을 동반한 congenital central hypoventilation syndrome 1례**

가톨릭대학교 의과대학 소아과학교실, 정신과학교실\*

최진현 · 오진희 · 김종현 · 고대균 · 홍승철\*

Congenital central hypoventilation syndrome은 혈중 이산화탄소 증가와 저산소에 대한 자율 신경계와 호흡 조절 기능의 선천성 결함으로 호흡의 저환기가 주로 수면시에 발생하는 질환이다. 이는 신경 이주장애 질환(neurocristopathy)에 속한다고 알려져 있으며 선천성 거대결장 등의 질환과 잘 동반된다. 아직 까지 확실한 완치법은 없는 상태이고 환아들은 평생을 환기 보조에 의존하여 생존해야 하며 적절한 환기 보조를 통해서 생존 기간을 연장할 수 있다. 저자들은 출생시부터 반복되는 수면시의 무호흡과 청색증이 있는 환아에서 congenital central hypoventilation 및 선천성 거대 결장이 동반된 1례를 경험하였기에 보고하는 바이다.

**References**

- 1) Mellins RB, Balfour HH, Turino GM, Winters RW. Failure of automatic control of ventilation (Ondine's curse): report of an infant born with this syndrome and review of the literature. *Medicine* 1970;49:487-504.
- 2) Haddad GG, Mazza NM, Defendini R, Blanc WA, Driscoll JM, Epstein MA, et al. Congenital failure of automatic control of ventilation, gastrointestinal motility and heart rate. *Medicine* 1978;57:517-26.
- 3) Ahn YM, Choi HR, Lee HJ, Dong ES, Hong SJ, Moon HN, et al. A case of congenital central hypoventilation syndrome with Hirschsprung's disease. *Pediatr Allergy Respir Dis(Korea)* 1993;3:113-20.

- 4) Weese-Mayer DE, Shannon DC, Keens TG, Silvestri JM. Idiopathic congenital central hypoventilation syndrome: diagnosis and management. *Am J Resp Crit Care Med* 1999; 160:368-73.
- 5) Gozal D, Marcus CL, Shoseyov D, Keens TG. Peripheral chemoreceptor function in the congenital central hypoventilation syndrome. *J Appl Physiol* 1993;74:379-87.
- 6) Fleming PJ, Cade D, Bryan MH, Bryan AC. Congenital central hypoventilation and sleep state. *Pediatrics* 1980;66: 425-8.
- 7) Guillemainault C, McQuitty J, Ariagno RL, Challamel MJ, Korobkin R, McClead RE Jr. Congenital central alveolar hypoventilation syndrome in six infants. *Pediatrics* 1982; 156:866-78.
- 8) Macey, PM, Valderama C, Kim AH, Woo MA, Gozal D, Keens TG, et al. Temporal trends of cardiac and respiratory responses to ventilatory challenges in congenital central hypoventilation syndrome. *Pediatr Res* 2004;55:953-9.
- 9) Khalifa MM, Flavin MA, Wherrett BA. Congenital central hypoventilation syndrome in monozygotic twins. *J Pediatric* 1988;113:853-5.
- 10) Sritippayawan S, Hamutcu R, Kun SS, Ner Z, Ponce M, Keens TG. Mother-daughter transmission of congenital central hypoventilation syndrome. *Am J Respir Crit Care Med* 2002;166:367-9.
- 11) Faure C, Viarme F, Cargill G, Navarro J, Gaultier C, Trang H. Abnormal esophageal motility in children with congenital central hypoventilation syndrome. *Gastroenterology* 2002;122:1258-63.
- 12) Chen ML, Keens TG. Congenital central hypoventilation syndrome: not just another rare disorder. *Paediatr Respir Rev* 2004;5:182-9.
- 13) Barlow PB, Bartlett D Jr, Hauri P, Hellekson C, Nattie EE, Remmers JE, et al. Idiopathic hypoventilation syndrome: importance of preventing nocturnal hypoxemia an hypercarbia. *Am Res Respir Dis* 1980;121:141-5.
- 14) Gozal D. Congenital central hypoventilation syndrome: an update. *Pediatr Pulmonol* 1998;26:273-82.
- 15) Tilman R, Daniel T, Gabriele E, Jurg H. Congenital central hypoventilation syndrome associated with Hirschsprung's disease and neuroblastoma. *Pediatr Pulmonol* 2002;33:71-6.
- 16) Croaker GDH, Shi E, Simpson E, Cartmill T, Cass DT. Congenital central hypoventilation syndrome and Hirschsprung's disease. *Arch Dis Child* 1998;78:316-22.
- 17) Migliori C, Cavazza A, Motta M, Bottino R, Chirico G. Early use of Nasal-BiPAP in two infants with congenital central hypoventilation syndrome. *Acta Pediatr* 2003;92:823-6.
- 18) Gozal D, Simakajornboon N. Passive motion of the extremities modifies alveolar ventilation during sleep in patients with congenital central hypoventilation syndrome. *Am J Respir Crit Care Med* 2000;162:1747-51.