

Combined Congenital Anterior and Posterior Midline Cleft of the Atlas Associated with Asymptomatic Lateral Atlantoaxial Subluxation

Sun-Young Park, M.D., Dong-Ho Kang, M.D., Chul-Hee Lee, M.D., Soo-Hyun Hwang, M.D.

Department of Neurosurgery, School of Medicine, Gyeongsang National University, Jinju, Korea

Although congenital anomalies of the atlas have been well-documented, atlas anomalies of clefts and aplasia are rare. Anterior and posterior midline clefts of the atlas have been reported separately in some series. However, combined congenital anterior and posterior midline clefts of the atlas are reported rarely. Hence, we report a very rare case of combined congenital anterior and posterior midline clefts of the atlas associated with asymptomatic lateral atlantoaxial subluxation.

KEY WORDS : Congenital anomaly · Midline cleft · Atlas.

Introduction

G eipel reported that clefts of the anterior arch occurred in 0.1% of 1613 specimens studied, and clefts of the posterior arch occurred in 4%^{5,14}. Reports of combined anomalies of the anterior and posterior arch of the atlas are very rare. These defects were considered by some to be a benign variation; and indeed, almost all of them are discovered incidentally. This report is of a very rare case of combined anomalies of the atlas that were associated with asymptomatic lateral atlantoaxial subluxation(AAS).

Case Report

A 57-year-old man was admitted for an ophthalmologic operation. The ophthalmologist consulted with us about a suspicious atlantoaxial subluxation detected on cervical X-rays that were performed due to complaint by the patient of intermittent neck discomfort. He had no other symptoms and exhibited no neurological deficits. There was no history of trauma or any significant perinatal history. The range of motion of the cervical spine was full with no abnormal findings. The lateral cervical radiograph demonstrated normal findings (Fig. 1A).

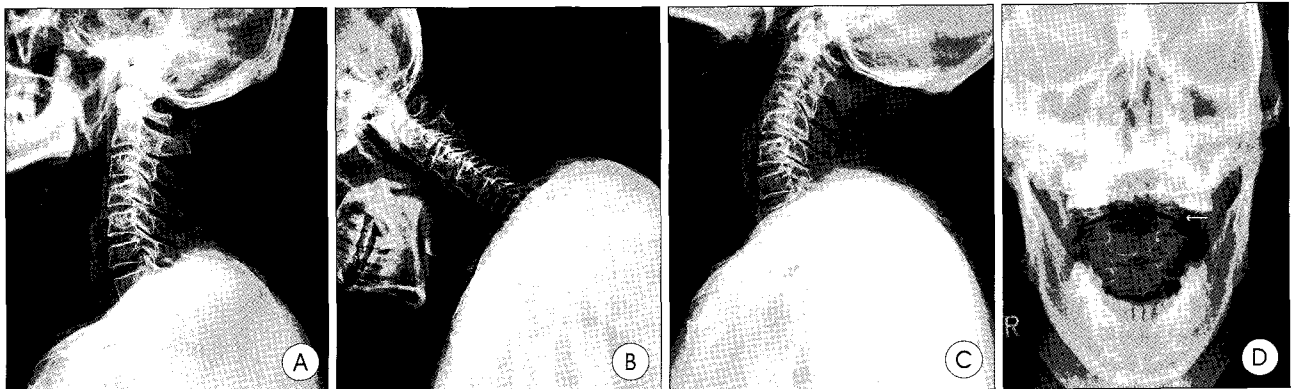


Fig. 1. Simple cervical spine radiograph. A : lateral image demonstrates diffuse osteoporosis but no other abnormal finding, B and C : atlantoaxial instability is not detected, D : lateral atlantoaxial subluxation is evident (arrow).

• Received : January 13, 2006 • Accepted : March 8, 2006
 • Address for reprints : Dong-Ho Kang, M.D., Department of Neurosurgery, School of Medicine, Gyeongsang National University, 90 Chilam-dong, Jinju 660-751, Korea Tel : +82-55-750-8112, Fax : +82-55-759-0817, E-mail : ns4793@hanmail.net

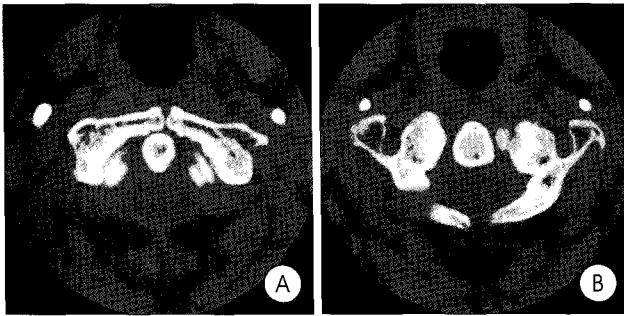


Fig. 2. There are closure defects at anterior (A) and posterior (B) neural arches of the atlas.

Radiographs taken in flexion and extension did not demonstrate AAS as evidenced by an increase in the atlantodental interval (Fig. 1B, C). Trans-oral anterior-posterior views of the atlas revealed a lateral AAS (Fig. 1D). Computed tomography(CT) images with three-dimensional (3D) reconstruction demonstrated a midline cleft, anteriorly and posteriorly, without bony inturning of medial hemiarches of a bifid anterior and posterior arches of atlas (Fig. 2). The patient did not undergo any treatment because he had minimal symptom.

Discussion

There are three ossification centers of the atlas: an anterior ossification center that forms the anterior tubercle, and two lateral centers from which the lateral masses and the posterior arch form^{6,12}. In 2% of the population, a fourth center forms the posterior tubercle. By the seventh gestational week, the lateral centers have extended dorsally to form the posterior arch. At birth, the posterior arches are nearly fused except for several millimeters of cartilage, and union occurs between the ages of 3 and 10 years⁴. The anterior arch ossifies from one or two ossification centers that form within it, or by extension of the lateral masses (without a separate ossification center). Ossification is usually complete by the age of 10¹⁴. Malformations of the atlas include both clefts and aplasia^{1-3, 5,9,15}. Clefts and aplasia of posterior arch are rare^{5,15}. Currarino et al. have divided the posterior arch anomalies into five types, depending on the extent of absence of the posterior arch and the presence or absence of the posterior tubercle⁵ (Fig. 3). Median clefts of the posterior arch of C1 (type A) have been estimated to occur in 4% of the population and represent 97% of all posterior arch defects. Types B through E congenital defects have been reported to occur in 0.69% of the population. They consist of varying degree of unilateral defects (type B), bilateral defects (type C), absence of the posterior arch with a persistent posterior tubercle (type D), and total agenesis of the posterior arch with a persistent posterior tubercle (type E).

Clefts and aplasia of the anterior arch are very rare, accounting for only 0.1% in the Geipel series². These midline clefts

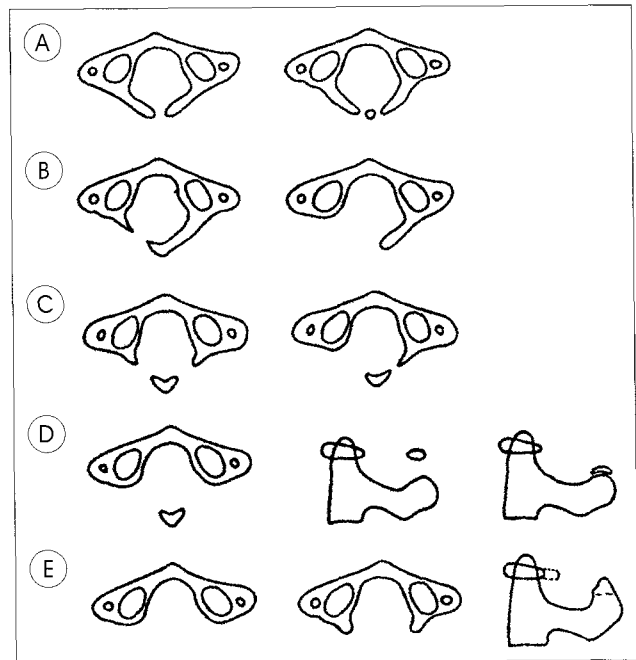


Fig. 3. Congenital anomalies of the posterior arch of the atlas, divided into five types by Currarino : Failure of posterior midline fusion of the two hemiarches (A), Unilateral clefts (B), Bilateral clefts (C), Absence of the posterior arch with persistent posterior tubercle (D), Absence of the entire arch including posterior tubercle (E).

are usually associated with posterior midline clefts and are seldom found in isolation. The anterior arch clefts may occur in the absence of an anterior ossification center and where the lateral masses do not fuse anteriorly; or, no fusion of two anterior ossification centers occurs². The association of both clefts, anterior and posterior, called a bipartite atlas, has been described as well^{3,7,8,11}. A bipartite atlas is also very rare. Several bipartite atlas cases were reported in the recent literature; however, only 40 cases have been reported before 1983^{3,13}. No other cases of bipartite atlas with lateral AAS had been reported previously. The disorder may simulate, and be misdiagnosed as, a Jefferson fracture of the atlas. It is important to differentiate between these pre-existing congenital abnormalities and more recent fractures. On imaging, fractures demonstrate irregular edges with associated soft tissue swelling, while the congenital clefts are smooth with an intact cortical wall and have an absence of a soft tissue swelling.

Cases of combined anterior and posterior clefts of the atlas are either asymptomatic or have minimal symptoms^{3,9}. However, surgical treatment should be considered, if a patient demonstrates an aggravation of neck pain and development of neurologic deficits or an increased AAS.

Conclusion

We report a very rare case of a bipartite atlas with asymptomatic lateral AAS. As minor trauma can result in

serious symptoms such as acute quadriplegia with varying degrees of sensory loss or paresthesias in bipartite atlas patients, careful observation is needed.

References

1. Atasoy C, Fitoz S, Karan B, Erden I, Akyar S : A rare cause of cervical spinal stenosis : posterior arch hypoplasia in a bipartite atlas. *Neuroradiology* 44 : 253-255, 2002
2. Chalmers AG, Gallegos NC : Spondyloschisis of the anterior arch of the atlas. *Br J Radiol* 58 : 761-763, 1985
3. Childers JC, Wilson FC : Bipartite atlas. *J Bone Joint Surg* 53 A : 578-582, 1971
4. Connor S, Chandler C, Robinson S, Jarosz JM : Congenital midline cleft of the posterior arch of atlas : a rare cause of symptomatic cervical canal stenosis. *Eur Radiol* 11 : 1766-1769, 2001
5. Currarino G, Rollins N, Diehl JT : Congenital defects of the posterior arch of the atlas : a report of seven cases including an affected mother and son. *AJNR* 15 : 249-254, 1994
6. Dorne HL, Lander PH : CT recognition of anomalies of the posterior arch of the atlas vertebra : differentiation from fracture. *AJNR* 7 : 176-177, 1986
7. Friedman MB, Jacobs LH : Case report : computed tomography of congenital clefts of the atlas. *Comput Radiol* 9 : 185-187, 1985
8. Haakonsen M, Gudmundsen TE, Histol O : Midline anterior and posterior atlas clefts may simulate a Jefferson fracture. *Acta Orthop Scand* 66 : 369-371, 1995
9. Hosalkar HS, Gerardi JA, Shaw BA : Combined asymptomatic congenital anterior and posterior deficiency of the atlas. *Pediatr Radiol* 31 : 810-813, 2001
10. Kim YZ, Song YJ, Kim HD : Cerebellar Ectopia Associated with Unilateral Agenesis of Posterior Arch of Atlas. *J Korean Neurosurg Soc* 36 : 157-159, 2004
11. Lipson SJ, Mazur J : Anteroposterior spondyloschisis of the atlas revealed by computerized tomography scanning. *J Bone Joint Surg* 60A : 1104-1105, 1978
12. Logan WW, Stuard ID : Absent posterior arch of the atlas. *Am J Roentgenol* 118 : 431-434, 1973
13. Osher SJ, Nasser NA : Coincidental finding of a bipartite atlas during assessment of facial trauma. *Br J Oral Maxillofac Surg* 42 : 270-271, 2004
14. Phan N, Marras C, Midha R, Rowed D : Cervical myelopathy caused by hypoplasia of the atlas : two case reports and review of the literature. *Neurosurgery* 43 : 629-633, 1998
15. Sharma A, Gaikwad SB, Deol PS, Mishra NK, Kale SS : Partial aplasia of the posterior arch of the atlas with an isolated posterior arch remnant : findings in three cases. *AJNR* 21 : 1167-1171, 2000