

임플란트주위골 흡수 및 상악전치부 치조제 형태와의 관계에 대한 방사선학적 연구

이준희 · 홍종락 · 김창수

성균관의대 삼성서울병원 구강악안면외과

Abstract (J. Kor. Oral Maxillofac. Surg. 2006;32:575-579)

RADIOGRAPHIC STUDY OF PERI-IMPLANT BONE LOSS AND ITS RELATIONSHIP TO THE MORPHOLOGY ON MAXILLARY ANTERIOR ALVEOLAR RIDGE

Jun-Hee Lee, Jong-Rak Hong, Chang-Soo Kim

Department of Oral and Maxillofacial Surgery, Samsung Medical Center,
Sungkyunkwan University School of Medicine, Seoul, Rep. of Korea

Purpose

The purpose of this study was to evaluate peri-implant bone loss and implant success on anterior maxillary alveolar ridges and Compare Class III and Class IV ridges in the aspect of peri-implant bone loss.

Material and Methods

14 patients (aged 21 to 68, 6males and 8females), who lacked maxillary anterior teeth and were installed from January 2000 to April 2003 at Samsung Medical Center, were selected. The type of implant used included 30 Brånemark implant. They were taken with digital tomographic and conventional intraoral radiographic examination, and were treated with implant installation without bone augmentation. The peri-implant bone resorption was measured at the mesial and distal aspect of implant on the conventional intraoral radiographs.

Results

The study classified the anterior maxillary alveolar ridge and measured peri-implant bone resorption from the period of implant installation to the 2nd year after functional loading radiographically. The study revealed no statistically significant difference between two groups, which was classified by its morphology. The average bone resorption on healing period before loading was 0.18mm and 0.18mm, the 1st year of loading period, 0.77 mm and 0.84mm, and on the 2nd year of loading period, 0.07mm and 0.06mm, respectively on both Class III and class IV.

Conclusion

In the knife edge form of anterior maxillary residual ridges(Class IV), implant placement without ridge augmentation does not have significant difference with that of Class III alveolar ridge in the concern of Implant success after 2 year functional loading period in the aspect of peri-implant bone resorption radiographically.

Key words: Anterior maxilla, Peri-implant, Bone loss, Bone resorption, Morphology, Cawood & Howell 's classification

I. 서 론

가¹⁾.
가

가^{2,3)}.

가

홍종락

135-710, 서울 강남구 일원동 50

성균관대의대 삼성서울병원 구강악안면외과

Jong-Rak Hong

Dept. of OMFS, Samsung Medical Center Sungkunkwan Univ. School of Medicine

#50, Ilwon-dong, Kangnam-gu, Seoul, Rep. of Korea

Tel: 82-2-3410-2420 Fax: 82-2-3410-0038

E-mail: oralsurgery@naver.com

가 협측 골 및 주변 연조직의 형태
를 예측하기가 어려우며, 일차적인 연조직 치유가 일어난 후
임플란트 식립을 계획하는 경우가 있으며, 환자 사정상 상당
한 시간이 경과하여 내원하는 경우가 많고, 즉시 임플란트 식
립이 가능한 경우에도 협측 치조골 및 주변 연조직 형태의 예
측이 어려워 일차적인 연조직 치유가 일어난 다음 임플란트

Ⅲ. 연구결과

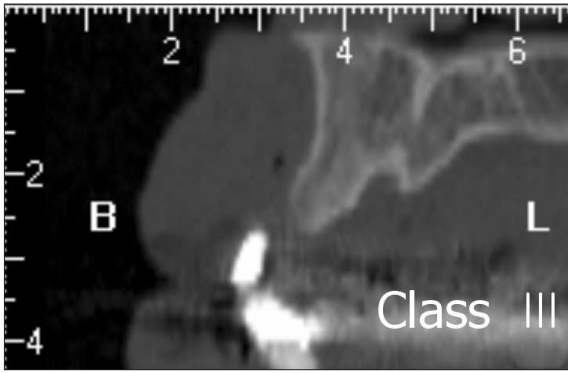


Fig. 2. Computerized Tomography on the anterior maxillae. The case was Cawood & Howell classification III.

가 . , Cawood and Howell
 Class III 가 2 0.3
 mm 1.2mm , Class
 IV 0.6mm 1.1mm
 (Fig. 4, 5). 8
 Class III Class IV
 0.18mm 가
 0.77mm 0.84mm ,
 0.07mm 0.06mm

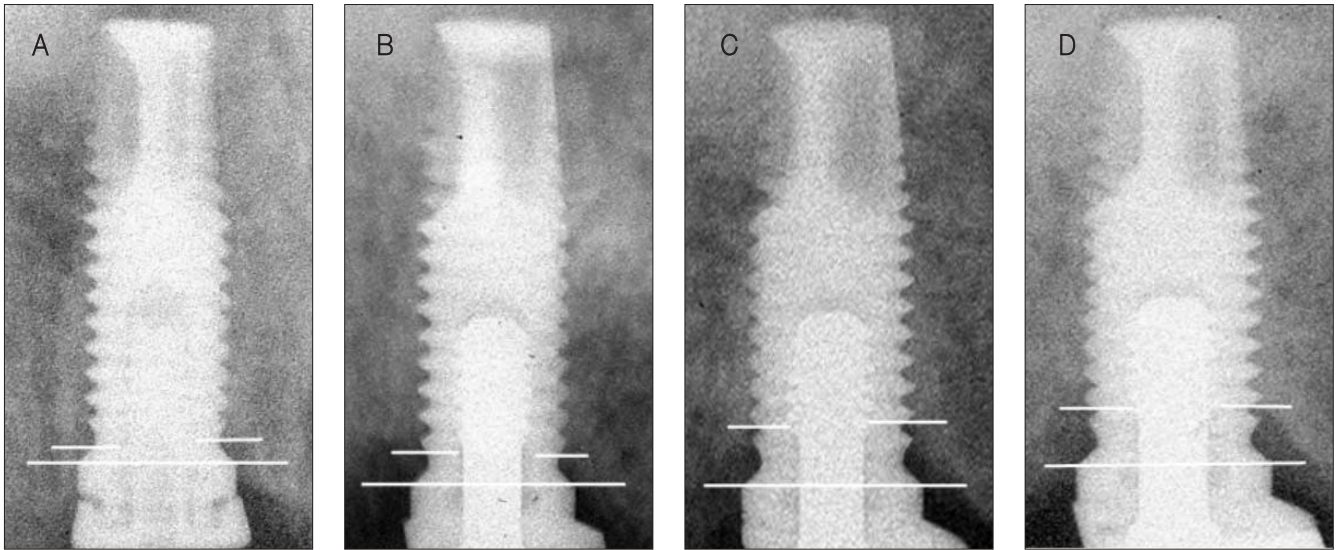


Fig. 3. Mesial and distal measuring of bone resorption on intraoral standard radiographs. (a) immediately after implant installation (b) 8 months healing period after implant installation (c) 1 year after loading on the implant (d) 2 years after loading on the implant.

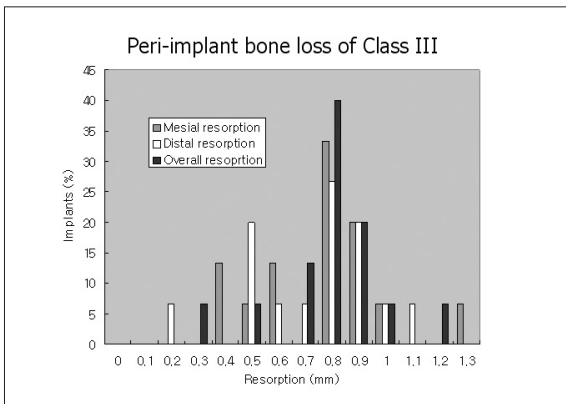


Fig. 4. Total peri-implant bone loss of class III.

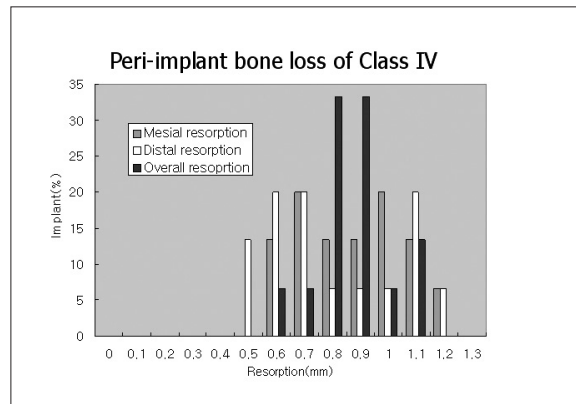


Fig. 5. Total peri-implant bone loss of class IV.

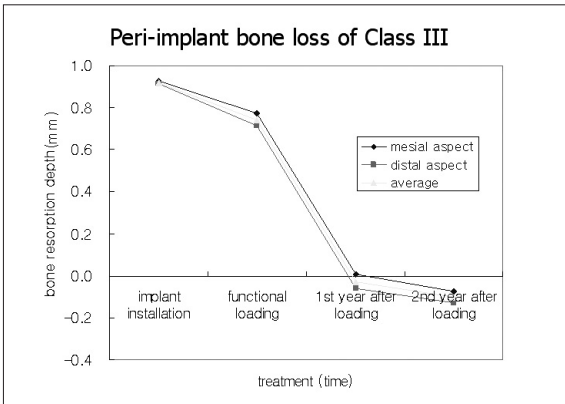


Fig. 6. Peri-implant bone loss of class III at each stage.

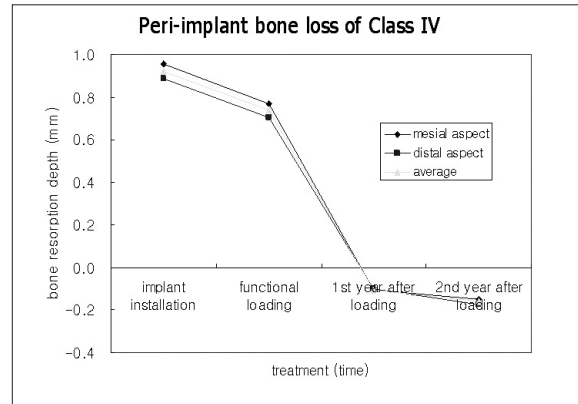


Fig. 7. Peri-implant bone loss of class IV at each stage.

1
Class III Class IV
(p < 0.05, Table 1).

IV. 총괄 및 고찰

가 6.7)
가 7.8)
가 가 9-11)
가 1 1mm 가 12-14)
0.1mm 가
가 가
1mm 9-11)
Class IV 가

lass III 가
가
가
가 15)
1mm
가
Class III Class IV
가 가
가 16)
가 17)
5mm 가
가 가
가 가
가 가
21 68

C

Bryant

Zarb

가

18).

가

5).

가가

가

V. 결 론

(Cawood and Howell

Class IV)

가 Class III

가 2

참고문헌

1. Andreasen JO: Fractures of the alveolar process of the jaw. A clinical and radiographic follow-up study. Scand J Dent Res 1970;78:263-272.
2. Lazzara RJ: Immediate implant placement into extraction sites: surgical and restorative advantages. Int J Periodontics Restorative Dent 1989;9:332-343.
3. Werbitz MJ, Goldberg PV: The immediate implant: bone preservation and bone regeneration. Int J Periodontics Restorative Dent 1992; 12:206-217.
4. Nevins M, Mellonig JT: The advantages of localized ridge augmentation prior to implant placement: a staged event. Int J Periodontics

- Restorative Dent 1994;14:96-111.
5. Penarrocha M, Palomar M, Sanchis JM, Guarinos J, Balaguer J: Radiologic study of marginal bone loss around 108 dental implants and its relationship to smoking, implant location, and morphology. Int J Oral Maxillofac Implants 2004;19:861-867.
6. Cawood JL, Howell RA: A classification of the edentulous jaws. Int J Oral Maxillofac Surg 1988;17:232-236.
7. Pietrokovski J, Massler M: Alveolar ridge resorption following tooth extraction. J Prosthet Dent 1967;17:21-27.
8. Pietrokovski J, Sorin S, Hirschfeld Z: The residual ridge in partially edentulous patients. J Prosthet Dent 1976;36:150-158.
9. Watzek G, Solar P, Ulm C, Matejka M: Surgical criteria for endosseous implant placement: an overview. Pract Periodontics Aesthet Dent 1993;5:87-94, quiz 96.
10. Dahlin C, Linde A, Rockert H: Stimulation of early bone formation by the combination of an osteopromotive membrane technique and hyperbaric oxygen. Scand J Plast Reconstr Surg Hand Surg 1993;27:103-108.
11. Adell R, Lekholm U, Rockler B, Branemark PI, Lindhe J, Eriksson B et al.: Marginal tissue reactions at osseointegrated titanium fixtures (I). A 3-year longitudinal prospective study. Int J Oral Maxillofac Surg 1986;15:39-52.
12. Levy D, Deporter DA, Pharoah M, Tomlinson G: A comparison of radiographic bone height and probing attachment level measurements adjacent to porous-coated dental implants in humans. Int J Oral Maxillofac Implants 1997;12:541-546.
13. Behneke A, Behneke N, d' Hoedt B, Wagner W: Hard and soft tissue reactions to ITI screw implants: 3-year longitudinal results of a prospective study. Int J Oral Maxillofac Implants 1997;12:749-757.
14. Becker W, Becker BE, Israelson H, Lucchini JP, Handelsman M, Ammons W et al.: One-step surgical placement of Branemark implants: a prospective multicenter clinical study. Int J Oral Maxillofac Implants 1997;12:454-462.
15. Celletti R, Pameijer CH, Bracchetti G, Donath K, Persichetti G, Visani I: Histologic evaluation of osseointegrated implants restored in nonaxial functional occlusion with preangled abutments. Int J Periodontics Restorative Dent 1995;15:562-573.
16. Kois JC: Predictable single-tooth peri-implant esthetics: five diagnostic keys. Compend Contin Educ Dent 2004;25:895-896, 898, 900 passim; quiz 906-897.
17. Tarnow DP, Magner AW, Fletcher P: The effect of the distance from the contact point to the crest of bone on the presence or absence of the interproximal dental papilla. J Periodontol 1992;63:995-996.
18. Bryant SR, Zarb GA: Crestal bone loss proximal to oral implants in older and younger adults. J Prosthet Dent 2003;89:589-597.