

- 1 -

가 , * , †
* †

2 가 1

가

2,3,6)

CRP가 3.75

mg/L(: 0.03mg/L) 가
785IU/L 가

MR가

2,4,6)

가

가

1

(Fig. 1A, 1B). MRI

(Fig. 2A)

2

가 (Fig. 2B)

13 가 6

CRP 가

:

93-6

가

Tel: 031) 249-7184, Fax: 031) 254-8228, E-mail: ykang@vincent.cuk.ac.kr

Langerhans
(Fig. 3).

가

(Fig. 4).

(Fig. 5), MRI

4

가

2

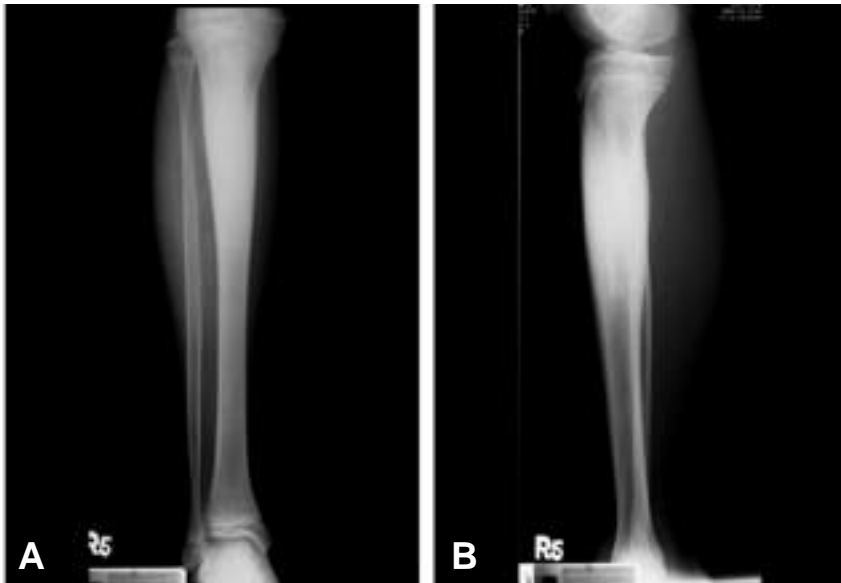

Fig. 1. AP (A) and lateral (B) plain radiographs of the right tibia showing extensive sclerosis and expansion. No definite nidus is identified.

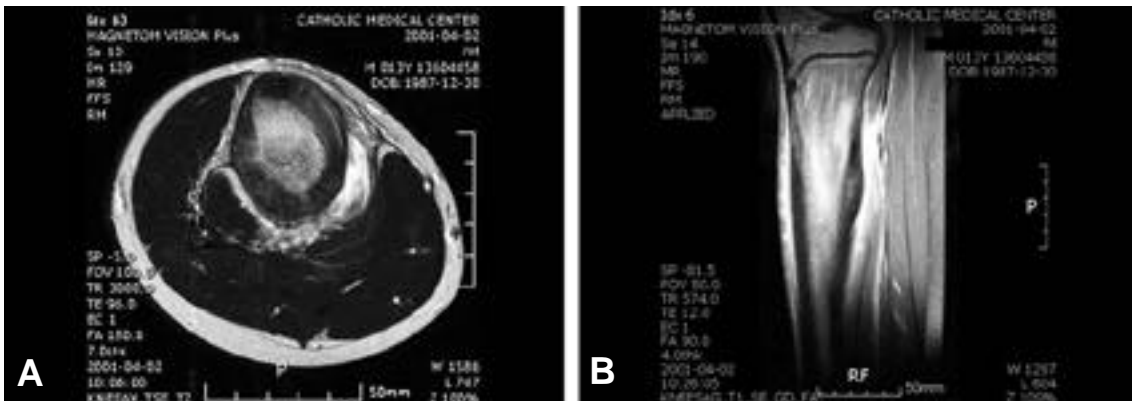


Fig. 2. (A) A T2-weighted MR image showed marked cortical thickening combined with extensive surrounding soft tissue reaction, which suggested subacute sclerosing osteomyelitis. (B) A fat-suppressed contrast-enhanced T1-weighted MR image showed two small enhancing foci in thickened posterior cortex of the right proximal tibia.

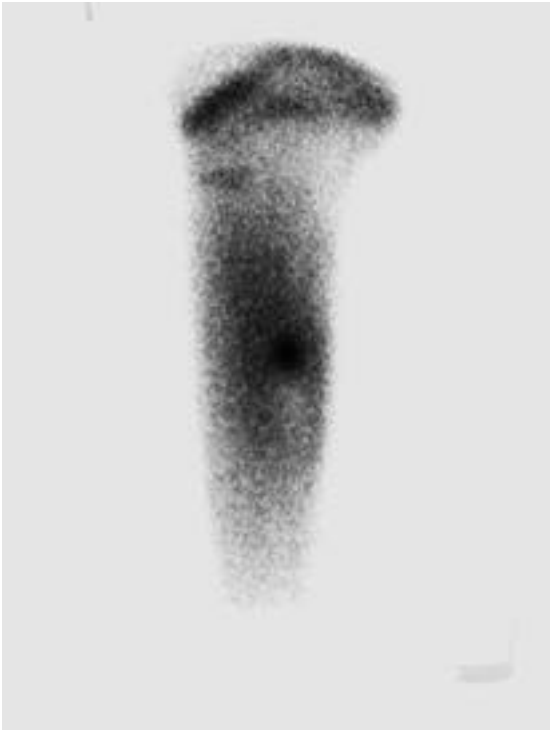


Fig. 3. A pinhole image of bone scan showed a small round hot spot surrounded by diffusely increased homogenous uptakes at meta-diaphysis of the right proximal tibia.

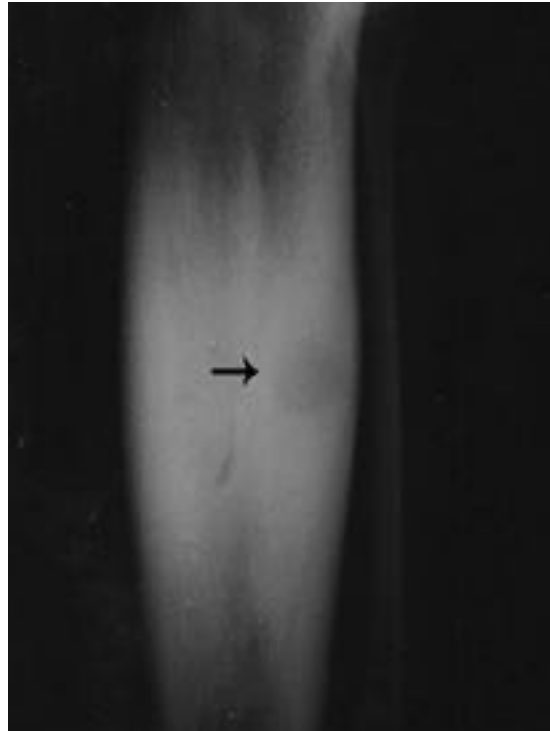

Fig. 4. A follow up lateral plain radiograph of the right tibia at postoperative 18 months revealed a small radiolucent nidus-like lesion (black arrow) in the sclerotic posterior cortex.

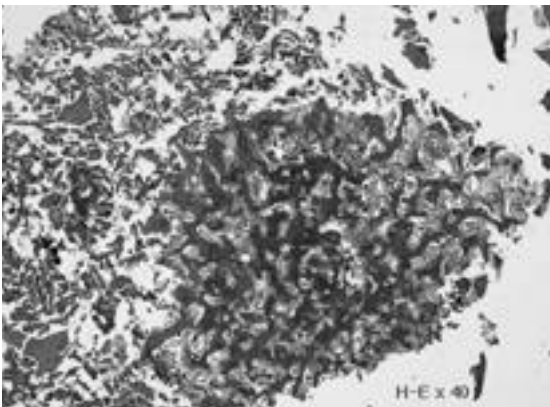


Fig. 5. Histological findings of irregular trabecular bones with osteoblast-lining surrounded by capillary-rich connective tissue were consistent with osteoid osteoma.

2
가 .

10 20
(, nidus)

가

2,3,4,6) 가

(Brodie abscess),
Langerhans , Paget ,

가

**Multicentric Osteoid Osteoma mimiking Sclerosing Osteomyelitis
-A Case Report-**

Yang-Guk Chung, M.D., Yong-Koo Kang, M.D., Won-Hee Jee, M.D.*, An-Hi Lee, M.D. †, Seung-Koo Rhee, M.D., Won-Jong Bahk, M.D., Ill Seok Park, M.D.

Department of Orthopedic Surgery, Department of Diagnostic Radiology,
Department of Clinical Pathology† The Catholic University of Korea, College of Medicine*

The typical radiologic findings of a small radiolucent nidus with surrounding sclerosis and night pain responding to aspirin make the diagnosis of osteoid osteoma not too difficult. We report a case of multicentric osteoid osteoma with unusual clinical and imaging features which were strongly suggestive of subacute sclerosing osteomyelitis.

Key Words: Sclerosing osteomyelitis-like, Multicentric, Osteoid osteoma

Address reprint requests to

Yong-Koo Kang, M.D.

Department of Orthopedic Surgery, St Vincent Hospital, College of Medicine, The Catholic University of Korea
#93-6 Ji-dong, Paldal-gu, Suwon 442-723 Korea.

TEL: 82-31-249-7184, Fax: 82-31-254-8228, E-mail: ykang@vincent.cuk.ac.kr