

— Abstract —

The Effect of Indwelling Silk Suture Following Aspiration in the Treatment of Chronic Olecranon Bursitis

Bong-Jin Lee, M.D., Sung-Rak Lee, M.D., Seong-Tae Kim, M.D.

Department of Orthopaedic Surgery, Halla General Hospital, Jeju, Korea

The purpose of this study was to evaluate the drainage effect of silk suture following aspiration of the bursa as an early treatment of chronic olecranon bursitis. Eleven cases, which have over two weeks of history and over one year of follow-up, were investigated. The average duration of follow-up was 17.5 months. The average symptom duration was 1.8 months. With an aseptic technique, the aspiration of the bursa was done with 18gauge needle and syringe and then the insertion of silk suture through the aspiration needle was performed. The amount of drainage was regularly checked 2~3 days interval and stitch out was done at the cessation of drainage. At the follow-up, recurrence, infection, pain, and limitation of range of motion were investigated by telephone interview. Redness around the insertion site of silk suture was found in all cases, but there was no active infection or recurrence. The results were satisfactory in all cases and the average time for recovery was 10.5 days. The drainage with silk suture following aspiration of the bursa is less invasive and very effective method in the early treatment of chronic olecranon bursitis.

Key Words: Olecranon Bursitis, Aspiration, Silk Suture

1963-2

Tel: 064) 740-5111, Fax: 064) 743-3110, E-Mail: schstk27@hanmail.net

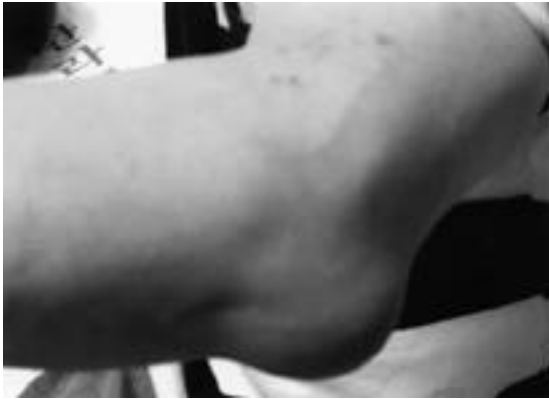

Fig. 1. The photograph shows 5 × 4 cm sized mass, presented in 40-year-old male.

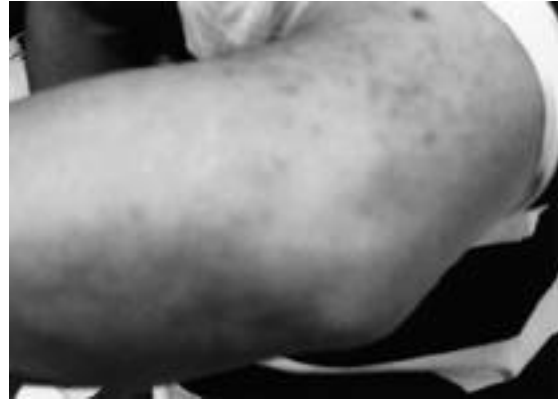

Fig. 2. The photograph shows resolution of the bursitis after treatment.

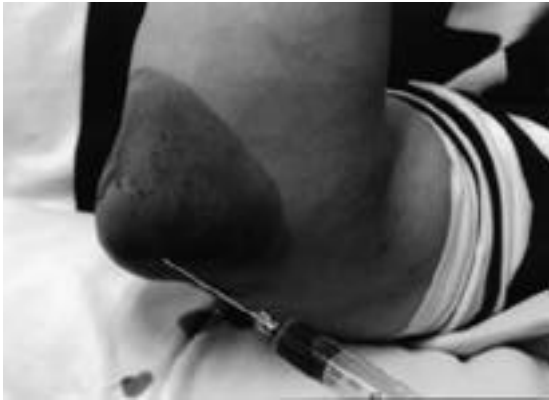


Fig. 3. Needle puncture and aspiration were performed with 18 gauge spinal needle.

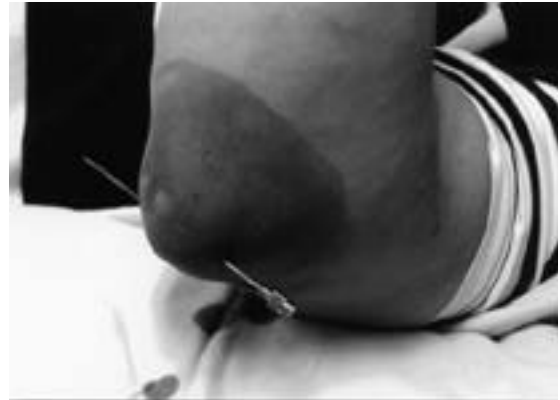

Fig. 4. The needle was advanced out of the bursa.

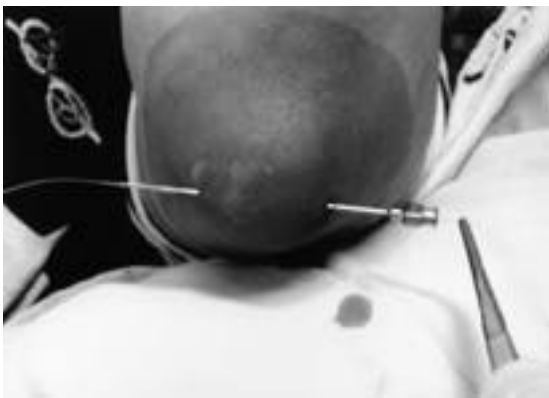

Fig. 5. Silk suture (No. 7) was inserted through the needle.

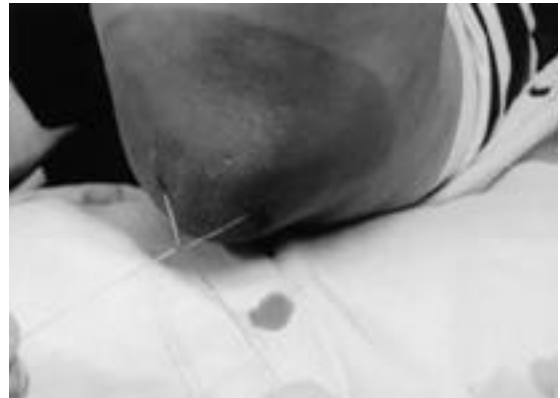

Fig. 6. Tie was performed at 2 cm apart from the skin.

가

, ' 가 (Fig. 2) , 3

가 1 , ,

2002 1 2003 12
2
1 가가 11 , 11
(Fig. 1,2),

12 24 17.5 ,
가 9 , 가 2 , 40
71 60.1 .
1 ,
가 1 , 11
. 2

가 , 7 15
1 . 10.5 .
2 4

1.8 .

18

(Fig. 3),

18 Albinus
bursa 가¹⁾.

(Fig. 4).

7

가 (anatomical bursa)
(adventitious bursa) .
(constant

(Fig. 5),

2~3 cm

bursa)

(Fig. 6).

가 ,

2~3

(,) 가 .

12)

6)

5)

가

가

가

2,7)

가

2

가 15)

12)

(10)

6

가

0.1±0.3

(10)

1.0±1.2

10%

16)

가

2)

가

17)

가

가

가

가

14)

14)

10)

3,8,9,11,13)

4)

REFERENCES

- 1) **Boutin FJ, Sr, Boutin RD, Boutin, Jr:** Bursitis. In: Chapman MW ed. *Operative Orthopaedics*. Second ed. Philadelphia, JB Lippincott Co: 3419-3432,1993.
- 2) **Butcher JD, Salzman KL and Lillegard WA:** Lower extremity bursitis. *Am Family Physic*, 53:2317-2324,1996.
- 3) **Chae IJ, Han SB and Lee BT:** Arthroscopic resection of prepatellar bursitis. *J Korean Arthroscopy Soc*, 4:38-41,2000.
- 4) **Fisher RH:** Conservative treatment of distended patellar and olecranon bursae. *Clin Orthop*,

- 123:98,1977.
- 5) **Goldwirth M, Krasin E and Goodwin DR:** Talcum powder in revision surgery for olecranon bursitis. *Acta Orthop Scand*, 70:286-287,1999.
 - 6) **Hassell AB, Fowler PD and Dawes PT:** Intra-bursal tetracycline in the treatment of olecranon bursitis in patients with rheumatoid arthritis. Preliminary report. *Br J Rheum*, 33:859-860,1994.
 - 7) **Ji JH, Kim WY, Kim JY, Jung SR and Kim JC:** Secondary septic arthritis due to olecranon Bursitis. A Case Report. *J Korean Shoulder Elbow Soc*, 6:167-172,2003.
 - 8) **Kaalund S, Breddam M and Kristensen G:** Endoscopic resection of the septic prepatellar bursa. Case report. *Arthroscopy*, 14:757-758,1998.
 - 9) **Kerr DR and Carpenter CW:** Arthroscopic resection of olecranon and prepatellar bursae. *Arthroscopy*, 6:86-88,1990.
 - 10) **Knight JM, Thomas JC and Maurer RC:** Treatment of septic olecranon and prepatellar bursitis with percutaneous placement of a suction-irrigation system. A report of 12 cases. *Clin Orthop*, 206:90-93,1986.
 - 11) **Kyung HS, Kim HS, Hwang JK and Ihn JC:** Arthroscopic treatment of recurrent prepatellar bursitis. *J Korean Arthroscopy Soc*, 6:183-187,2002.
 - 12) **Nardella FA:** Blood-patch treatment for prepatellar bursitis(Housemaid's knee). *New Eng J Med*, 306:1553,1982.
 - 13) **Ogilvie-Harris DJ and Gilbert M:** Endoscopic bursal resection: The olecranon bursa and prepatellar bursa. *Arthroscopy*, 16:249-253,2000.
 - 14) **Quayle JB and Robinson MP:** An operation for chronic prepatellar bursitis. *J Bone Joint Surg*, 58-B:504-506,1976.
 - 15) **Shell D, Perkins R and Cosgarea A:** Septic olecranon bursitis: Recognition and treatment. *J Am Board Fam Pract*, 8:217-220,1995.
 - 16) **Smith DL, McAfee JH, Lucas LM, Kumar KL and Romney DM:** Treatment of nonseptic olecranon bursitis. A controlled, blinded prospective trial. *Arch Intern Med*, 149:2527-2530.
 - 17) **Stewart NJ, Manzanares JB and Morrey BF:** Surgical treatment of aseptic olecranon bursitis. *J Shoulder Elbow Surg*, 6:49-54,1997.