

Biliary Cystadenoma in a Captive Japanese Macaque (*Macaca fuscata*)

Ho-seong Cho, Joseph S. Masangkay, Young-seob Kim and Nam-yong Park¹

Department of Veterinary Pathology, College of Veterinary Medicine, Chonnam National University

Abstract : A seven-year old female captive Japanese macaque (*Macaca fuscata*) was mobbed by its cage mates and subsequently died due to trauma. An incidental finding of multiple biliary cystadenoma in the liver is herein reported. Grossly, multiple small cysts were observed throughout the surface of the liver. One particular cyst that measured 1.3 × 1.2 × 1.0 cm and contained mucinous fluid was observed in the center of the liver. Microscopically the cysts were lined by biliary epithelium that varied from simple cuboidal to columnar cells. Signs of malignancy and metastasis to other organs were not observed. This is the first report of biliary cystadenoma in Japanese macaque.

Key words : biliary cystadenoma, liver, Japanese macaque (*Macaca fuscata*).

Introduction

Biliary cystadenoma, also known as biliary cystic adenoma, with single or multilocular cysts is considered as a subtype of cholangioma¹². In animals, biliary cystadenoma is not detected clinically because of the absence of clinical signs. Among animals, the domestic cat appears to be the most commonly affected by this tumor^{1,5,9,13}. This tumor has been reported in dog¹⁴, sheep^{3,16} and pigs⁴. In the fish, biliary cystadenoma was one kind of neoplasm found in farmed Chinook salmon (*Onchorhynchus tshawytscha*) from New Zealand¹⁰.

In humans, biliary cystadenoma can be caused by the hydatid cyst of *Echinococcus granulosus* and it must be carefully diagnosed to differentiate it from non-parasitic cause of this tumor¹³. In humans, there are two subset of biliary cystadenoma. The former subset of biliary cystadenoma, which occurs exclusively in women and is characterized by two histologic components, a cyst lining of mucin-secreting cuboidal to columnar epithelium and distinctive, densely cellular sub-epithelial mesenchymal stroma (MS), was later termed "cystadenoma with MS" and the latter is cystadenoma without MS which occurs mainly in man¹⁷. In contrast to cystadenoma with MS, biliary cystadenoma can arise in male patients.

As no case of a biliary cystadenoma has been published in detail, in this report a case of a biliary cystadenoma in a Japanese macaque is herein presented.

Case

This case involved a captive seven-year-old female Japanese macaque (*Macaca fuscata*) from a zoo in Gyeonggi province, Republic of Korea. The animal died as a result of mobbing by its cage mates. External examination revealed hemorrhages in the buttocks and lips. A big wound at the back measuring 20 × 3 cm was also found. The lungs had multifocal hemorrhagic foci and areas of rubbery consistency.

Blood clots were present inside the chambers of the heart. The stomach and duodenum showed mucosal hemorrhages. The animal was in a fairly good nutritional condition as evidenced by its good musculature. Peritoneal abdominal fat was also clearly evident. The most noticeable lesion was the presence of multiple hepatic cysts of varying sizes. The biggest cyst measured 1.3 × 1.2 × 1.0 cm (Fig 1), contained clear to slightly yellowish mucinous fluid.

The collected tissue samples were subjected to the routine histopathological examination using hematoxylin and eosin stain. Sections of the hepatic cyst showed that the hepatocytes were compressed by the expanding cysts and some of them tend to form islands of nearly normal hepatocytes (Fig 2). The lining of the cyst was composed of biliary epithelium varying from simple cuboidal to simple columnar. Nuclei were round to oval and centrally located. There was moderate amount of pale eosinophilic cytoplasm. The lining epithelial cells were usually in a single file but in some places multilayered cells were noted (Fig 3). Mitotic figures were scanty to almost absent. Around this, the interstitium consisted

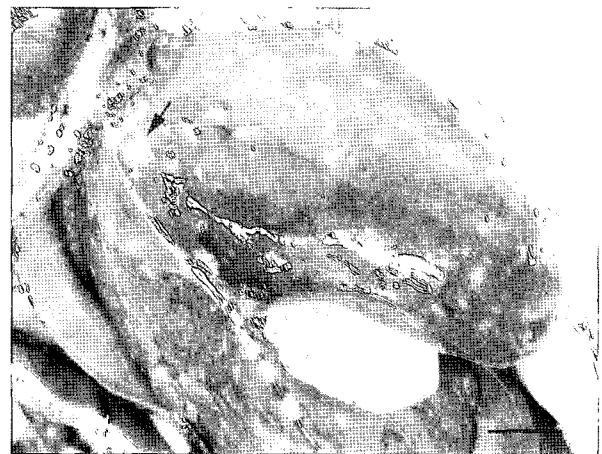


Fig 1. Gross lesion of the liver of Japanese macaque. Note the multifocal cysts throughout the surface of the liver (arrow). Bar=2 cm.

¹Corresponding author.
E-mail : nypark@chonnam.ac.kr




Fig 2. Biliary cystadenoma; Japanese macaque. Note the multiple cysts in the liver. Hepatocytes were compressed by the expanding cysts and some of them tend to form islands of normal hepatocytes. H&E. $\times 40$.




Fig 3. Biliary cystadenoma; Japanese macaque. The lining of the cyst was composed of biliary epithelium varying from simple cuboidal to simple columnar. There was moderate amount of pale eosinophilic cytoplasm. The lining epithelial cells were usually in a single file but in some places multilayered cells were noted (arrow). H&E. $\times 400$.

mainly of fibro-collagenous tissue with intervening normal liver tissue. No inflammatory cell infiltration was seen in the interstitium. Evidence of local invasion to adjacent liver parenchyma or blood vessels was absent. The above histopathological findings clearly indicated a benign biliary cystadenoma.

Discussion

Biliary cystadenoma is one of the benign epithelial tumors of the liver¹². In humans, cystadenoma accounts for about 3-5% of intrahepatic non-parasitic cysts and is usually unilo-

cular⁷. Half of the reported cases in which the site was specified had tumors in the right lobe of the liver, over one-fourth in the left and the rest in both lobes⁷. One tumor was located in the caudate lobe⁸. Eighty per cent of the reported patients were females and many of these were above 30 years of age⁷. As in our case, tumor was located in the right and left lobe of a female Japanese macaque.

In humans, the histologic appearance of biliary cystadenoma with MS has been well characterized and consists of a neoplastic cyst lined by mucin-producing columnar to cuboidal epithelial cells. The cyst is underlined by a layer of undifferentiated mesenchymal cells and an outer layer of dense collagenous connective tissue, which delimits the cyst from the adjacent hepatic parenchyma¹⁷. As in our case, this tumor was diagnosed as biliary cystadenoma without MS base on human criteria¹⁷.

Just like most neoplasms the etiology of biliary cystadenoma is unknown. However, some chemicals suspected to be carcinogens like nitrosamines can produce this kind of tumor in swine⁶ and dogs². Likewise, in this case the exact cause is difficult to determine. All we can say is that since the animal was kept for a long time in the zoo located within a busy metropolitan area, the pollutants from the poor quality of air plus unknown possible carcinogens taken by the animal could have contributed to the formation of the tumor.

The treatment of choice for biliary cystadenoma is complete surgical excision with 1 cm margin allowance in animals and human. Cholecystectomy may also be required. If complete removal is not possible, partial excision may be adequate for good prognosis due to the slow-growing nature of this tumor. Recurrence appears to be extremely rare, but has been reported in at least one case. Other treatments, such as aspiration, marsupialization, and partial excision have met with limited success and are not recommended since there may be a possibility of malignant transformation^{7,11,15}.

As far as literature search is concerned, it appears that this is the first report of biliary cystadenoma in a Japanese macaque.

Conclusion

A seven-year old female captive Japanese macaque (*Macaca fuscata*) was mobbed by its cage mates and subsequently died due to trauma. An incidental finding of multiple biliary cystadenoma in the liver was observed. The cysts were lined by biliary epithelium that varied from simple cuboidal to columnar cells. Signs of malignancy and metastasis to other organs were not observed. There is a high probability that the biliary cystadenoma could have been caused by unknown carcinogens taken in by the animal from the polluted environment during its captive condition.

References

1. Adler R, Wilson DW. Biliary cystadenoma of cats. Vet

- Pathol 1995; 32: 415-418.
2. Allison JB, Wase AW, Leatham JH, Wainio WW. Some effects of 2-acetylaminofluorene on the dog. *Cancer Res* 1950; 10: 266-271.
 3. Anderson LJ, Sandison AT. Tumors of the liver in cattle, sheep and pigs. *Cancer* 1967; 21: 289-301.
 4. Bastianello SS. A survey on neoplasia in domestic species over a 40-year period from 1935 to 1974 in the Republic of South Africa. III. Tumours occurring in pigs and goats. *Onderstepoort J Vet Res* 1983; 50: 25-28.
 5. Carpenter JL, Andrews LK, Holzworth J. Tumors and tumor-like lesions. In: *Diseases of the Cat: Medicine and Surgery*. Philadelphia: W.B. Saunders. 1987: 406-596.
 6. Graw JJ, Berg H. Hepatocarcinogenic effect of DENA in pigs. *Zeitschrift für Krebsforsch* 1977; 89: 137-143.
 7. Ishak KG, Willis GW, Cummins SD, Bullock AA. Biliary cystadenoma and cystadenocarcinoma. *Cancer* 1977; 39: 322-338.
 8. Kokal KC, Abraham P, Pimparkar BD, Desai AP, Bapat RD. Biliary cystadenoma of the liver. (A case report). *J Postgrad Med* 1983; 29: 53-55.
 9. Lawrence HJ, Erb HN, Harvey HJ. Nonlymphomatous hepatobiliary masses in cats: 41 cases (1972 to 1991). *Vet Surg* 1994; 23: 365-368.
 10. Lumsden JS, Marshall S. Sporadic neoplasms of farmed Chinook salmon *Onchorhynchus tshawytscha* (Walbaum) from New Zealand. *J Fish Dis* 2003; 26: 393-399.
 11. March JL, Dahms B, Longmire WP. Cystadenoma and cystadenocarcinoma of the biliary system. *Arch Surg* 1974; 109: 41-43.
 12. Meuten DJ. Tumors of the liver and gall bladder. In: *Tumors in Domestic Animals*. 4th ed. Iowa: Iowa State University Press. 2002; 493-499.
 13. Rutledge JN, Pratt MC, Taupmann RE. 1983. Biliary cystadenoma mistaken for an echinococcal cyst. *South Med J* 1983; 76: 1575-1577.
 14. Trigo FJ, Thompson H, Breeze RG, Nash AS. The pathology of liver tumours in the dog. *J Comp Pathol* 1982; 92: 21-39.
 15. Trout NJ, Berg RJ, McMillan MC, Schelling SH, Ullman S. Surgical treatment of hepatobiliarycystadenomas in cats: five cases (1988-1993). *J Am Vet Med Assoc* 1995; 206: 505-507.
 16. Watt DA. A hepatocholangioma in a sheep. *Aust Vet J* 1970; 46: 552.
 17. Wheeler DA, Edmonson HA. Cystadenoma with mesenchymal stroma (CMS) in the liver and bile ducts. A clinicopathologic study of 17 cases, 4 with malignant change. *Cancer* 1985; 56: 1434-1445.

일본 원숭이(*Macaca fuscata*)의 담관 낭샘종(biliary cystadenoma) 증례

조호성 · Joseph S. Masangkay · 김영섭 · 박남용¹

전남대학교 수의과대학 병리학교실

요약 : 동물원에서 사육 중이던 7세령 암컷 일본원숭이가 찢김기 과정에서 피부에 외상을 입은 후 치료 도중 폐사하였다. 부검시 간에서 1.3×1.2×1.0 cm 크기를 비롯한 다양한 크기의 다발성 낭포가 관찰되었으며 낭포내에 점액성 액체가 저류되어 있었다. 현미경 소견상 낭포는 담관 상피세포로 덮혀 있었고 입방상피에서 원주상피까지 다양하였으며 대부분 단층이었으나 일부는 여러층으로 덮혀 있었다. 악성도나 다른 장기로의 전이 소견은 찾을 수 없었다. 본 증례는 일본 원숭이에서 발견된 첫 번째 담관 낭샘종 증례이다.

주요어 : 담관 낭샘종, 간, 일본원숭이