

## Treatment Outcome of Metastatic Carcinoma of Cervical Lymph Node from an Unknown Primary

Kyubo Kim, M.D.\*, Eui Kyu Chie, M.D.\*, Hong-Gyun Wu, M.D., Ph.D.\*<sup>§</sup>, Kwang Hyun Kim, M.D., Ph.D.<sup>†</sup>, Myung-Whun Sung, M.D., Ph.D.<sup>†</sup>, Dae Seog Heo, M.D., Ph.D.<sup>†</sup> and Charn Il Park, M.D., Ph.D.\*<sup>§</sup>

Departments of \*Radiation Oncology, <sup>†</sup>Otolaryngology and Head & Neck Surgery, and <sup>†</sup>Internal Medicine, Seoul National University College of Medicine, <sup>§</sup>Institute of Radiation Medicine, Medical Research Center, Seoul National University

**Purpose:** To analyze the outcome of radiation therapy for patients with a metastatic carcinoma of cervical lymph nodes from an unknown primary (MUO), and identify the prognostic factors for these patients.

**Materials and Methods:** Between July 1981 and June 1999, 39 patients with MUO underwent radiation therapy with curative intent. Twelve patients were treated with radiation therapy alone (Group 1), 8 with neoadjuvant chemotherapy followed by radiation therapy (Group 2), and 19 with either an excision or neck dissection and postoperative radiation therapy (Group 3). There were 31 males and 8 females, with a median age of 55 years, ranging from 25 to 77 years. The median duration of follow-up was 38 months, ranging from 3 to 249 months.

**Results:** The 5-year overall survival rate was 55%. According to the treatment modality, the 5-year disease-free survival rates of Groups 1, 2 and 3 were 48, 19 and 75%, respectively ( $p=0.0324$ ). In addition to the treatment modality, the appearance of the primary site was a significant prognostic factor for disease-free survival ( $p=0.0085$ ).

**Conclusion:** Surgical resection and radiation therapy achieves a superior disease-free survival compared to radiation therapy alone, either with or without chemotherapy. Further investigation is needed to evaluate the role of chemotherapy in the treatment of MUO.

**Key Words:** Metastatic carcinoma of cervical lymph node, Unknown primary, Radiation therapy

### Introduction

Metastatic carcinoma of unknown origin (MUO) represents a heterogeneous group of malignancies presenting with lymph node or distant metastases, for which a work-up fails to identify the site of origin.<sup>1)</sup> In this study, the authors defined MUO as a metastatic carcinoma of cervical lymph node without distant metastases below clavicle despite the thorough evaluation for primary origin.

MUO represents 3~9% of the total head and neck cancer

cases, despite careful physical examination, CT and/or MRI, endoscopy and biopsies.<sup>2)</sup> There are several management options for these patients and also a great deal of controversy regarding the optimal treatment. It has been generally accepted that N1 disease without extracapsular extension has low risk of recurrence and can be treated with neck dissection or excision alone.<sup>3~5)</sup> N3 disease has high risk of recurrence with single modality (either radiation therapy alone or neck dissection alone),<sup>5~7)</sup> and combined modality has been suggested.<sup>8~10)</sup> On the other hand, N2 disease has heterogeneous disease spectrum, so a variety of treatment methods are employed.

In this study, we compared the outcome of various combinations of treatment for MUO, and analyzed the prognostic factors.

Submitted August 17, 2005, accepted September 15, 2005  
Reprint request to Hong-Gyun Wu, Department of Radiation Oncology, Seoul National University College of Medicine, 28 Yeongeon-dong, Jongno-gu, Seoul 110-744, Korea  
Tel: 02)2072-3177, Fax: 02)765-3317  
E-mail: wuhg@snu.ac.kr

## Materials and Methods

### 1. Study population

Between July 1981 and June 1999, 44 patients who had newly diagnosed MUO underwent radiation therapy with curative intent at the Department of Radiation Oncology, Seoul National University Hospital. Of these, 5 patients were excluded from the analysis: 2 patients due to follow-up loss just after treatment; 2 patients due to inadequate clinical information; one patient due to previous history of other malignancy. Therefore, 39 patients were included in this retrospective study.

The population was predominantly men (31 patients, 79%). The median age of the patients was 55 years old (range; 25~77). As regards the performance status, one patient had an Eastern Cooperative Oncology Group (ECOG) performance score of 0, 35 patients had an ECOG score of 1, and 3 patients had an ECOG score of 2. The median duration of follow-up was 38 months (range; 3~249). Patient characteristics are summarized in Table 1.

All the patients underwent tumor evaluation and staging work-up, including a complete history, general physical ex-

amination, chest radiograph, and head and neck examination with laryngoscopy. Neck CT and/or MRI was performed in 23 patients (59%). Esophagoscopy and/or esophagography was done in 14 patients (36%). For patients with adenocarcinoma, upper gastrointestinal series, esophagogastroduodenoscopy, and/or colon study were performed for evaluation of gastrointestinal tract. Random blind biopsies from nasopharynx, oropharynx, or hypopharynx were obtained in 10 patients (26%), and a biopsy of the palpable LN was performed in all the patients.

All the patients were retrospectively restaged according to the American Joint Committee for Cancer Staging.<sup>11)</sup>

Twelve patients were treated with radiation therapy alone (Group 1), 8 patients with neoadjuvant chemotherapy followed by radiation therapy (Group 2), and 19 patients with excisional biopsy (n=6) or neck dissection (n=12) and post-operative radiation therapy (Group 3). One patient in Group 3 had neoadjuvant chemotherapy prior to neck dissection. Of 13 patients who had neck dissection, 6 patients underwent radical neck dissection, 5 patients modified radical neck dissection, and 2 patients supraomohyoid neck dissection. No elective neck dissection was performed. Distribution of nodal stage according to treatment modality is shown in Table 2.

### 2. Radiation therapy

Patients were treated with either <sup>60</sup>Co  $\gamma$ -ray or 4~6 MV photon beams. In 29 patients (74%), elective mucosal irradiation was performed. In 21 patients, naso-oro-hypopharynx and neck were irradiated with bilateral parallel-opposed fields, and the lower neck and supraclavicular LN with matched anterior

Table 1. Patient Characteristics

Variable	No. of patients	
Age	<60 yr	24
	≥60 yr	15
Sex	Male	31
	Female	8
Performance status*	0	1
	1	35
	2	3
Stage	N1	5
	N2A	7
	N2B	19
	N2C	4
	N3	4
Histology	Squamous cell carcinoma	27
	Undifferentiated carcinoma	8
	Adenocarcinoma	4
Level	I	1
	II	24
	III	13
	IV	14
	V	9
	VI	1

\*eastern cooperative oncology group score

Table 2. Distribution of Nodal Stage according to Treatment Modality

Stage	RT*	EXC <sup>†</sup> +RT	ND <sup>‡</sup> +RT	CTX <sup>§</sup> +RT	Total
N1	2	1	1	1	5
N2A	2	2	1	2	7
N2B	4	3	9	3	19
N2C	1	0	1	2	4
N3	3	0	1 <sup>  </sup>	0	4
Total	12	6	13	8	39

\*radiation therapy, <sup>†</sup>excision, <sup>‡</sup>neck dissection, <sup>§</sup>chemotherapy, <sup>||</sup>this patient received neoadjuvant chemotherapy prior to neck dissection

one field. In 8 patients, pharyngeal axis and upper neck were treated with bilateral parallel-opposed fields. In 10 patients, only neck was irradiated: 4 patients received RT to the bilateral neck, and 6 patients to the ipsilateral neck alone. Eight patients received elective neck irradiation to the whole neck except 2 patients with supraclavicular LN involvement, who received radiation to the involved neck. The median dose was 60 Gy at 1.75-2 Gy/fx in patients treated with surgical resection including excision or neck dissection (range; 54~70). The median dose was 65.2 Gy at 1.75~2 Gy/fx in patients treated without surgical resection (range; 50.4~73.8).

### 3. Chemotherapy

Nine patients received neoadjuvant chemotherapy before radiation therapy. Five of 9 patients received a median 3 cycles (range; 2~5) of 5-fluorouracil and cisplatin. Four patients were treated with various regimens of chemotherapy: 2 patients had bleomycin, vincristine, mitomycin-C, and cisplatin; one patient received bleomycin, 5-fluorouracil, and picibanil; and another one patient was given futraful and methyl-CCNU. But, these 4 patients received only one cycle of such regimen of chemotherapy.

### 4. Statistics

The actuarial survival rates were calculated using the Kaplan-Meier method, and statistical significance was evaluated by the log-rank test.<sup>12)</sup>

## Results

### 1. Response to treatment

Response to chemotherapy was available in 7 patients. Among 5 patients who received 5-fluorouracil and cisplatin, 2 patients attained complete remission (CR), and 3 patients attained partial remission (PR). Both patients treated with bleomycin, vincristine, mitomycin-C, and cisplatin attained stable disease (SD).

Response to radiation therapy was determined at the end of radiation therapy. Two patients with SD after chemotherapy achieved PR with radiation therapy. Two of 3 patients with PR reached CR after radiation therapy, and one patient remained PR despite radiation therapy. Two patients with CR after chemotherapy maintained CR. For remaining 2 patients

whose response to chemotherapy was unavailable, the response to radiation therapy was PR in one patient, and CR in the other patient.

Overall, 8 patients attained CR, 11 attained PR, and one patient had stable disease.

### 2. Patterns of failure

Regional recurrences were observed in 11 patients. Of these, 3 were true recurrences and 8 were persistent diseases. No out-of-field failures were observed.

One nodal failure was found simultaneously with the axillary LN metastases. And one patient manifested the primary tumor (lung) in the course of radiation therapy to the cervical LN, and the neck was not controlled.

Distant metastases below the clavicle occurred in 4 patients, and the sites of failure were as follows: axillary LN in 2 patients; bone in one patient; liver in one patient.

Four patients manifested a primary tumor. There were 3 cancers in lung and one in esophagus. As for the level of involved LN in these patients, lower cervical LN (level VI) was involved in 3 patients, and level III in one patient. As for the histologic type, all had squamous cell carcinoma.

The patterns of failure according to the treatment modality are listed in Table 3.

### 3. Survival

The 5-year overall survival rate of all the patients was 55%. The overall survival curve using Kaplan-Meier method is

Table 3. Patterns of Failure according to Treatment Modality

1st site of failure	RT*	EXC <sup>†</sup> +RT	ND <sup>‡</sup> +RT	CTX <sup>§</sup> +RT	Total
Neck	5	1	0	3	9
Primary	1	0	1	1	3
Neck and primary	0	0	0	1	1
Distant metastasis	1	0	1	1	3
Neck and distant metastasis	0	0	1	0	1
No. of failures/ No. of total pts	7/12	1/6	3/13	6/8	17/39

\*radiation therapy, <sup>†</sup>excision, <sup>‡</sup>neck dissection, <sup>§</sup>chemotherapy

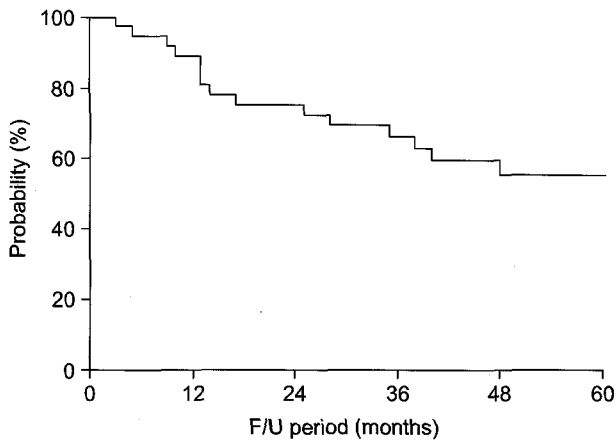


Fig. 1. Overall survival curves using Kaplan-Meier method.

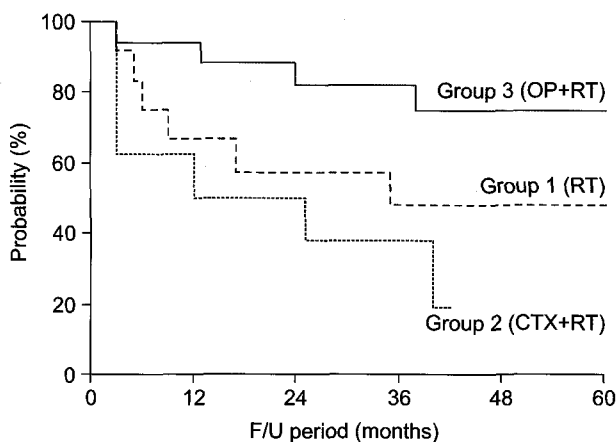


Fig. 2. Disease-free survival curves according to the treatment modality (OP: excision or neck dissection, RT: radiation therapy, CTX: chemotherapy).

shown in Fig. 1.

The 5-year overall survival rate of Group 1, 2, and 3 were 48%, 29%, and 68%, respectively ( $p=0.2197$ ). The 5-year disease-free survival rate of Group 1, 2, and 3 were 48%, 19%, and 75%, respectively ( $p=0.0324$ ). Between Group 1 and Group 2, the difference in disease-free survival did not reach statistical significance ( $p=0.3047$ ). In contrast, the difference was statistically significant between Group 1 and Group 3 ( $p=0.0203$ ). The disease-free survival curve according to the treatment modality is shown in Fig. 2.

**4. Prognostic factors**

A univariate analysis using the Kaplan-Meier product limit method confirmed that significant prognostic factors for overall survival included the appearance of primary site ( $p=$

Table 4. Univariate Analysis for Overall and Disease-free Survival

Variable	p-value	
	Overall survival	Disease-free survival
Age	0.9096	0.3799
Sex	0.6057	0.3288
Histology (squamous vs. non-squamous)	0.7092	0.4821
N Stage (N1 vs. N2-3)	0.3901	0.9568
Treatment modality	0.2197	0.0324
Appearance of primary	0.0038	0.0085

0.0038).

For disease-free survival, treatment modality ( $p=0.0324$ ), and the appearance of primary site ( $p=0.0085$ ) were statistically significant prognosticator (Table 4).

**5. Complications**

Acute treatment-related complications were evaluated using the Radiation Therapy Oncology Group criteria.<sup>13)</sup> Five patients complained of grade 1 and 2 esophagitis, respectively. Grade 1 xerostomia was developed in 7 patients. Eleven patients had grade 1~2 skin desquamation, and 3 of them had treatment interruption. Three patients had middle ear effusion. Five patients had grade 1 lymphedema of submental area.

As late treatment-related complications, the majority of patients who received radiation therapy to the pharyngeal axis reported varying degrees of xerostomia. Three patients had submental lymphedema and laryngeal edema, respectively. Late neck fibrosis was documented in 3 patients, who had neck dissection. Two patients showed Lhermitte's sign at 4 and 6 months after RT, respectively.

**Discussion**

Treatment of patients with MUO has been discussed extensively. It has been generally accepted that N1 disease without extracapsular extension has low risk of recurrence and can be treated with neck dissection or excision alone.<sup>3-5)</sup> As for  $\geq N2$  disease, Marcial-Vega et al. has showed the combined surgery and adjuvant radiation therapy is crucial.<sup>6)</sup> However, the surgical procedure varied from excisional biopsy

to radical neck dissection. Some investigators have reported the excellent regional control of excision+radiation therapy,<sup>5,10,14</sup> although contradictory data also exist.<sup>15,16</sup> Of course, most of the patients who received excision+radiation therapy had N1-2 disease. In our study, 5 of 6 patients treated with excision followed by radiation therapy attained regional control. Of 6 patients, 5 were of N2 disease. One patient with recurrence was staged as N2B initially. Based on these results, more conservative approach such as excision+radiation therapy is feasible in N2 disease.

Surgical resection (excision or neck dissection) and post-operative radiation therapy achieved superior disease-free survival to the non-surgical method in our study. This resulted partly from the distribution of more advanced disease in the non-surgical arm. Radiation therapy alone can only cure a small portion of these patients. Adding concurrent or neoadjuvant chemotherapy to radiation therapy, DeBraude et al. reported improved regional control and overall survival.<sup>17</sup> In our study, 4 of 8 patients who received chemotherapy gained regional control. Compared with radiation therapy alone (Group 1), the addition of chemotherapy (Group 2) improved regional control ( $p=0.6844$ , data were not shown) nor the overall survival ( $p=0.6968$ , data were not shown). Rather, Group 2 showed inferior disease-free survival than Group 1 though the difference was not statistically significant. Four patients in Group 2 received only one cycle of chemotherapy, due to no response in 2 patients and unknown reason in another 2 patients. Such suboptimal chemotherapy led to the delay of definitive radiation therapy, so Group 2 reported the most inferior result. With respect to distant metastasis, 3 patients experienced distant failure, and one of these 3 patients treated with chemotherapy previously. Because of the small patient number, the role of chemotherapy is inconclusive.

The appearance of the primary is another issue in MUO. Several authors demonstrated the reduction of the subsequent appearance of the primary in the irradiated area by elective mucosal treatment,<sup>8,10,15,16,18</sup> whereas others not.<sup>3,6,7</sup> In our study, all the primary sites appeared in the thorax, not in the head and neck. This is partly due to the elective mucosal irradiation. Even in patients who received radiation therapy to the neck alone, significant part of hypopharynx and oropharynx was also irradiated. And, the level of involved LN seemed to be related with the location of the primary. Jakob-

sen et al. reported the autopsy data of metastatic carcinoma of cervical LN from an unknown primary. Ten of 37 patients had level IV involvement, and 5 of 18 whose primary tumor was identified had lung cancers.<sup>19</sup> Marcial-Vega et al. demonstrated that lung cancers appeared in 5 of 17 patients whose primary tumor identified within 5 years from initial treatment, and 18% of their population had level IV disease.<sup>9</sup> In the present study, 3 of 4 patients with their primary in the thorax had level IV involvement.

In conclusion, surgical resection and radiation therapy achieves superior disease-free survival compared to radiation therapy with or without chemotherapy. Excision can be considered feasible as a more conservative method for the treatment of MUO of N1-2 disease. Further investigation is needed for evaluation of the role of chemotherapy in the treatment of MUO.

## References

1. **ESMO Guideline Task Force.** ESMO minimum clinical recommendations for diagnosis, treatment and follow-up of cancers of unknown primary site (CUP). *Ann Oncol* 2001; 12:1057-1058.
2. **Million RR, Nicholas JC, Mancuso AA.** The unknown primary. In: Million RR, Cassisi NT, eds. *Management of Head and Neck Cancer: a Multidisciplinary Approach*, 2nd ed. Philadelphia: JB Lippincott, 1994:311-320.
3. **Coster JR, Foote RL, Olsen KD, et al.** Cervical nodal metastasis of squamous cell carcinoma of unknown origin: indications for withholding radiation therapy. *Int J Radiat Oncol Biol Phys* 1992;23:743-749.
4. **Wang RC, Goepfert H, Barber AE, Wolf P.** Unknown primary squamous cell carcinoma metastatic to the neck. *Arch Otolaryngol Head Neck Surg* 1990;116:1388-1393.
5. **Iganej S, Kagan R, Anderson P, et al.** Metastatic squamous cell carcinoma of the neck from an unknown primary: management options and patterns of relapse. *Head Neck* 2002;24:236-246.
6. **Marcial-Vega VA, Cardenes H, Perez CA, et al.** Cervical metastases from unknown primaries: radiotherapeutic management and appearance of subsequent primaries. *Int J Radiat Oncol Biol Phys* 1990;19:919-928.
7. **Weir L, Keane T, Cummings B, et al.** Radiation treatment of cervical lymph node metastases from an unknown primary: An analysis of outcome by treatment volume and other prognostic factors. *Radiother Oncol* 1995;35:206-211.
8. **Maulard C, Housset M, Brunel P, et al.** Postoperative radiation therapy for cervical lymph node metastases from an occult squamous cell carcinoma. *Laryngoscope* 1992;102:

884-890.

9. Davison BJ, Spiro RH, Patel S, Patel K, Shah JP. Cervical metastases of occult origin: the impact of combined modality therapy. *Am J Surg* 1994;168:395-399.
10. Colletier PJ, Garden AS, Morrison WH, Goepfert H, Geara F, Ang KK. Postoperative radiation for squamous cell carcinoma metastatic to cervical lymph nodes from an unknown primary site: outcomes and patterns of failure. *Head Neck* 1998;20:674-681.
11. American Joint Committee on Cancer (AJCC). AJCC Cancer Staging Handbook. 6th ed. New York: Springer-Verlag; 2002. p17-87.
12. Kaplan EL, Meier PI. A nonparametric estimation from incomplete observations. *J Am Statist Assoc* 1958;53:457-481.
13. Cox JD, Stetz J, Pajak TF. Toxicity criteria of the Radiation Therapy Oncology Group (RTOG) and the European Organization for Research and Treatment of Cancer (EORTC). *Int J Radiat Oncol Biol Phys* 1995;31:1341-1346.
14. Mack Y, Parsons JT, Mendenhall WM, Stringer SP, Cassisi NJ, Million RR. Squamous cell carcinoma of the head and neck: management after excisional biopsy of a solitary metastatic neck node. *Int J Radiat Oncol Biol Phys* 1993;25:619-622.
15. Reddy SP, Marks JE. Metastatic carcinoma in the cervical lymph nodes from an unknown primary site: results of bilateral neck plus mucosal irradiation vs. ipsilateral irradiation. *Int J Radiat Oncol Biol Phys* 1997;37:797-802.
16. Lefebvre JL, Coche-Dequeant B, Van JT, Buisset E, Adenis A. Cervical lymph nodes from an unknown primary tumor in 190 patients. *Am J Surg* 1990;160:443-446.
17. DeBraud F, Heilbrun LK, Ahmed K, et al. Metastatic squamous cell carcinoma of an unknown primary localized to the neck: advantages of an aggressive treatment. *Cancer* 1989;64:510-515.
18. Park IK, Yun CM, Kim JC. Radiotherapy for metastatic neck nodes from an unknown primary site. *J Korean Soc Ther Oncol* 1997;15:105-111.
19. Jakobsen J, Aschenfeldt P, Johansen J, Jorgensen K. Lymph node metastases in the neck from unknown primary tumour. *Acta Oncologica* 1992;31:653-655.

국문초록

원발병소 불명의 경부림프절 전이의 치료결과

서울대학교 의과대학 방사선종양학교실\*, 이비인후과학교실†, 내과학교실†, 서울대학교 의학연구원 방사선의학연구소§

김규보\* · 지의규\* · 우홍균\*§ · 김광현† · 성명훈† · 허대석† · 박찬일\*§

**목적:** 원발병소 불명의 경부림프절 전이의 치료는 각 기관들의 치료원칙에 따라 경부림프절청소술, 림프절 절제술, 방사선치료 및 항암화학치료 등 다양한 조합의 치료가 적용되고 있다. 저자들은 서울대학교병원에서 원발병소 불명의 경부림프절 전이의 치료성적을 분석하고자 하였다.

**대상 및 방법:** 1981년 7월부터 1999년 6월까지 서울대학교병원 방사선종양학과에서 근치적 또는 수술 후 방사선치료를 받은 39명의 환자들을 대상으로 후향적으로 분석하였다. 방사선치료가 12명에서, 선행항암화학요법 및 방사선치료가 8명에서, 수술 및 수술 후 방사선치료가 18명에서 시행되었고, 1명은 선행항암화학요법, 경부림프절청소술 및 수술 후 방사선치료를 받았다. 성별은 남자가 31명, 여자가 8명이었고, 연령의 중앙값은 55세였다.

**결과:** 전체 환자의 5년 생존율은 55%였다. 치료방법에 따라 분석해보았을 때, 수술+방사선치료가 방사선치료 단독 혹은 항암화학요법+방사선치료에 비해 우월한 5년 무병생존율을 보고하였다 (75% vs. 48% vs. 19%). 그 외에 원발병소 발현여부가 무병생존율에 유의한 영향을 주는 것으로 나타났다.

**결론:** 원발병소 불명의 경부림프절 전이의 치료에 있어서 수술적 절제술 및 방사선치료의 병용요법이 방사선치료±항암화학요법에 비해 우월한 무병생존율을 보여주었다. 항암화학요법의 효과에 대해서는 추가 연구가 요망된다.

**핵심용어:** 경부림프절 전이, 원발병소 불명, 방사선치료