

- 1 -

---

가 10 가

(exostosis)

10 가 4

10)

2

8)

4,5

2)

---

:

1

Tel: 02) 958-8369, Fax: 02) 964-3865, E-mail: CShan1129@khmc.or.kr

(cartilagenous cap)

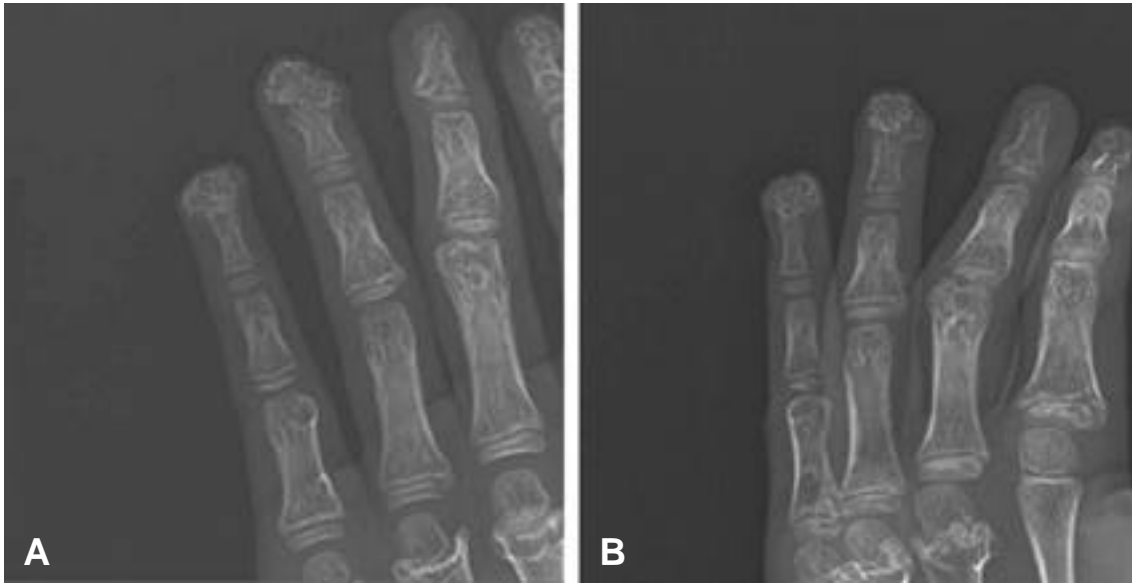
(Fig. 2).

4 0.5 cm × 0.3 cm

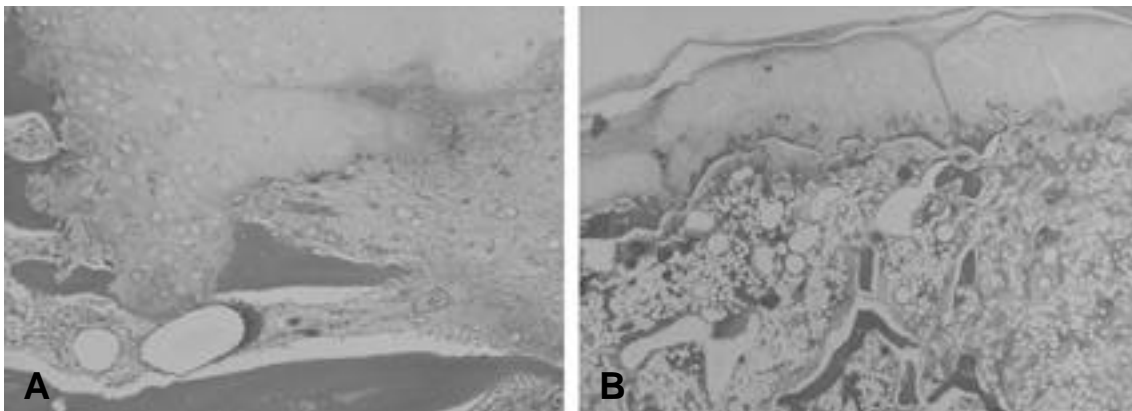
4

(Fig. 1).

2001 7  
4,5



**Fig. 1.** The preoperative anterior (A) and oblique (B) roentgenography of the right 4th,5th finger of 10 year-old male patient.



**Fig. 2.** The pathologic findings of biopsy specimen: The lesion is made up of mature bone tuberculae and cartilagenous cap (A. × 100, B. × 40, H&E)

1814 Boyer<sup>1)</sup>

가

<sup>11)</sup>

10

1

10 ~ 15%

<sup>5,6)</sup>

### REFERENCES

Solomon <sup>10)</sup> 7%

Keith <sup>7)</sup>

6

가

- 1) **Boyer A:** Traite des maladies chirurgicales et des operation qui leur conviennent. Paris: *ve Migneret*, 3: 594. 1814.
- 2) **Dick HM:** Bone tumors. In Green DP ed. Operative hand surgery. New York, *Churchill livingstone Inc:* 1682, 1982.
- 3) **Ganzhorn RW, Bahri G and Horowitz M:** Osteochondroma of the distal phalanx. *J Hand Surg*, 6-A(6): 625-626, 1981.
- 4) **Harris, H:** A sex-limiting modifying gene in diaphysical aclasis. *Ann. Eugen*, 14: 165-170, 1948.
- 5) **Iijima K, Kimura K, Kobayashi Y, Horiuchi Y, Ito Y and Uchinishi K:** Analysis of 310 cases of hand tumors mainly on giant cell tumor of tendon sheath.. *J Jpn Soc Surg Hand* 1: 248-252, 1984.
- 6) **Imakiire A, Miura Y, Komagata M, Kamoto K, Ishii T, Okabe T, et al:** Analysis of tumor of the hand for recent 10 years. *J Jpn Soc Surg Han*, 1: 241-247, 1984.
- 7) **Keith A:** Studies on the anatomical changes which accompany certain growth disorders of the human body. *J Anat*, 54: 101-115, 1920.
- 8) **McCornack EB:** The surgical management of hereditary multiple exostosis. *Orthop rev*, 10: 57, 1981.
- 9) **Moore JR, Cutis RM and Wilgis EFS:** Osteocartila-genous lesions of the digits in children: an experience with 10 cases. *J Hand Surg*, 8: 309-315, 1983.
- 10) **Solomon L:** Hereditary multiple exostosis. *Am. J Hum. Genet*, 16: 351, 1964.
- 11) **Solomon L:** Hereditary Multiple Exostosis. *J Bone and Joint Surg*, 45-B: 292, 1963.

Ganzhorn <sup>3)</sup>

1

(subungual exostosis)

가

(fibrocartilage cap)

가

(hyaline

cartilage cap)

가

가

가

<sup>9)</sup>

**Abstract**

**Hereditary Multiple Exostosis at Distal Tip of Distal Phalanx  
-A Case Report-**

**Chung Soo Han, M.D., Bi O Jeong, M.D., Man Ho Kim, M.D.**

*Department of Orthopaedic Surgery, School of Medicine, Kyung Hee University, Seoul, Korea*

---

Osteochondromas, which are uncommon in the hand, are encountered most frequently with hereditary multiple exostosis. They can occur away from the epiphyseal plate region at the distal end of the proximal and middle phalanges. But little has been written about exostosis that occur at the distal end of the distal phalnges.

We report one case of hereditary multiple exostosis that arose at the distal end of the distal phalnges. Complete excision was done and the patient was disease-free of 4 years follow-up

**Key Words:** Hand, Hereditary multiple exostosis, Osteochondroma.

---

**Address reprint requests to**

Chung Soo Han, M.D.

Department of Orthopaedic Surgery, School of Medicine, Kyung Hee University, Seoul, Korea

#1 Hoeki-dong, Dong Dae Mun-Ku, Seoul 130-702, Korea

TEL: 82-2-958-8369, Fax: 82-2-964-3865, E-mail: CShan1129@khmc.or.kr