

The effect of horizontal microgap location on the bone loss around 2-piece implants

Jae-Il Kim¹, Yong-Moo Lee^{1,2}, Byoung-Keon Yang¹, Young Ku^{1,2},
Chong-Pyoung Chung^{1,2}, Soo-Boo Han^{1,2}, In-Chul Rhyu^{1,2}

¹ Department of Periodontology, College of Dentistry, Seoul National University

² Dental REsearch Institute, College of Dentistry, Seoul National University

I. INTRODUCTION

The long-term success of endosseous implants depends mainly on integration between implant components and oral tissues, including hard and soft tissues. Maintenance of osseointegration and a steady state in marginal bone level are therefore imperative. However, initial breakdown of the implant-tissue interface generally begins at the crestal region even in successfully osseointegrated endosseous implants.¹⁻⁴ In particular, after the first year of function, crestal bone loss to or beyond the first thread of titanium screw implants, characterized by "saucerization", is often observed radiographically around 2-piece implants. In 1981, Adell et al.¹ reported an average of 1.2 mm marginal bone loss after loading. Thereafter, many investigations²⁻⁴ have shown that 2-piece titanium implants had 0.9 mm to 1.6 mm marginal bone loss from the first thread by the end of first year in function.

There is a lack of agreement as to why greater

bone loss occurred during healing and the first year of implant function than following years. Microgap in 2-piece implant and biologic width formation around endosseous implants seem to play an important role in marginal bone resorption. The influence of the microgap on the peri-implant tissue formation during healing was studied in dogs by Hermann et al.²⁵⁻²⁸ The results indicated that the crestal bone level is dependent on the location of the microgap in all 2-piece implants. The study suggested that epithelial proliferation to establish a biologic width could be responsible for the crestal bone loss about 2mm below the microgap.

Recently, there are some attempts to reduce marginal bone loss by supracrestal positioning of the implant collar.^{25-28,30,37} However, there is lack of data concerning the effect of horizontal change of microgap location on the bone loss around 2-piece implant. The aim of present study was to examine the effect on the marginal bone loss around 2-piece implants when the microgap shifts centrally to the

*This study was supported by Seoul National University Hospital(Grant #04-2003-050-0)

Corresponding author: Yong-Moo Lee, Department of Periodontology, College of Dentistry, Seoul National University, 28, Yongon-Dong, Chongno-Gu, 110-749, Seoul, Korea

center of implant by using smaller abutment than the regular-matched one.

II. MATERIALS AND METHODS

Five patients (2 women and 3 men with an average age of 52 years) were employed in this study. They are generally healthy patients, having no contradicting systemic disease to implant placement surgery. Mandibular posterior partial edentulous patients who needed at least 2 fixtures placed adjacently each other in the same edentulous site were selected. Cases in which additional surgical procedures such as bone graft or GBR were needed was excluded from this study.

Patients were given a local anesthetic (lidocaine with 1:100,000 epinephrine). Midcrestal incisions were made, and full-thickness mucoperiosteal flaps were reflected, exposing the underlying bone. Preparation of implant sites and placement of implants were performed as described by Adell et al.¹ A total of 15 Osseotite XP 4/5 implants (*3I, Implant innovations, Palm Beach, FL*) were placed into the prepared sites in one surgical steps. Implants were placed initially with the upper implant shoulder margin located at the height of alveolar bone crest (Figure 2). When it was difficult to locate the entire upper implant shoulder margin at the height of alveolar crest exactly due to bone curvature or local anatomic situations, we located the one side of implant upper shoulder, mesial or distal side, at the alveolar crest level and only that side was included in statistical evaluation.

One standard diameter and one wide diameter healing abutment were allocated without any preference to the site where the two adjacent fixtures had been installed (Figure 3). However, for the case that more than two fixtures were inserted, we chose both types of abutment evenly for the remaining fix-

tures. Seven wide diameter and 8 standard diameter of healing abutment was used. All of healing abutments protruded a minimum of 1 mm coronal to the flap margins. The mucosal flap margins were carefully adapted around the healing abutments using interrupted sutures (Figure 4). Periodontal pack was placed if necessary.

During 3 months healing period, patients received a periodic recall check for plaque control and oral hygiene instruction.

After 3 months healing period, the prosthetic procedure was done (Figure 8). In each group, the prosthetic procedure was carried out with same size of prosthetic components with healing abutment. In the group of standard healing abutment (S group), we did prosthetic procedure with standard diameter impression coping and prosthetic abutment (Figure 9). In the group of wide healing abutment (W group), wide diameter impression coping and prosthetic abutment was used. As a result, the microgap was centrally shifted 0.5mm in S group as compared to W group. This is the result of difference in diameter between upper implant shoulder and lower facing margin of abutments for upper implant shoulder. Around 1 month of time was spent for prosthetic procedures.

1. Radiographic evaluation

Standardized radiographs were taken immediately following fixture installation (Figure 5), 3 months later, just before prosthetic procedure (Figure 7), and at the delivery of final prosthesis (Figure 9). The long-cone parallel technique was applied so that implant threads were clearly visible. When deviation from a proper parallel implant projection was observed, the radiograph was redone during same visit. The radiographs were evaluated with regard to the alteration of the mesial and distal alveolar bone

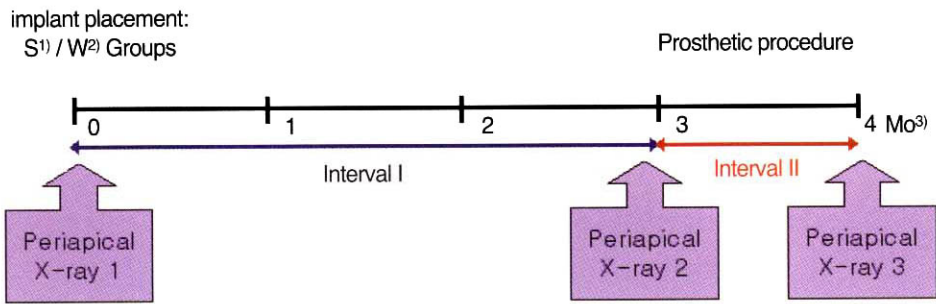


Figure 1. Experimental sequence

- 1) standard diameter healing abutment application groups
- 2) wide diameter healing abutment application group
- 3) months

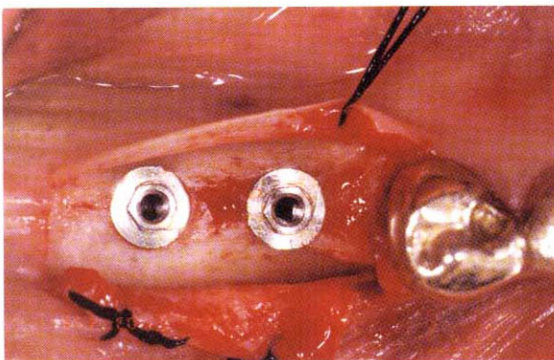


Figure 2. Two Osseotite XP 4/5 were placed with the upper shoulder margin located at the height of alveolar crest.

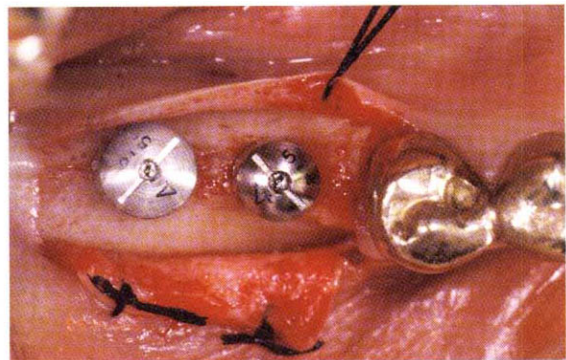


Figure 3. One standard diameter and one wide diameter healing abutment were allocated without any preference to the site.

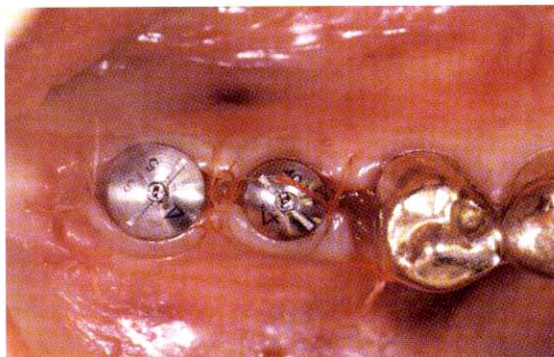


Figure 4. The mucosal flap margins were carefully adapted around the healing abutments.

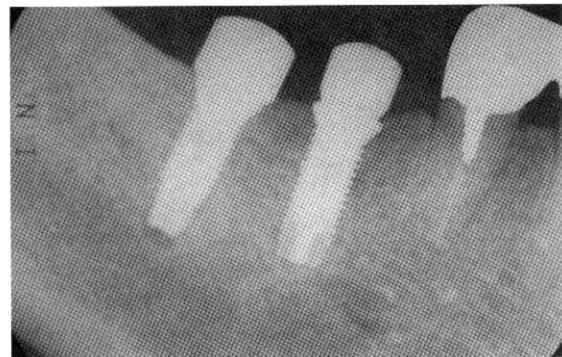

Figure 5. Periapical x-ray was taken immediately following implant placement. Note the step between implant shoulder and healing abutment in the right implant for first molar.

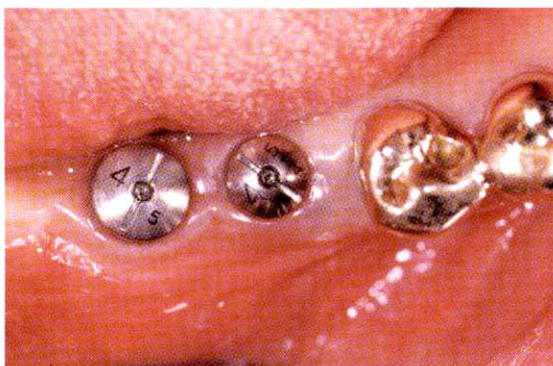

Figure 6. Three months later following implant placement

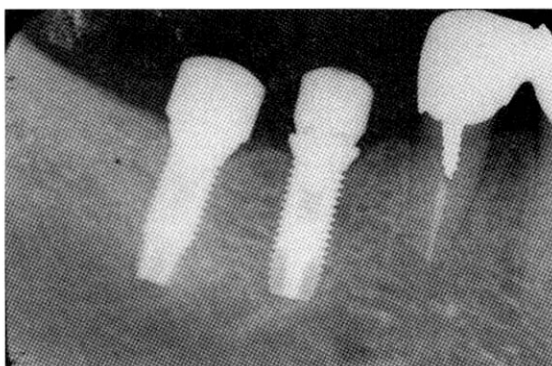


Figure 7. Periapical x-ray taken after 3 months healing period

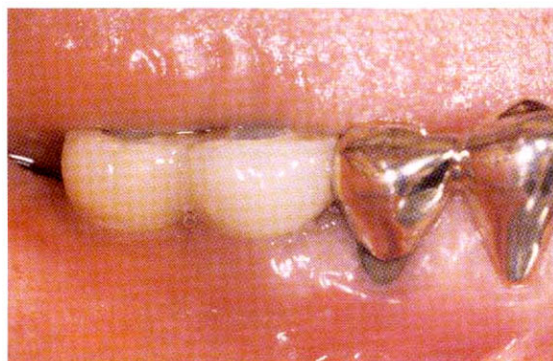

Figure 8. At the time of prosthesis delivery

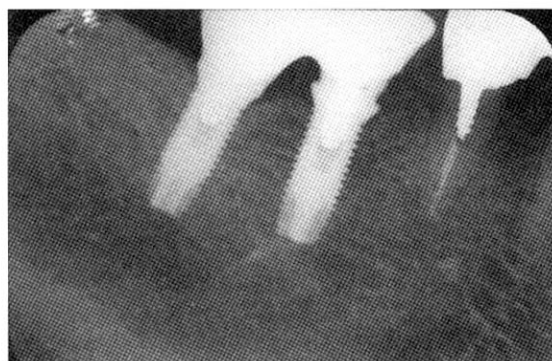


Figure 9. Periapical x-ray immediately after the delivery of final prosthesis

levels at the different observation intervals, i. e., the interval between the fixture installation and just before prosthetic procedure (Interval I), and the interval during prosthetic procedure (Interval II). TDI Scope Eye 3,0 (Techsan Co., Ltd) was used for assessment of bone level changes. The measured distance between the tips of the implant threads, which is always 0,7 mm in reality, was used as the basis for assessing and calibrating the radiographs. The marginal bone level was estimated with the upper implant shoulder margin as the baseline reference because implants had been placed initially with the upper implant shoulder margin located at

the height of the bone crest. The measurements from the radiographs were performed by one of the authors.

2. Statistical evaluation

The differences in the marginal bone loss of S and W group at each interval were evaluated by Mann-Whitney test. In each group, the marginal bone loss changes according to different intervals were evaluated by Wilcoxon signed rank test. The amount of marginal bone loss was expressed as a mean \pm standard deviation. Statistically significant differ-

Table 1. Radiographic bone loss (measured from upper implant shoulder margin to Marginal bone level) at different interval and groups

	Interval I	Interval I+II
W group	1,61 ± 0,79*	2,36 ± 0,30**
S group	1,58 ± 0,30	1,73 ± 0,42*

*: significant different at $P < 0,05$ - Mann-Whitney test

*: significant different at $P < 0,05$ - Wilcoxon signed rank test

ences were set at $P < 0,05$.

III. RESULTS

Table I shows radiographic bone loss in the experimental groups. During Interval I, W and S group did not show any significant difference in marginal bone level ($P > 0,05$). However, after interval I+II, W groups showed approximately 0,6 mm more marginal bone resorption than S group. The difference was statistically significant ($P < 0,05$).

Comparing the marginal bone resorption at each period, W group showed additional bone resorption during interval II, prosthetic procedures. However, In S group, the change of the marginal bone level was not statistically different between Interval I and Interval I+II ($P > 0,05$).

IV. DISCUSSION

The significance of the existence and location of a microgap between implant components is not fully understood. The reason for the reaction to the presence of a microgap is not well-known, but it could be related to the presence of a contamination by bacteria present at the implant-abutment interface,¹⁸⁻²⁴ micromovement of the implant-abutment interface^{29,30} and mechanical disruption of the mucosal barrier.³²

Gaps and cavities have been described in 2-piece implants, even where good marginal fit of implant

components is present, and these hollow spaces can be a trap for bacteria that might cause inflammation in the peri-implant soft tissue. The existence of bacterial leakage both at the junction between the abutment and the fixture as well as along the abutment screw has been reported.¹⁸⁻²⁴ The microorganism found inside the implants might be associated with the bone loss observed during early healing period.²⁴

Recently, Hermann et al.²⁹ demonstrated that no significant difference in the amount of crestal bone could attributed to the size of the microgap, but welding the abutment to the implant with a laser resulted in a significantly lower bone resorption. They suggested that the movements between abutments and implants seemed to influence the crestal bone resorption. In this study, they disconnected and immediately tightened the abutments of 2-piece implants to imitate clinically as well as biologically important and relevant steps during implant treatment such as the placement of another cover screw/healing abutment and mounting of the impression cylinder, as well as the delivery of the temporary/final prosthetic component. According to Abrahamsson et al,³² the dis- and subsequent reconnection of the abutment component of the implant compromised the mucosal barrier and resulted in a more apically positioned zone of connective tissue and additional marginal bone resorption. They suggested that this may be the result of tissue reactions initiated to establish a proper biologic width of the

mucosal-implant barrier following the mechanical disruption of the mucosal barrier. So mechanical disruption of the mucosal barrier, in addition to microbial contamination and micromovement of implant-abutment interface, seemed then to influence the crestal bone resorption.

In present study, there are no statistically significant difference between W and S group in Interval I. The reasons for similar amount of bone loss in each group are not fully understood. However, at least in part, this might be due to the difficulties in adapting the mucoperiosteal flaps to the abutments piercing the mucosa and to the consequent bone surface denudation in one stage surgery.³³⁻³⁵

In this study, W group, 2,36mm of bone loss occurred during interval I+II. This results were comparable Hermann's investigations that for all 2-piece implant the crestal bone level appeared dependent on the location of the microgap, approximately 2mm below the microgap.²⁵⁻²⁸ It is likely that the approximately 2mm of bone loss observed below a microgap is necessary to re-establish a biologic width with epithelium migrating below the microgap as was shown by Weber et al.¹³ and Hermann et al.²⁵⁻²⁸ and discussed by Cochran et al.¹⁴ In addition, 0,7mm of bone loss during interval II may be the result of mechanical disruption of the mucosal barrier.³²

In present study, the authors intentionally shifted the microgap centrally 0,5mm in S group by using smaller diameter abutments than the regular one. In this group, during interval I+II, 1,73mm of marginal bone resorption occurred. This resorption was less than 2mm of bone resorption that Hermann et al.²⁵⁻²⁸ reported. And S group showed 0,6mm lesser bone resorption than W group. This much bone loss was approximate to the amount of central microgap shift.

Within the limit of this study, central shift of

microgap using the smaller diameter of abutment than the regular one could reduce the marginal bone resorption in 2 piece implants. This may imply that the biologic width is not just vertical height, but length along the implant surface. Further studies employing the more subject population for a long period and histologic evaluations using animal model are needed to ascertain these findings.

V. Conclusions

With the limit of this study, central shift of microgap could reduce the marginal bone resorption in 2 piece implants.

VI. REFERENCES

1. Adell R, Lekholm U, Rockler B, Brånemark PI. A 15-year study of osseointegrated implants in the treatment of the edentulous jaw. *Int J Oral Surg* 1981;10:387-416
2. Buser D, Weber HP, Lang NP. Tissue integration of non-submerged implants. 1-year results of a prospective study with 100 ITI hollow-cylinder and hollow-screw implants. *Clin Oral Implant Res* 1990;1:33-40
3. Jemt T, Lekholm U, Grondhal K. A 3-year follow-up study of early single implant restoration ad modum Brånemark. *Int J Periodontics Restorative Dent* 1990;10:341-349
4. Cox JF, Zarb GA. The longitudinal clinical efficacy of osseointegrated dental implants: A 3-year report. *Int J Oral Maxillofac Surg* 1986;15:39-52
5. Adell R, Eriksson B, Lekholm U, Brånemark PI, Jemt T. A long-term follow-up of osseointegrated implants in the treatment of totally edentulous jaws. *Int J Oral Maxillofac Implants* 1990;5:347-359
6. Zarb GA and Schmitt A. The longitudinal clinical

- effectiveness of osseointegrated dental implants: The Toronto study. Part I: Surgical results. *J Prosthet Dent* 1990;63:451-457
7. Zarb GA and Schmitt A. The longitudinal clinical effectiveness of osseointegrated dental implants: The Toronto study. Part II: The Prosthetic results. *J Prosthet Dent* 1989;64:53-61
 8. Zarb GA and Schmitt A. The longitudinal clinical effectiveness of osseointegrated dental implants in anterior partially edentulous patients. *Int J Prosthodont* 1993;6:180-188
 9. Zarb GA and Schmitt A. The longitudinal clinical effectiveness of osseointegrated dental implants in posterior partially edentulous patients. *Int J Prosthodont* 1993;6:189-196
 10. Schmitt A and Zarb GA. The longitudinal clinical effectiveness of osseointegrated dental implants for single-tooth replacement. *Int J Prosthodont* 1993;6:197-202
 11. Albrektsson T, Zarb G, Worthington P, Eriksson AR. The long-term efficacy of currently used dental implants: A review and proposed criteria of success. *Int J Oral Maxillofac Implants* 1986;1:11-25
 12. Smith D, Zarb G. Criteria for success of osseointegrated endosseous implants. *J Prosthet Dent* 1989;62:567-572
 13. Weber HP, Buser D, Donath K, Fiorellini JP, Doppalapudi V, Paquette DW, Williams RC. Comparison of healed tissues adjacent to submerged and non-submerged unloaded titanium dental implants. A histometric study in beagle dogs. *Clin Oral Implants Res* 1996;7:11-19
 14. Cochran DL, Hermann JS, Schenk RK, Higginbottom FL, Buser D. Biologic width around titanium implants. A histometric analysis of the implant-gingival junction around unloaded and loaded nonsubmerged implants in the canine mandible. *J Periodontol* 1992; 63:226-236
 15. Gargiulo AW, Wentz FM, Orban B. Dimensions and relations of the dentogingival junction in humans. *J Periodontol* 1961;32:261-268
 16. Oh T, Yoon J, Misch CE, Wang HL. The cause of early implant bone loss: Myth or Science? *J Periodontol* 2002;73:322-333
 17. Engquist B, strand P, Dahlgren S, Engquist E, Feldmann H, Grondahl K. Marginal bone reaction to oral implants: a prospective comparative study of Astra Tech and Bränemark system implants. *Clin Oral Implants Res* 2002;13:30-37
 18. Quirynen M, van Steenberghe D. Bacterial colonization of the internal part of two-stage implants. An in vivo study. *Clin Oral Implants Res* 1993;4:158-161
 19. Quirynen M, Bollen CML, Eyssen H, van Steenberghe D. Microbial penetration along the implant components of the Bränemark system. An invitro study. *Clin Oral Implants Res* 1994;5:239-244
 20. Persson LG, Lekholm U, Leonhardt A, Dahlen G, Lindhe J. Bacterial colonization on internal surfaces of Bränemark system implant components. *Clin Oral Implants Res* 1996;7:90-95
 21. Rimondini L, Marion C, Brunella F, Fini M. Internal contamination of a 2-component implant system after occlusal loading and provisionally luted reconstruction with or without a washer device. *J Periodontol* 2001; 72:1652-1657
 22. Jansen VK, Conrads G, Richter EJ. Microbial leakage and marginal fit of the implant-abutment interface. *Int J Oral Maxillofac Implants* 1997; 12:527-540
 23. Piatelli A, Scarano A, Paolantonio M. Fluids and microbial penetration in the internal part of cement-retained versus screw-retained implant-abutment connections. *J Periodontol* 2001;72:1146-1150

24. Brogini N, McManus LM, Hermann JS, Mendina RU, Oates TW, Schenk RK, Buser D, Mellonig JT, Cochran DL. Persistent acute inflammation at the implant-abutment interface. *J Dent Res* 2003;82(3):232-237
25. Hermann JS, Cochran DL, Nummikoski PV, Buser D. Crestal bone changes around titanium implants. A radio-graphic evaluation of unloaded non-submerged and submerged implants in the canine mandible. *J Periodontol* 1997;68:1117-1130
26. Hermann JS, Buser D, Schenk RK, Higginbottom FL, Cochran DL. Biologic width around titanium implants. A physiologically formed and stable dimensions over time. *Clin Oral Implants Res* 2000;11: 1-11
27. Hermann JS, Buser D, Schenk RK, Cochran DL. Crestal bone changes around titanium implants. A histometric evaluation of unloaded non-submerged and submerged implants in the canine mandible. *J Periodontol* 2000;71:1412-1424
28. Hermann JS, Buser D, Schenk RK, Schoolfield JD, Cochran DL. Biologic width around one- and two-piece titanium implant. A histometric evaluation of unloaded non-submerged and submerged implants in the canine mandible. *Clin Oral Implants Res* 2001;12:559-571
29. Hermann JS, Schoolfield JD, Schenk RK, Buser D, Cochran DL. Influence of the size of the microgap on crestal bone changes around titanium implants. A histometric evaluation of unloaded non-submerged implants in the canine mandible. *J Periodontol* 2001;72:1372-1383
30. Piattelli A, Vrespa G, Petrone G, Iezzi G, Anibaldi S, Scranò A. Role of the microgap between implant and abutment: A retrospective histologic evaluation in monkeys. *J Periodontol* 2003;74:346-352
31. Berglundh T, Lindhe J. Dimension of the peri-implant mucosa. Biologic width revisited. *J Clin Periodontol* 1996;23:971-973
32. Abrahamsson I, Berglundh T, Lindhe J. The mucosal barrier following abutment dis/reconnection. An experimental study in dogs. *J Clin Periodontol* 1997;24:568-572
33. Ericsson I, Nilner K, Klinge B, Glantz P-O. Radiographical and histological characteristics of submerged and nonsubmerged titanium implants. An experimental study in the Labrador dog. *Clin Oral Implants Res* 1996;7:20-26
34. Ericsson I, Randow K, Glantz P-O, Lindhe J, Nilner K. Clinical and radiographical features of submerged and nonsubmerged titanium implants. *Clin Oral Implants Res* 1994;5: 185-189
35. Becker W, Becker BE, Israelson H, Lucchini JP, Handelsman M, Ammons W, Rosenberg E, Rose L, Tucker LM, Lekholm U. One-step surgical placement of Brånemark implants: A prospective multicenter clinical study. *Int J Oral Maxillofac Implants* 1997;12:454-462
36. Zitzmann NU, Scharer P, Marinello CP. Long-term results of implants treated with guided bone regeneration: a 5-year prospective study. *Int J Oral Maxillofac Implants* 2001;16:355-366
37. Davarpanah M, Martinez H, Tecucianu J-F. Apical-coronal implant position: recent surgical proposals. technical note. *Int J Oral Maxillofac Implants* 2000;15:865-872

2-piece 임플란트에서 미세 간극의 수평적 위치 변화에 따른 골 소실 비교 연구

김재일¹, 이용무^{1,2}, 양병근¹, 구 영^{1,2}, 정종평^{1,2}, 한수부^{1,2}, 류인철^{1,2}

¹ 서울대학교 치과대학 치주과학교실

¹ 서울대학교 치과대학 치학연구소

2-piece 임플란트에서는 초기 치유 기간 동안 0.9-1.6mm의 골 소실이 일어나는데 2-piece 임플란트의 미세 간극과 그에 따른 생물학적 폭경의 형성이 중요한 원인이다. 최근 수직적으로 미세 간극의 위치를 변화시킴으로 골 소실의 양을 줄일 수 있다는 보고가 있다. 이번 실험의 목적은 미세 간극의 수평적 위치 변화에 따른 골 소실의 양을 비교하는데 있다.

하악에서 인접하여 최소 2개의 임플란트를 식립할 수 있는 7 무치악 부위에 총 15개의 Osseotite XP 4/5를 식립하였다. 이때 임플란트의 상연이 주위 치조골과 일치하게 식립하였고 무작위로 선택하여 한 그룹(W 군)에서는 wide diameter healing abutment를 연결하였고 다른 한 그룹(S 군)에서는 standard diameter healing abutment를 연결하였다. 3개월의 치유 기간후 보철 과정을 시작하였으며 이 때 healing abutment와 같은 크기의 prosthetic component를 이용하였다.

임플란트 식립 직후, 3개월의 치유 기간이 지난 보철 직전(Interval I)에, 보철 과정 직후(Interval II)에 각각 치근단 방사선 사진을 찍어 각 단계에서의 골 소실 양을 비교하였다.

W 군의 경우 골 소실의 양이 Interval I에서 1.60 ± 0.78 , Interval I+II에서 2.36 ± 0.29 이었고 S 군에서는 Interval I에서 1.5810 ± 0.3030 , Interval I+II에서는 1.7346 ± 0.4199 이었다. W군에서는 Interval I와 I+II에서의 골 소실 양이 통계학적으로 유의할 만한 차이를 보였으며, Interval I+II에서의 W 군과 S 군에서의 골 소실 양도 통계학적으로 유의할 만한 차이를 나타내었다.

Interval I에서는 두 그룹에서 골 소실의 차이가 없었는데 이는 1 stage surgery시 healing abutment 주위로 mucoperiosteal flap 접합의 어려움 때문으로 생각된다. 한편 Interval II에서는 abutment manipulation 등의 과정이 추가적인 골 소실을 야기한 것으로 생각된다. Interval I+II에서 W 군과 S 군 사이의 골 소실 양 차이는 미세 간극의 수평적 위치 변화의 양과 유사한 결과를 나타내었는데 이로 미루어 미세 간극의 수평적 이동은 임플란트 주위의 골 소실 양에 영향을 미칠 수 있다고 생각된다.

주요어: 미세간극, 수평적 위치변화, 생물학적 폭경, 골소실