

구강악안면수술을 위한 악하 기관 삽관 - 증례보고 -

강릉대학교 치과대학 구강악안면외과학교실 및 구강과학연구소

김 성 민 · 권 광 준

Abstract

Submental Intubation for Maxillofacial Surgery

- A Case Report -

Soung-Min Kim and Kwang-Jun Kwon

Department of Oral & Maxillofacial Surgery and Research Institute of Oral Science, College of Dentistry, Kangnung National University, Gangneung, Korea

구강저를 통한 기관내 삽관은 1986년 Altemir에 의해 처음 소개된 바 있는데 그 후 1993년 Hoenig 와 Braun 및 같은 해 Stoll 등에 의해서나, 또는 1996년 Prochno 등에 의해 계속 변형된 방법으로 문헌에서 기술되어 왔다. 이 방법은 치과 영역 특히 구강악안면외과의 외상 수술시 이상적인 교합을 얻기 위해 임시 상하악간 고정(intermaxillary fixation)을 할 수 있고 중앙모 골절(midface fracture)의 회복을 위한 비관 삽관의 불편함을 피할 수 있는 유리한 점이 있으며, 또한, 정복 및 고정술이 필요한 비골 골절(nasal bone fracture)에서나 두개기저골 골절(skull base fracture)에서 여러 감염 등 합병증을 피하기 위해 추천될 수 있다. 또한, 목 부위에 비심미적인 반흔을 만들게 되며 여러 합병증을 초래할 수 있는 기관절개술(tracheostomy)보다 유용할 수 있다.

본 증례보고에서는 교통사고로 두개기저부 골절을 동반한 심한 중앙모 골절 환자에서 적용시킨 경우를 알아보고, 아울러 이러한 악하부 삽관의 장, 단점 및 시술 과정 등에 대해 고찰해보고자 한다. (JKDSA 2004; 4: 96~99)

Key Words: Intermaxillary fixation, Midface fracture, Skull base fracture, Submental intubation, Tracheostomy

Endotracheal intubation through the floor of the mouth was first described by Hernandez Altemir in 1986 (Altemir, 1986). Since then there have been several articles in the literature describing and modifying the technique (Stoll et al, 1993; Prochno et al, 1996). This method allows temporary intermaxillary fixation to

achieve optimal occlusion and avoids interference of the endotracheal tube during the repair of the midface (Paetkau, 2000; Adamo, 1996; Katsnelson, 1994). And in the case of nasal intubation interfering with centralization and stabilization of nasal fractures or of the possibility of basal skull fracture, this technique is more useful than tracheotomies that result in a number of potential complications with esthetically poor scarring in a highly visible anterior neck.

This paper would be like to introduce the case of multiple skull base fracture patient, and also to review

책임저자 : 김성민, 강원도 강릉시 지번동 123
강릉대학교 치과대학 구강악안면외과학교실
우편번호: 210-702
Tel: +82-033-640-2468, 3139
Fax: +82-033-642-6410
E-mail: smin_kim@kangnung.ac.kr

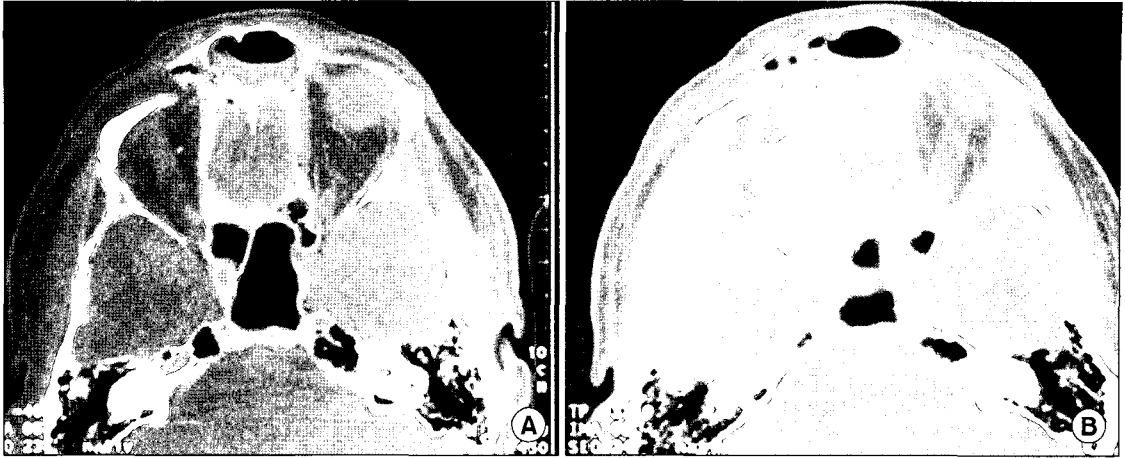

Fig. 1. The CT view of multiple maxillofacial bone fractures.

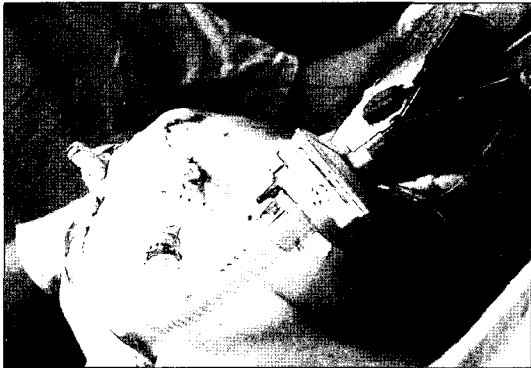


Fig. 2. The fixation state of submental intubation.

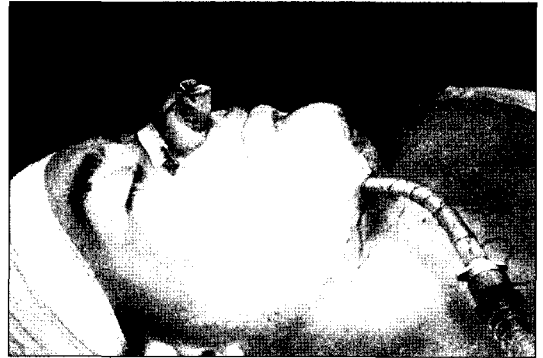

Fig. 3. With submental intubation, Nasal bone fracture was corrected with intermaxillary fixation at the same time.

the advantage, disadvantage and the procedures of the submental intubation.

Case Report

A 28-yr-old man in an automobile accident with multiple maxillofacial injuries, cerebral concussion and cervical spine fractures was delivered at the emergency department at the Regensburg University Hospital in Germany (Fig. 1). At first, he had been orally intubated shortly after arrival at the emergency department and his lungs were ventilated.

He was scheduled for repair of the maxillofacial

fractures and, because intermaxillary fixation was needed with nasal bone reduction, he would be decided with a submental approach for endotracheal intubation. After general anesthesia, the another tube was repositioned via submental route (Fig. 2) with reinforced tube (Rush, Kemen-Rommelshausen Co., Germany).

After submental intubation, nasal bone fracture with ecchymosis was corrected at the same time (Fig. 3).

Discussion

The endotracheal intubation is necessary for the

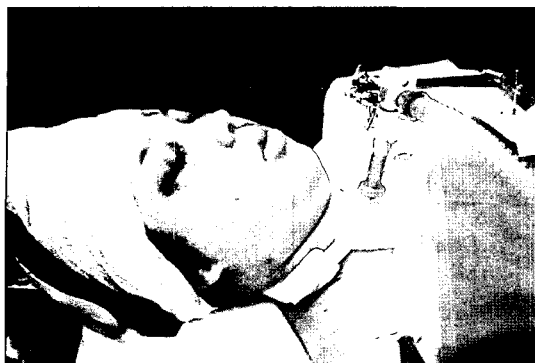

Fig. 4. The state of routine tracheostomy procedure.

routine procedures in oral and maxillofacial surgery, and the various method has been used as surgical intubation; preoxygenation, awake intubation, rapid sequence intubation, retrograde intubation, nasal intubation and submental intubation.

In the craniomaxillofacial trauma with basal skull fracture or panfacial fracture or severe facial bony deformities secondary to beta-thalassaemia major, multiple complications with a tracheostomy can be prevented by using the submental intubation (Mak and Ooi, 2002).

Extensive facial trauma surgery frequently requires intermaxillary fixation. In situations in which intermaxillary fixation is required and nasoendotracheal intubation is contraindicated, a cricothyrotomy or tracheostomy has been the traditional method of airway control. But additional surgery and potential complications associated with either a cricothyrotomy or tracheostomy would be happened as follows; formation of aesthetically poor scarring, thyroid isthmus bleeding, tracheotomy tube displacement, passage error, pneumothorax or pneumomediastinum formation, tracheocutaneous fistula or tracheal stenosis formation and subglottic larynx damages (Fig. 4). Temporary intermaxillary fixation with optimal occlusion is possible with submental intubation and the interference of the endotracheal tube during the midface repair is also advantages of submental intubation (Stranc and Skoracki, 2001).

But the disadvantages are also occurred, for example, damage of the lingual nerve, the marginal mandi-

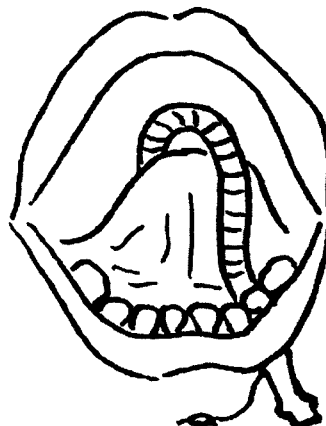


Fig. 5. Scheme of the pilot ballon and the end of the reinforced endotracheal tube, which are passed extraorally through the floor of the mouth.

bular branch of the facial nerve and the duct of the submandibular gland. And the rare cases of mucocutaneous fistulae or mucocoele formation and airway complication secondary to the submental edema were also reported (Ogata et al, 2001; Stranc and Skoracki, 2001). Green and Moore reported the submental endotracheal intubation with an endotracheal tube exchanger using two separate tubes (Drolet et al, 2000). After general anesthesia and placement of an oral endotracheal tube, a second endotracheal tube was introduced through a submental incision and subsequently substituted into the larynx. To minimize the apnea time and to minimize the cuff damage and make relatively small submandibular incision while passing the endotracheal tube through the submental passage, they removed and reconnected the plastic connector.

The routine procedures of submental intubation are as follows (Bennet and Spiro, 1999; Laplace et al, 1999);

1. A 2-cm submental skin incision is made parallel and medial to the inferior border of the mandible.
2. Blunt dissection with a hemostat is made along the medial surface of the mandible.
3. The dissection is carried through the skin, subcutaneous tissue, platysma muscle, mylohyoid muscle,

and mucosa.

4. The hemostat should penetrate the mucosa of the floor of the mouth at the junction of the attached and free mucosa.

5. A 2-cm mucosal incision that parallels the mandible is made at this junction.

6. The hemostat is spread to establish a channel through which to pass the endotracheal tube.

7. The connector to the endotracheal tube is removed and the hemostat grabs the end of the reinforced endotracheal tube from within the mouth.

8. The pilot balloon and the end of the reinforced endotracheal tube are then passed extraorally through the floor of the mouth (Fig. 5).

9. A reinforced endotracheal tube is required to accommodate the angulation of the tube through the floor of the mouth.

10. The connector is reattached and endotracheal position with bilateral breath sounds are confirmed.

11. The endotracheal tube is then secured to the skin in the submental region with a suture.

12. If intermaxillary fixation is not maintained and if postoperative ventilation is required, the submental intubation can be reconverted to an oral intubation.

13. And if intermaxillary fixation is maintained, the patient may be extubated in the operating room or postanesthesia care unit (PACU), as indicated through the submental site.

14. Submental skin closure is achieved once the tube is removed from the submental site.

airway management with pan-facial fractures: alternative approaches. *J Craniomaxillofac Trauma* 1996; 2: 30-5.

Altemir FH: The submental route for endotracheal intubation. A new technique. *J Maxillofac Surg* 1986; 14: 64-5.

Bennet J, Spiro J: Anesthetic considerations in the acutely injured patient. *Oral and Maxillofac Surg Clin Nor Am* 1999; 11(2): 185-201.

Drolet P, Girard M, Poirier J, Grenier Y: Facilitating submental endotracheal intubation with an endotracheal tube exchanger. *Anesth Analg* 2000; 90: 222-3.

Katsnelson T, Farcon E, Adamo AR: More on submandibular endotracheal intubation for panfacial fractures. *J Clin Anesth* 1994; 6: 527-8.

Laplace E, Aubert S, Giraud D, Labeyrie JL, Dandrau JP: Intubation par voie sous-mentale. *Ann Fr Anesth Reanim* 1999; 18: 913-5.

Mak PHK, Ooi RGB: Submental intubation in a patient with beta-thalassaemia major undergoing elective maxillary and mandibular osteotomies. *Br J Anaesth* 2002; 88: 288-91.

Ogata J, Minami K, Oishi M, et al: The influence of the laryngeal mask airway on the shape of the submandibular gland. *Anesth Analg* 2001; 93: 1069-72.

Paetkau DJ, Stranc MF, Ong BY: Submental orotracheal intubation for maxillofacial surgery. *Anesthesiology* 2000; 92: 912.

Prochno T, Dornberger I, Esser U: Management of panfacial fractures--also an intubation problem. *HNO* 1996; 44: 19-21.

Stoll P, Galli C, Wachter R, et al: Submandibular endotracheal intubation in panfacial fractures. *J Clin Anesth* 1994; 6: 83-6.

Stranc MF, Skoracki R: A complication of submandibular intubation in a panfacial fracture patient. *J Cranio Maxillofac Surg* 2001; 29: 174-6.

REFERENCES

Adamo AK, Katsnelson T, Rodriguez ED: Intraoperative