

A Case of Spontaneous Pneumomediastinum without Direct Cause

Sam Beom Lee, Jung Ho Kim, Byung Soo Do

*Department of Emergency Medicine
College of Medicine, Yeungnam University, Daegu, Korea*

Introduction

Spontaneous pneumomediastinum is a rare, self-limiting benign disease that usually occurs in young patients without an obvious precipitating factors (1). Emergency physicians may be encountered in diagnosis and treatment in the emergency department, and is occasionally be able to be considered as an emergency condition in some cases.

We would present our experience in treating a case of spontaneous pneumomediastinum without direct precipitating cause, he was a 15-year-old boy treated with conservative therapy.

Case

A 15-year-old boy presented with left chest discomfort for 12 hours not associated with pleuritic chest pain or dyspnea. He did not cough or vomit vigorously just before

this presentation. But it was aggravated by deep inspiration and radiated to the left shoulder. He did not suffer from other symptoms. He lately visited in emergency care center.

He did not have significant past medical history such as tuberculosis. There was no history of recent trauma, upper respiratory infection, or foreign body swallowing.

Vital signs were within the normal limit, blood pressure 130/80 mmHg, heart rate 60/minute, respiratory rate 18/minute, and body temperature 36.7°C.

Physical examinations were essentially normal except faintly audible mediastinal crunching sound at the left mid-precordium (Hamman's sign).

He was checked on blood gas analysis, chest X-ray, electrocardiogram, and computerized tomography (CT). Blood gas analysis showed pH 7.434, PaCO₂ 35.4 mmHg, PaO₂ 109 mmHg, base excess 0.8 mmol/L, HCO₃

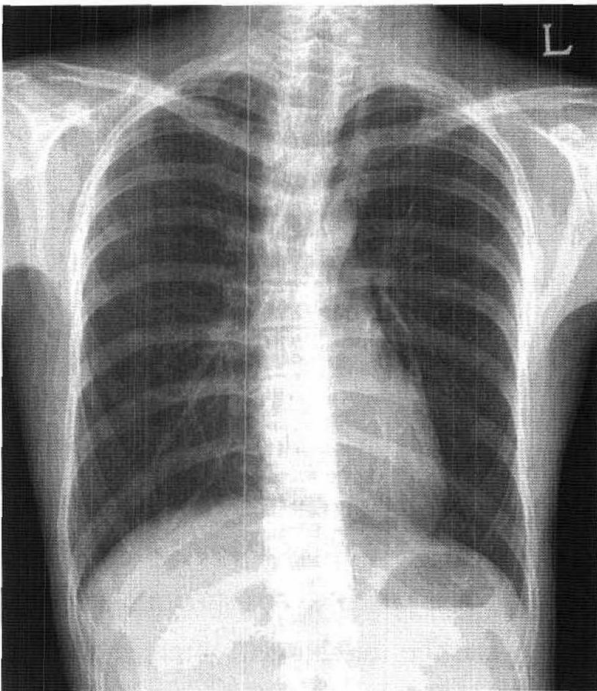


Fig. 1. Chest PA showed mediastinal air and “continuous diaphragm sign” and small amount of air in left pericardial space.

24 mmol/L, and O₂ saturation 98.4%. Chest X-ray showed the pneumomediastinum and small amount of pneumopericardium, but rib fracture, pneumothorax, and other visible active lung disease were not seen on this study (Fig. 1). Electrocardiogram showed no

evidence of ischemia or infarction such as ST changes, T inversion. Chest CT drip infusion study was taken by immediately and showed the pneumomediastinum with extending to interstitium, but visible bullae or pneumothorax were not seen (Fig. 2).

And also he immediately underwent a esophagoscopy, which did not demonstrate the evidence of esophageal perforation.

He was placed on oxygen by nasal catheter, and the following day, he did not complain such symptoms any more and the follow-up chest X-ray showed that the pneumomediastinum had began to resolve. So he was discharged that day without admission.

Discussion

Spontaneous pneumomediastinum is rare disease or condition and usually occurs in young patients without an apparent precipitating factor or disease (1).

Hamman (2) first described spontaneous

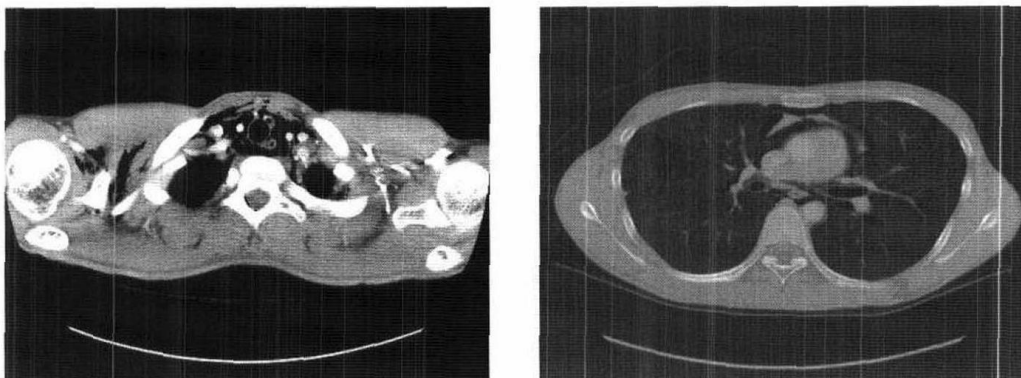


Fig. 2. Chest CT showed pneumomediastinum and pneumopericardium.

pneumomediastinum in 1939. His description of audible crepitation occurring with the heartbeat on chest auscultation is known as "Hamman's sign", which was present in 9 of 22 cases (1).

Pneumomediastinum results from the rupture of terminal alveoli into the lung interstitium and the dissection of air along the pulmonary vasculature toward the hilum, with eventual extravasation into the mediastinum (3). This theory could explain our case which not confirmed by precipitating cause.

Spontaneous pneumomediastinum is often reported to be the result of asthma, labor, diabetic ketoacidosis, Hodgkin's disease after irradiation, chemotherapy, coughing or forceful straining during exercise, Valsalva maneuver, etc, in the many literatures (4-10).

Classic symptoms include retrosternal chest pain, dyspnea, cough, cervical pain, but are not nonspecific. In our case, he only complained chest discomfort. Other symptoms include general weakness, dysphagia, back pain, sore throat, etc (11-15). Physical finding may include subcutaneous emphysema on the chest, back, or neck area (14). The precordial crunching sound described by Hamman (2) in 1939 can be audible at substernal area (Hamman's sign), which can be confused with the pericardial friction rub. Abolnik said that the precordial crunching sound was heard in 40% of his cases (16).

The presence of pneumomediastinum was

confirmed by chest X-ray films, and CT scan was performed to exclude any underlying lung disease such as bullous lung disease in our case. Esophagoscopy or esophagogram are essential to demonstrate esophageal perforation. Emergency physicians initially have to study this methods for differential diagnosis including pleural, pulmonary, cardiac, esophageal, and musculoskeletal causes (1,17, 18).

No special treatment is required in spontaneous pneumomediastinum and the patient can be discharged after short-term observation without admission. Supplemental oxygen therapy may be useful, and careful observation, bed rest, analgesics can be needed in most cases. Recurrence and complications are unusual because spontaneous pneumomediastinum is self-limiting condition in most cases (1,14,17).

-요약-

자연성 종격동 기종은 젊은 연령에서 주로 직접적인 이유가 없이 발생하는 흔치 않은 질환으로 응급실에서 급성 흉통의 원인으로 감별해야할 질환중의 하나이다. 간혹 응급상황이 발생하여 응급 처치를 받을 수 있다고 하지만 대부분에서 보존적인 치료로 호전이 되는 양호한 질환이기도 하다.

저자들은 15세 남자에게 특별한 유발 요인이 없이 발생하였고 입원치료 없이 응급의료센터에서 바로 퇴원한 자연성 종격동 기종 1례를 경험하였기에 문헌고찰과 함께 보고하는

바이다.

References

1. Michalis G, Kalliopi A, Nikolitsa K, Marios M: Spontaneous pneumomediastinum: A rare benign entity. *J Thorac Cardiovasc Surg* 126(3): 774-776, 2003.
2. Hamman L: Spontaneous mediastinal emphysema. *Bull Johns Hopkins Hosp* 64: 1-21, 1939.
3. Macklin MT, Macklin CC: Malignant interstitial emphysema of the lungs and mediastinum as an important occult complication in many respiratory diseases and other conditions: an interpretation of the clinical literature in the light of laboratory experiment. *Medicine* 23: 281-358, 1944.
4. Panacek EA, Singer AJ, Sherman BW, Prescott A, Ruther WF: Spontaneous pneumomediastinum: clinical and natural history. *Ann Emerg Med* 21: 67-72, 1992.
5. Beauchamps G: Spontaneous pneumothorax and pneumomediastinum. Pearson FG, Deslauriers J, Ginsberg RJ, Hiebert CA, McKneally MF, Urschel HC: *Thoracic surgery*. Churchill Livingstone, New York, 1995, pp. 1037-1054.
6. Weathers LS, Brooks WG, De Clue TJ: Spontaneous pneumomediastinum in a patient with ketoacidosis: a potential hidden complication. *South Med J* 88: 483-485, 1995.
7. Kim KI, Lee JW, Lee CH, Park SK: Polypoid endobronchial Hodgkin's disease with pneumomediastinum. *Br J Radiol* 72: 392-394, 1999.
8. Sikdar T, Macvivar D, Husband JE: Pneumomediastinum complicating bleomycin related lung damage. *Br J Radiol* 71: 1202-1204, 1998.
9. Partridge RA, Coley A, Bowie R, Woolard RH: Sports-related pneumothorax. *Ann Emerg Med* 30: 539-541, 1997.
10. Morgan EJ, Henderson DA: Pneumomediastinum as a complication of athletic competition. *Thorax* 36: 155-156, 1981.
11. Maunder R, Pierson D, Hudson L: Subcutaneous and mediastinal emphysema, pathophysiology, diagnosis, and management. *Arch Intern Med* 144: 1447-1453, 1984.
12. Dekel B, Paret G, Vardi A, Katz M, Barzilay Z: Torticollis: an unusual presentation of spontaneous pneumomediastinum. *Pediatr Emerg Care* 12: 352-353, 1996.
13. Frenkel M, Lyons L: Spontaneous pneumomediastinum: an unusual case of a sore throat. *Postgrad Med* 89: 257-259, 1991.
14. Munsell W: Pneumomediastinum, a report of 28 cases and review of the literature. *JAMA* 202: 689-693, 1967.
15. Stack B, Ridley M: Spontaneous cervical emphysema in a child. *Otolaryngol Head Neck Surg* 110: 318-323, 1993.
16. Abolnik I, Izidore S, Breuer R: Spontaneous pneumomediastinum: A report of 25 cases. *Chest* 100: 93-95, 1991.

17. Ralph-Edwards AC, Pearson FG: Atypical presentation of spontaneous pneumomediastinum. *Ann Thorac Surg* 58: 1758-1760, 1994.
18. Dosios T, Fytas A, Zarifis G: Spontaneous epidural emphysema and pneumomediastinum. *Eur J Cardiothorac Surg* 18(1): 123, 2000.
-