
난소의 성끈 종양을 닮은 자궁종양

-세포학적 소견 1에 보고-

고려대학교 의과대학 병리학교실

김 인 선 · 한 은 미 · 정 운 용 · 이 주 한 · 염 범 우

= Abstract =

Uterine Tumor Resembling Ovarian Sex-Cord Tumor

- A Case Report of the Cytologic Finding -

Insun Kim, M.D., Eun-Mee Han, M.D., Woon Yong Jung, M.D.,
Ju Han Lee, M.D., and Bum-Woo Yeom, M.D.

Department of Pathology, Korea University Medical College, Seoul, Korea

Uterine stromal tumors with features of ovarian sex-cord differentiation are relatively rare. The neoplasms composed of sex cord-like components in more than 50% of the tumor are classified as group II. We report the cytologic findings of a case of uterine tumor resembling ovarian sex-cord tumor. The cervical smears of a 62-year-old woman with submucosal tumor showed loose aggregates of spindle cells as well as glandular or tubular structures of round cells with a distinct cell membrane and a prominent small nucleolus. Because uterine stromal tumor can have sex cord differentiation, its possibility should be considered in the interpretation of cervical smears.

Key words: Stromal tumor, Uterus, Sex cord differentiation, Cervical smear

책임저자 : 김 인 선

주 소 : 80, Guro-dong, Guro-Ku, Seoul, Korea

전 화 : 82-2-818-6871

팩 스 : 82-2-818-6239

E-mail address : iskim@korea.ac.kr

INTRODUCTION

The cytologic findings of endometrial stromal sarcoma have been described in sputum,¹ body fluids,²⁻⁵ fine needle aspiration smears^{4,6-9} and touch imprints of the tumor.⁵ However, the difficulty in making a correct diagnosis of low grade endometrial stromal sarcoma has been emphasized in cervical smears because the tumor cells have a bland appearance and do not have cytologic features of malignancy.^{3-5,10}

Uterine tumor resembling ovarian sex cord tumor (UTROSCT) was first described by Clement and Scully.¹¹ These tumors are divided into two groups according to the proportion of the sex cord elements: those composed predominantly of endometrial stromal cells (group I) and those composed predominantly of sex cord elements, such as tubules, trabeculae and rosette (group II). According to the review of Hauptmann et al.,¹² 38 cases with UTROSCTs have been reported until 2001, however, there is no cytologic description of these tumors.

Recently, we experienced a case of UTROSCT, in which the cervical smear showed the cytologic features of the tumor representing its histologic counterpart.

CASE HISTORY

A 62-year-old woman, gravida 4, para 4, visited the hospital with complaints of vaginal bleeding on November 15, 2002. She had been treated for gastric adenocarcinoma by subtotal gastrectomy on July 19, 2001 and chemotherapy after that. At the time of admission, no evidence of recurrence was found. On ultrasonogram, her uterine cavity was distended with a heterogenous subserosal mass (Fig. 1). The cervical smear was interpreted as endometrial cells and the endometrial curettage was diagnosed as endometrial stromal tumor. Total abdominal hysterectomy and bilateral salpingo-oophorectomy were performed.

1. Cytologic Findings

The cervical smears were bloody and contained reactive squamous cells (Fig. 1) and multiple tumor cell

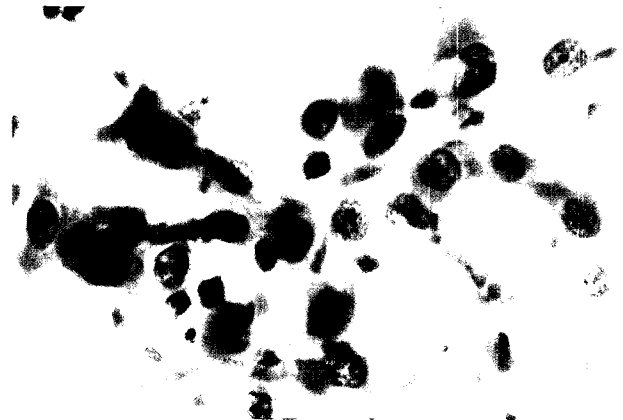

Fig. 1. Cytologic finding of cervical smear: Reactive squamous cells originating from cervix are seen. (Papanicolau)

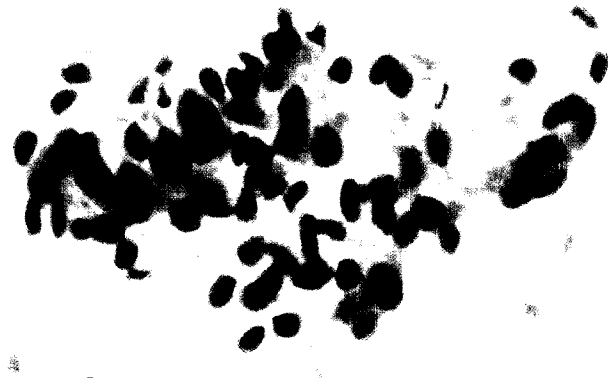

Fig. 2. Cytologic finding of cervical smear: The aggregate of short spindle cells with cytoplasmic process and oval to elongated nucleus are arranged in palisade. (Papanicolau)

clusters. The tumor cells in loose aggregates had short cytoplasmic process and oval nuclei arranged in palisade (Fig. 2). The tumor cells forming tubular structures had moderate amount of cyanophilic cytoplasm and round nucleus with fine chromatin and a small nucleolus (Fig. 3), whereas the tumor cells in clusters had less amount of cytoplasm, and more distinct nuclear membrane and a prominent nucleolus (Fig. 4). Some of the cells showed hyperchromatic nuclei and slight anisonucleosis. However, multinucleated or bizarre cells were not found.

2. Histologic Findings

The uterus was slightly enlarged with an 8cm-sized

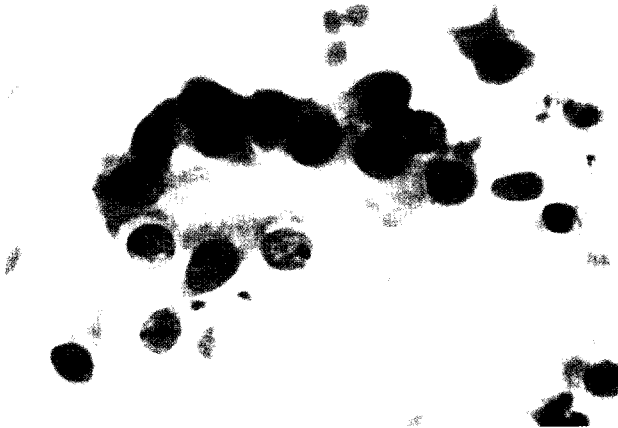

Fig. 3. Cytologic finding of cervical smear : The tubular structure is composed of epithelioid cells with moderate amount of cytoplasm and round nucleus with occasional small nucleolus. (Papanicolau)



Fig. 4. Cytologic finding of cervical smear : The round tumor cells in cluster have scanty cytoplasm and round nucleus with distinct nuclear membrane and a prominent nucleolus. (Papanicolau)

pedunculated submucosal mass attached to the fundus with stalk. On section, the mass was yellowish white and soft with multifocal hemorrhages. Microscopically, the endometrium was atrophic and the surface epithelium was composed of a single layer of cuboidal cells. The tumor was composed of diffuse sheets of round to spindle cells and scattered small tubules or large elongated tubules (Fig. 5A). In areas, the stroma was hyalinized and contained small tubules and irregular shaped, cleft-like structures lined by cuboidal cells, reminiscent of sex cord tubules (Fig. 5B). On higher

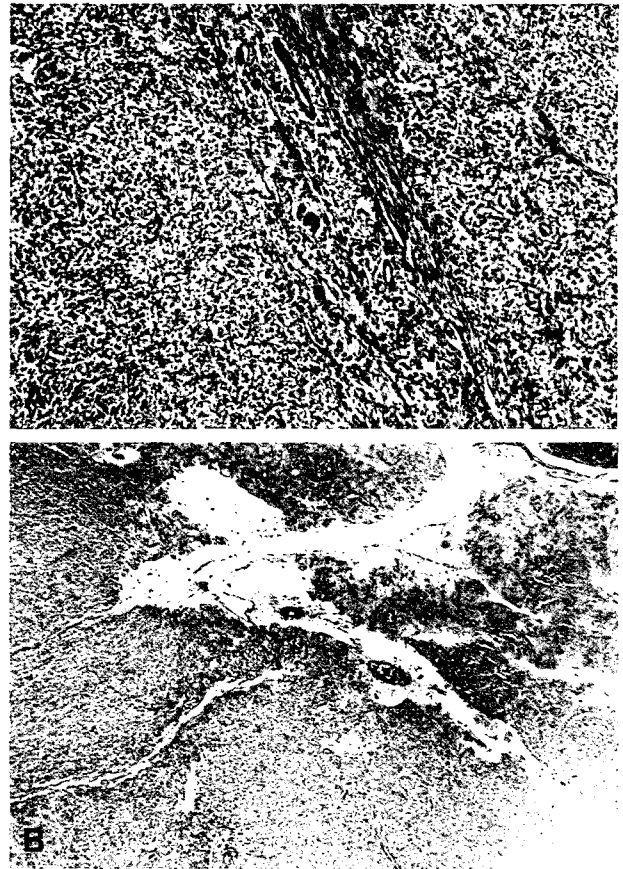


Fig. 5. Histologic finding : The tumor is composed of diffuse sheets of spindle cells with occasional round to elongated tubules (A). The tumor shows hyalinization of the stroma with small tubules and irregular cleft-like structures (B).

magnification, the spindle cells had elongated or oval nuclei and short cytoplasmic process (Fig. 6A), and the round cells had scanty or moderate amount of cytoplasm and round to oval, vesicular nucleus with distinct nuclear membrane and a prominent nucleolus (Fig. 6B). The stroma was sparse, but there were prominent spiral arterioles and hyaline strands resembling osteoid. Immunohistochemically, most of the tumor components were positive for Cam5.2, vimentin, CD10, smooth muscle actin, and calretinin. In addition, the tubular components were positive for desmin. Some of the tumor cells were positive for alpha-inhibin, CD99, and Melan A. The tumor cells were also positive for estrogen and progesterone receptors, but negative for epithelial membrane antigen. Because the sex cord elements were more than 50% of the tumor, the tumors was diagnosed

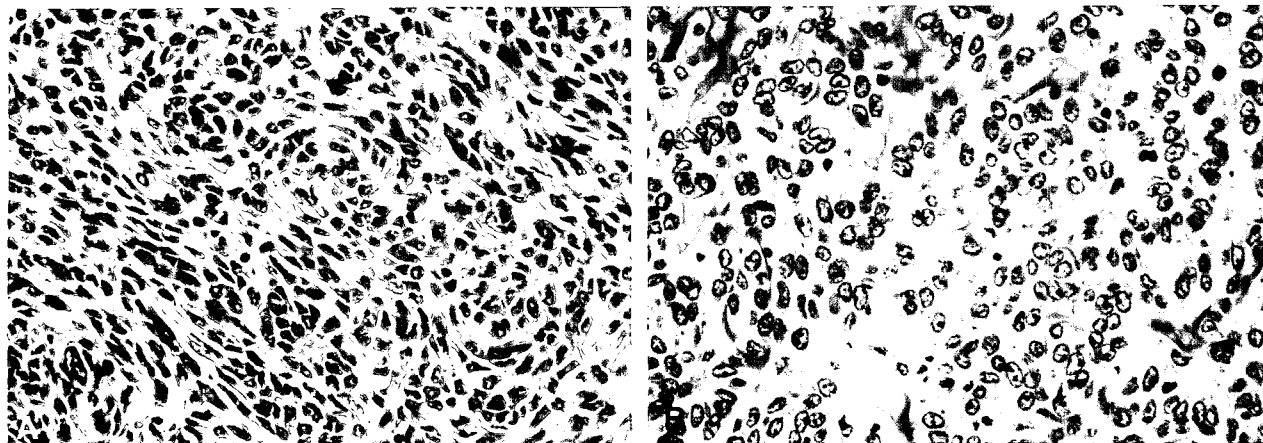


Fig. 6. Histologic finding : The spindle tumor cells have short cytoplasmic process and elongated nucleus (A). The round tumor cells have round, vesicular nucleus, distinct nuclear membrane and a prominent nucleolus (B).

as endometrial stromal sarcoma, group II (uterine tumor resembling ovarian sex cord tumor (UTROSCT)).

DISCUSSION

The cytologic diagnosis of endometrial stromal sarcoma is difficult and frequently missed because the tumor cells usually do not present in cervical smears and closely resemble the normal endometrial stromal cells in low grade sarcoma or is misdiagnosed as poorly differentiated carcinoma in high grade sarcoma. Becker and Wong¹ reported that only three of six endometrial stromal sarcomas had cervicovaginal smears that were positive or highly suggestive of malignancy. Massoni and Hajud⁴ compared the positive rates of cervical cytology in uterine sarcomas. Approximately 50% of the patients with mixed mesodermal tumors, 30% of those with endometrial stromal sarcomas, and 20% of those with leiomyosarcomas had positive cytologic findings. Hsiu and Stawicki³ described two cases of endometrial stromal sarcomas and summarized four useful cytologic features; the occurrence of predominantly isolated malignant cell, the uniform pattern of tumor cells in spite of marked nuclear variations, the comet appearance of tumor cells, and the presence of bizarre, multinucleated giant tumor cells. The common cytologic features of endometrial stromal sarcomas of the uterus are the presence of small, rounded, malignant cells with occasionally tapered comet

cells, identifiable nucleoli, and a necrotic tumor background.

UTROSCT group II shows predominant components of bland epithelioid cells with tubules and anastomosing cords. Histologically, the distinction from a variety of uterine tumors such as endometrial adenocarcinoma, adenosarcoma, carcinosarcoma, epithelioid smooth muscle tumors may be sometimes difficult. We could not find any descriptions about the cytologic findings of UTROSCT in cervicovaginal smears. Our case showed loose aggregates of spindle cells with short cytoplasmic process and elongated nuclei and epithelioid cells with round nuclei, distinct nuclear membrane and a prominent nucleolus arranged in tubules or glandular structures. On initial cytologic examination, we interpreted these cells as atypical endometrial glandular cells.

The differential diagnosis from endometrial adenocarcinoma may rely upon the absence of cellular atypism comparable with adenocarcinoma and the presence of stromal components. Malignant mixed mesodermal tumor (MMMT) may be also considered in differential diagnosis. In MMMT, both epithelial and stromal components are frankly malignant and atypical or malignant squamous cells are present in about 25% of the cases. Recently, Kabbani et al.¹³ described a case of UTROSCT presenting as a cervical mass and mimicking cervical adenocarcinoma. The histologic picture was partly identical with our present case.

In summary, UTROSCT should be included in the differential diagnosis when an epithelioid or gland-forming cells are identified, especially accompanied with stromal component in cervical smears.

REFERENCES

1. Zaharopoulos P, Wong JY, Lamke CR. Endometrial stromal sarcoma: Cytology of pulmonary metastasis including ultrastructural study. *Acta Cytol* 1982;26:49-54.
2. Hong IS. The exfoliative cytology of endometrial stromal sarcoma in peritoneal fluid. *Acta Cytol* 1981;25:277-81.
3. Hsiu JG, Stawicki ME. The cytologic findings in two cases of stromal sarcoma of the uterus. *Acta Cytol* 1979;23:487-9.
4. Massoni WA, Hajdu SI. Cytology of primary and metastatic uterine sarcomas. *Acta Cytol* 1984;28:93-100.
5. Morimoto N, Ozawa M, Kato Y, Kuramoto H. Diagnostic value of mitotic activity in endometrial stromal sarcoma. Report of two cases. *Acta Cytol* 1982;26:695-8.
6. Kim K, Naylor B, Han IH. Fine needle aspiration cytology of sarcomas metastatic to the lung. *Acta Cytol* 1986;30:688-94.
7. Nguyen GK, Berendt RC. Aspiration biopsy cytology of metastatic endometrial stromal sarcoma and extragenital mixed mesodermal tumor. *Diagn Cytopathol* 1986;2:256-60.
8. Yang GCH. Fine needle aspiration cytology of low grade endometrial stromal sarcomas. *Acta Cytol* 1995;39:701-5.
9. Yokosuka K, Abe S. Recurrent low grade endometrial stromal sarcoma in ascitic fluid. *Acta Cytol* 2002;46:785-6.
10. Becker SN, Wong JY. Detection of endometrial stromal sarcoma in cervicovaginal smears. Report of three cases. *Acta Cytol* 1981;25:272-6.
11. Clement PB, Scully RE. Uterine tumors resembling ovarian sex cord tumors. *Am J Clin Pathol* 1976;66:512-25.
12. Hauptmann S, Nadjari B, Kraus J, Turnwald W, Dietel M. Uterine tumor resembling ovarian sex-cord tumor : a case report and review of the literature. *Virchows Arch* 2001;439:97-101.
13. Kabbani W, Deavers MT, Malpica A, et al. Uterine tumor resembling ovarian sex-cord tumor: Report of a case mimicking cervical adenocarcinoma. *Int J Gynecol Pathol* 2003;22:297-302.