

Original Articles

The Effects of *Live Leech (Hirudo Medicinalis)* Therapy on Diabetic Foot: a Clinical Case Report

Hyun-Jong Na

Ausung Korean Oriental Medical Clinic

Purpose : A clinical case of diabetic foot-wound repair using *Hirudo medicinalis* therapy and its application is reported and discussed.

Methods : The subject was a sixty-six-year-old woman diagnosed with a non-healing wound indicating the amputation of her right diabetic foot. Instead, *Hirudo medicinalis* therapy was performed twelve times over forty days, twice a week. The transition of wound closure was observed with the naked eye, and the plethysmogram was measured at the beginning and end of the treatment period.

Results : The wound contracted with decreased exudate, collagen-like connective tissue sprouted, and then the wound gradually closed. The initial value (-0.08) of the dicrotic elastic index rose to -0.03.

Conclusion : *Hirudo medicinalis* therapy had a positive effect on the wound repair, without a negative effect on the circulation, allowing the foot to be saved. It is necessary to investigate its wound repair mechanism for the further development of the *Sahyul* method. (*Korean J of Oriental Med* 2003;24(4):136-138)

Key Words: *Hirudo medicinalis*, diabetic foot, wound repair, plethysmogram, *Sahyul*

Introduction

Hirudo medicinalis(*HM*) may circumvent tissue necrosis by removing engorged blood from tissues otherwise devoid of adequate venous channels (Dabb et al., 1992), and may be applied on venous congestion that induces hypoxia, acidosis, and arterial thrombi formation.

Diabetics are more vulnerable to bacterial invasion and consequent delay in wound healing. Though the internal use of leeches for circulatory improvement has

been clinically applied, rarely has *HM* therapy been used for chronic wound repair. A clinical case of diabetic foot-related wound repair and circulatory change by *HM* therapy is described.

Methods

Live leeches (Hansmedi Co., Korea) were used as treatment, and plethysmogram (PTG) analysis (Meridian Co., Korea) conducted for circulation comparison.

The patient was a sixty-six-year-old woman, recommended for the amputation of her right diabetic foot due to a non-healing wound, under the control of blood glucose, blood pressure, and renal function. The

Received 21 April 2003; revised 20 September 2003; accepted 2 October 2003

Correspondence to: Hyun-Jong Na, Ausung KOM Clinic, 36-1, Dongsung-ro, St. 3, Jung-gu, Daegu, Korea; Tel: 82-53-422-2830, E-mail: kodna@naver.com

size of the chronic wound near *Soggol* (*Shugu*: 束骨: B65) was about 3.0 cm in width and 2.5 cm in length, with exposed reddish flesh and becoming loose around the boundary on first examination.

The *HM* treatments were performed twelve times over forty days, twice a week; one leech per treatment was applied to the dried wound at 11:30 a.m. The transition of chronic wound closure formed by *HM* treatments was observed with the naked eye and PTG was measured at the beginning and end of the treatment period.

Results

1. Wound repair

Signs of wound contraction were observable initially to the naked eye on the second treatment day: tighter boundary, dry flesh surface, and decreased fluids. The contraction was directed downwards and forwards, and the wound boundaries were drawn inwards.

A subcutaneous whitish layer, supposed to be connective tissue like collagen, was formed initially on the third treatment day and enlarged from the edge to the center of the wound.

Gradually the wound narrowed more lengthwise, and then healed up around the fortieth day.

2. PTG

The major circulation indexes of PTG measurement are ejection elastic index (EEI), dicrotic dilation index (DDI), and dicrotic elastic index (DEI).

The initial EEI (0.20) was similar to the final (0.23), and the initial and final DDIs were the same (0.26), but the final DEI (-0.03) was higher than the initial (-0.08)(Fig. 1).

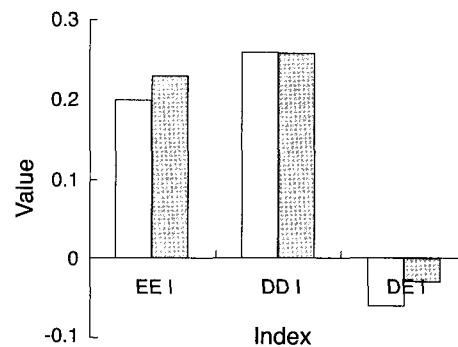


Fig. 1. Comparison of the Circulation Index Transition between the Beginning and End of the Treatment Period through PTG Analysis.

Discussion

Generally, *HM* therapy is used for any of the following conditions: poor venous drainage (venous congestion and/or venous outflow obstruction); salvage of vascularly compromised flaps (muscle, skin, and fat tissue surgically transplanted from one part of body to another); or salvage of vascularly compromised replants (limbs or other body parts re-attached after traumatic amputation). In this clinical case, the optimal sucking and bleeding of *HM* would contribute to wound repair by way of removing the metabolic substrates and accelerating tissue-remodeling, changing the states of temperature, oxygen, pH, fluid dynamics, and micro-organisms in the chronic wound. A new purpose for *Sahyul* (*xiexue*: 瀉血) can be proposed at this point.

HM may ingest 20 to 60 ml of human blood or 900% of its body weight (Lent, 1986), followed by an additional amount of bleeding via slow but continuous flow after feeding, restoring blood flow in the micro-circulation. In this clinical case, the average sucking-time of one leech was twelve minutes, the blood volume sucked by one about 10 ml, and the continuous bleeding-time after each treatment 9 hours.

The continuous bleeding is related to hirudin, a

thrombin inhibitor isolated from the saliva of the *HM*. Further investigations may well disclose even more uses for the leech, particularly for its enzymes with anesthetic, anticoagulant, and antimetastatic properties (Mory et al., 2000).

Wound contraction, the biomechanical phenomenon, is a ubiquitous and essential feature in the healing of these wounds and, together with tissue formation, normally effects full wound closure. Clinically by reducing the size of the defect, wound contraction is supposed to be beneficial to the overall repair process. So, the results of this report, including the initial wound contraction within 3 days after the first *HM* treatment, reveals wound repair is promoted by wound contraction.

When diabetes is accompanied by delayed wound healing and insufficient granulation tissue formation, possibly because of a defect in fibroblast function (Kim et al., 2001), *HM* therapy could enhance the regeneration of fibroblasts.

Conclusion

HM therapy had a positive effect on wound repair of

a sixty-six-year-old woman's diabetic foot, allowing it to be saved. Furthermore, according to a circulation analysis of PTG measurement, it did not have a negative effect on her circulation during the treatment period.

This implies that we should develop the methods of *Sahyul* (*xiexue*: 瀉血) therapy as well as those of *HM* therapy, applying the mechanism of *HM* therapy.

References

1. Dabb RW, Malone JM, and Leverett LC. The use of medicinal leeches in the salvage of flaps with venous congestion. *Ann. Plast. Surg.* 1992; 29:250-6.
2. Kim JD, Kang NH, Kwon H, Lim P, and Oh GT. The effects of glucose control on DNA and collagen synthesis of cultured fibroblasts of chronic diabetic wounds. *J. Korean Soc. Plast. Reconstr. Surg.* 2001; 28(1):26-31.
3. Lent C. New medical and scientific uses of the leech. *Nature.* 1986; 323:494.
4. Mory RN, Mindell D, and Bloom DA. The leech and physician: biology, etymology, and medical practice with *Hirudinea medicinalis*. *World J. Surg.* 2000; 24:878-83.