

## 완전 대정맥-폐동맥 연결수술로 전환 후의 폰탄순환장애 개선

박한기\* · 이기종\* · 송석원\* · 이 식\* · 박영환\* · 조범구\*

### Improvement of Fontan Circulatory Failure after Conversion to Total Cavopulmonary Connection

Han Ki Park, M.D.\*, Gijong Yi, M.D.\*, Suk Won Song, M.D.\*, Sak Lee, M.D.\*  
Young Hwan Park, M.D.\*, Bum Koo Cho, M.D.\*

**Background:** By improving the flow pattern in Fontan circuit, total cavopulmonary connection (TCPC) could result in a better outcome than atriopulmonary connection Fontan operation. For the patients with impaired hemodynamics after atriopulmonary Fontan connection, conversion to TCPC can be expected to bring hemodynamic and functional improvement. We studied the results of the revision of the previous Fontan connection to TCPC in patients with failed Fontan circulation. **Material and Method:** From October 1979 to June 2002, eight patients who had failed Fontan circulation, underwent revision of previous Fontan operation to TCPC at Yonsei University Hospital. Intracardiac anomalies of the patients were tricuspid atresia (n=4) and other functional single ventricles (n=4). Mean age at TCPC conversion was  $14.0 \pm 7.0$  years (range, 4.6~26.2 years) and median interval between initial Fontan operation and TCPC was 7.5 years (range, 2.4~14.3 years). All patients had various degree of symptoms and signs of right heart failure. NYHA functional class was III or IV in six patients. Paroxysmal atrial fibrillation (n=1), cyanosis (n=2), intraatrial thrombi (n=2), and protein losing enteropathy (PLE) (n=3) were also combined. The previous Fontan operation was revised to extracardiac conduit placement (n=7) and intraatrial lateral tunnel (n=1). **Result:** There was no operative death. Major morbidities included deep sternal infection (n=1), prolonged pleural effusion over two weeks (n=1), and temporary junctional tachyarrhythmia (n=1). Postoperative central venous pressure was lower than the preoperative value ( $17.9 \pm 3.5$  vs.  $14.9 \pm 1.0$ ,  $p=0.049$ ). Follow-up was complete in all patients and extended to 50.1 months (mean,  $30.3 \pm 12.8$  months). There was no late death. All patients were in NYHA class I or II. Paroxysmal supraventricular tachycardia developed in a patient who underwent conversion to intraatrial lateral tunnel procedure. PLE was recurred in two patients among three patients who had had PLE before the conversion. There was no newly developed PLE. **Conclusion:** Hemodynamic and functional improvement could be expected for the patients with Fontan circulatory failure after atriopulmonary connection by revision of their previous circulation to TCPC. The conversion could be performed with low risk of morbidity and mortality.

(Korean J Thorac Cardiovasc Surg 2003;36:559-565)

**Key words:** 1. Cavopulmonary connection  
2. Fontan operation  
3. Anastomosis, surgical  
4. Shunt

\*연세대학교 의과대학 흉부외과학교실

Department of Thoracic and Cardiovascular Surgery, Yonsei University College of Medicine, Seoul, Korea

†본 논문은 대한흉부외과학회 제 34차 추계학술대회에서 구연되었음.

책임저자 : 박영환 (120-752) 서울특별시 서대문구 신촌동 134, 연세대학교 의과대학 흉부외과학교실

(Tel) 02-361-7285, (Fax) 02-313-2992, E-mail: yhpark@yumc.yonsei.ac.kr

논문접수일 : 2003년 5월 7일, 심사통과일 : 2003년 6월 28일

본 논문의 저작권 및 전자매체의 지적소유권은 대한흉부외과학회에 있다.

## INTRODUCTION

Fontan and Baudet [1] presented a new surgical treatment for functional single ventricle by reporting successful treatment for correction of tricuspid atresia. Although the survival has been improving over time, patients undergoing Fontan operation are still subject to postoperative morbidity: right atrial dilatation, thromboembolism, atrial arrhythmias, right pulmonary vein obstruction, decreased ventricular function, increasing cyanosis, and protein-losing enteropathy [2-4]. Most of these complications occur as a result of dilatation of right atrium in patients who have undergone atriopulmonary Fontan connections.

On the basis of flow dynamics, Dr. de Leval [5] modified the Fontan operation to minimize energy loss of systemic venous drain to the pulmonary artery. His modification, total cavopulmonary connection (TCPC), excludes the right atrium from the Fontan circuit and routs the caval blood into pulmonary artery and demonstrated better long-term outcome [6]. When patients with atriopulmonary Fontan connections show circulatory failure, conversion to total cavopulmonary connection might alleviate some of the common complications by reducing the turbulence of central venous flow.

We studied the surgical results of the TCPC conversion, to evaluate the outcome and the risk of the revision of the previous Fontan connection to TCPC.

## MATERIAL AND METHOD

### 1) Patients

From October 1979 through June 2002, eight patients needed conversion of previous Fontan connection to intraatrial or extracardiac TCPC due to Fontan circulatory failure at Yonsei Cardiovascular Center. We retrospectively reviewed the medical records of the patients. The preoperative clinical characteristics of our patient population are noted in Table 1. Six patients were male and two two were female. Intracardiac anomalies were tricuspid atresia in four cases, and other functional single ventricle in the other four cases. One patient had heterotaxia syndrome. The atriopulmonary Fontan operations were performed at the age of  $5.3 \pm 4.2$  years (range, 1.6~11.9 years). Originally, patients had undergone either direct

right atrial appendage to pulmonary artery anastomosis (n=6), or anastomosis of the right atrial appendage to the infundibulum of the right ventricle (n=2).

Hemodynamic derangements were present in all patients. All patients showed various degree of symptom and signs of systemic venous congestion such as easy fatigability, peripheral pitting edema, pleural effusion, ascites and hepatic congestion. The New York Heart Association classification was class II in two patients, Class III in five patients, and class IV in one patient. Paroxysmal atrial fibrillation was noted in a patient and in the other patients sinus rhythm was maintained.

Echocardiogram and cardiac catheterization were performed preoperatively in all patients. The right atriums were markedly dilated and the systemic venous blood drain revealed swirling in dilated right atrium and delayed passage into pulmonary artery. In two patients, thrombi were found in the right atrium. Obstruction of the Fontan pathway at the anastomosis site was present in a patient. Preoperative central venous pressure measured at right atrium was  $17.9 \pm 3.5$  mmHg (range, 12~22 mmHg), and was over 18 mmHg in five patients. Ventricular function was considered poor with ventricular end diastolic pressure of  $10.2 \pm 4.9$  mmHg. Mild to moderate atrioventricular valve regurgitation was present in three patients.

Cyanosis ( $\text{SaO}_2 < 90\%$ ) was noted at the time of presentation in two patients, one of them had partial detachment of the patch of the atrioventricular valve closure. Protein losing enteropathy (PLE) was combined in three patients (patient 1, 6, and 8). The diagnosis of PLE was confirmed with the  $\alpha$ -1-antitrypsin clearance in stool.

The age at TCPC conversion was  $14.0 \pm 7.0$  years (range, 4.6~26.2 years). The conversion was performed at an average of  $8.7 \pm 5.1$  (range, 2.1~14.5 years) years after the original Fontan operation

### 2) Revision of atriopulmonary connection

The operation was performed under extracorporeal cardiopulmonary bypass and cardioplegic cardiac arrest. Standard cardiopulmonary bypass was initiated with aortic and bicaval cannulation initially at normothermia, after which the patients body was cooled to moderate hypothermia during the operation.

The previous atriopulmonary and atrioventricular connec-

**Table 1.** Patient characteristics and preoperative status

Patient No.	Diagnosis	Type of previous Fontan operation	Age at conversion (year)	Interval (year)	Indication	CVP (mmHg)	Rhythm	NYHA class
1	TA	RA-PArt	26.2	14.5	Effusion, ascites, RA thrombi, PLE	12	Sinus bradycardia	III
2	TA	RA-RV	16.5	13.8	Edema, Huge RA	19	NSR	III
3	TA	RA-RV	15.4	13.7	Edema, Effusion, AVVR (I/IV), RA thrombi	22	Afib	IV
4	TA, DOLV	RA-PArt	15.5	10.0	Dilated RA, Engorged hepatic vein, AVVR (I/IV)	16	NSR	II
5	PA, AVSD, TAPVR	RA-PArt	10.7	7.6	Anastomosis stenosis, cyanosis	20	NSR	III
6	DORV	RA-PArt	5.5	2.3	Effusion, PLE	20	NSR	III
7	Corrected TGA, VSD, hypoplastic LV	RA-PArt	17.4	5.5	AVVR (II/IV), cyanosis, TV Patch detachment	20	NSR	III
8	DORV, hypoplastic LV	RA-PArt	4.6	2.1	PLE	14	NSR	II

AFib=Atrial fibrillation; AVSD=Atrioventricular septal defect; AVVR=Atrioventricular valve regurgitation; DOLV=Double outlet left ventricle; DORV=Double outlet right ventricle; LV=Left ventricle; PA=Pulmonary atresia; PArt=Pulmonary artery; PLE=Protein losing enteropathy; RA=Right atrium; RV=Right ventricle; TA=Tricuspid atresia; TGA=Transposition of great arteries; TV=Tricuspid valve.

tions were taken down and the revision to extracardiac conduit (n=7) and intraatrial lateral tunnel (n=1) Fontan operation was performed. The extracardiac conduit Fontan was performed by placing conduit between inferior vena cava and pulmonary artery. In five cases polytetrafluoroethylene tube grafts were used for extracardiac conduit and in two patients the conduits were made of autologous pericardial flap. Intraatrial lateral tunnel was constructed with atrial wall flap.

Fenestration between the conduit and the left atrium was made in four cases including three patients who had had PLE. Thrombi in the right atrium, which had been noticed preoperatively with the echocardiogram, were removed during the operation.

Mean cardiopulmonary bypass time was  $144 \pm 38$  minutes (range, 82~202 minutes) and the aorta cross clamp time was  $81 \pm 30$  minutes (range, 36~130 minutes).

### 3) Statistical analysis

Means are expressed as average standard deviation; comparison of groups was analyzed by the Wilcoxon signed ranks test.

## RESULT

### 1) Operative and early postoperative outcome

There was no operative mortality.

Just one patient had pleural effusion that required thoracic drainage for more than two weeks postoperatively; in patient 1, who had PLE and large amount of pleural effusion preoperatively, the PLE and pleural effusion persisted and the chest tube could be removed on the 41<sup>st</sup> postoperative day.

Patient 2, who underwent TCPC conversion with extracardiac pericardial flap, required re-exploration due to mediastinal bleeding. In this patient, deep mediastinal infection was

**Table 2.** Conversion to TCPC and follow-up status

Patient No.	Type of TCPC	Conduit material	Fenestration	Postoperative CVP (mmHg)	Follow up duration (mo)	Follow up NYHA	Problem during class	EF (%) follow up	AVVR
1	EC	PTFE tube graft	+	13	33.1	II	PLE recur	65	No
2	EC	Pericardial flap	-	16	31.4	II	-	72	No
3	EC	PTFE tube graft	-	15	31.7	I	-	57	No
4	EC	PTFE tube graft	-	15	32.0	I	-	59	I/IV
5	EC	Pericardial flap	+	16	31.6	I	-	78	No
6	IA	Atrial wall	+	14	50.1	I	PSVT	77	No
7	EC	PTFE tube graft	-	15	3.1	II	-	57	No
8	EC	PTFE tube graft	+	15	29.7	II	PLE recur	48	No

AVVR=Atrioventricular valve regurgitation; EF=Ejection fraction; CVP=Central venous pressure; EC=Extracardiac; IA=Intra-atrial; PLE=Protein losing enteropathy; PSVT=Paroxysmal supra-ventricular tachycardia; PTFE=Polytetrafluoroethylene.

developed postoperatively, which was successfully treated by debridement and mediastinal irrigation without long-term sequelae.

Postoperative arrhythmia occurred in one patient. Patient 6, who had no preoperative rhythm disturbance, experienced transient junctional rhythm. Normal sinus rhythm was maintained in the other patients until discharge from the hospital.

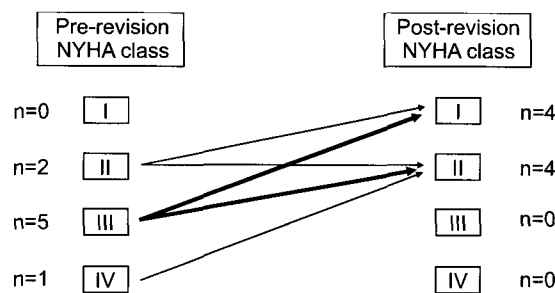
The median length of hospital stay was 13.1 days (range, 6~45 days) postoperatively. Two patients stayed more than 30 days in the hospital; patient 2 who suffered from postoperative deep sternal infection was discharged at 43 days and patient 1 whose PLE persisted after TCPC was discharged from the hospital at 45 days after operation.

The central venous pressure measured postoperatively at the intensive care unit ranged 13~17 mmHg and was lower than the preoperative value ( $17.9 \pm 3.5$  versus  $14.9 \pm 1.0$ ,  $p=0.049$ ) (Table 1, 2).

**2) Follow up**

Follow-up was complete in entire patients and extended to 50.1 months (average,  $30.3 \pm 12.8$  months). There was no late death. The functional class of the patients was improved and all the patients were in NYHA class I or II (Table 2, Fig 1).

Atrial arrhythmia was developed in one patient. Paroxysmal supra-ventricular tachycardia developed in patient 6 who had maintained normal sinus rhythm preoperatively and underwent TCPC conversion with intraatrial lateral tunnel Fontan



**Fig. 1.** Preoperative and postoperative functional class.

operation. In that patient the supra-ventricular arrhythmia was controlled with medication. All patients, including patient 3 who had had preoperative paroxysmal atrial fibrillation, maintained normal sinus rhythm during follow up.

After TCPC conversion, the PLE was resolved at discharge in all three patients who had suffered from PLE. However PLE was recurred in two patients during the follow up and the patients were on conservative management. There was no newly developed PLE during follow up.

Patients were on anticoagulation with warfarin for six months postoperatively and no intracardiac thrombi were found with the echocardiographic examination during the follow up period. The systemic ventricular function was well preserved with the follow up systemic ventricular ejection fraction ranging 48~78% (mean,  $64.1 \pm 10.8\%$ ). Mild atrioventricular valve regurgitation remained in one patient and no

moderate or severe atrioventricular valve regurgitation was shown during the follow up. Follow up angiogram taken in five patients showed good hemodynamics without systemic venous stasis.

## DISCUSSION

Although Fontan operation ameliorated the life expectancy of the patients born with functional single ventricle, common problems such as intraatrial thrombi, atrial arrhythmias, hemodynamic derangement, and impaired exercise tolerance occur years after the operation [2-4]. The right atrium in the atriopulmonary connection was thought to play a detrimental role in the development of late complications. Turbulent blood flow in the systemic venous atrium with parietal stasis increases the risk of thrombus formation and elevated atrial pressure facilitates distension of the atrial wall, progressive atrial enlargement, and conduction abnormality. In order to improve the flow pattern in the Fontan circulation, de Leval and associates [5] developed a technique to guide the systemic venous return from the inferior vena cava to the orifice of the superior vena cava through a tubular construct. His modification was to achieve laminar blood flow in the Fontan circuit. With his modification, hemodynamic profile of the patients was relatively well preserved and the incidence of late morbidities related to the unnatural physiology of Fontan procedure was diminished [6].

For the patients with impaired hemodynamics after atriopulmonary Fontan connection, hemodynamic and functional improvements are expected with the revision of their Fontan connection to either extracardiac or intraatrial conduit cavopulmonary anastomosis. Actually, Fontan conversion has resulted in significant hemodynamic improvement in patients with failing Fontan circulations [7,8]. However, patients with Fontan circulatory failure are high risk group, because complications of Fontan failure such as pleural effusion, arrhythmia, hepatic and splenic congestion, impaired gastrointestinal and immune system increase the operative risk.

Our retrospective clinical analysis demonstrated the beneficial effect of the conversion to TCPC. One of the most beneficial effects is the lowering of the central venous pressure. This effect would simply improve the complications

such as edema, pleural effusion and ascites. Also, it would affect the ventricular function. We could not directly compare the preoperative and postoperative ventricular function because preoperative ventricular ejection fraction and postoperative ventricular end diastolic pressure were available only in limited cases. But the ventricular ejection fraction measured echocardiographically during follow up demonstrated well-preserved ventricular function. And when we compared the degree of atrioventricular valve regurgitation, we think it could be said that the ventricular function of our cohort improved or at least preserved after operation. It is reported that elevated coronary sinus pressure decreases transcortical perfusion gradient and results in impaired myocardial function in atriopulmonary connection [9]. McElhinney et al [7] showed that lowering of coronary sinus pressure improves myocardial function and increases cardiac output. Decompression of the pulmonary venous drainage might be another factor for hemodynamic improvement after TCPC conversion. When the pulmonary venous return is compressed by enlarged right atrium, the pulmonary venous obstruction rises the pulmonary artery pressure, disturbs the systemic venous drainage and aggravates failed Fontan circulatory failure. In all patients in our cohort, the symptoms such as easy fatigability, edema, pleural effusion, and ascites were improved and the NYHA functional class was improved. It is reasonable to regard this clinical and functional improvement resulted from the hemodynamic improvement.

One of the chronic complications of atriopulmonary type Fontan operation is atrial arrhythmia. Arrhythmias have been noted in up to 40% of Fontan patients at 10-year follow up [4,10]. Dilated atrium, high right atrial pressure, and suture burden in the atrium are regarded as causative factors for the development of arrhythmia. In our cohort only one patient had paroxysmal atrial fibrillation and no arrhythmia surgery was performed with the revision of Fontan operation. After TCPC conversion, seven patients maintained normal sinus rhythm, but atrial arrhythmia was developed in a patient who underwent intraatrial lateral tunnel using atrial wall flap. In that patient, the right atrium is still exposed to the systemic venous chamber and has a suture line, which might affect adversely. Recently, for the patients whose Fontan repair has failed, conversion to TCPC with concomitant arrhythmia

surgery showed excellent result with improved functional class and low incidence of recurrent arrhythmia [11,12]. If a patient with failed Fontan circulation has atrial arrhythmia, it is recommended to perform arrhythmia surgery during the revision of Fontan operation.

PLE, one of debilitating complications of Fontan operation, was believed to be related to chronic elevation of venous pressure and subsequent impaired lymphatic drainage. But it is not seen only in those patients who have the elevated RA pressure. It is not uncommon to find patients with elevated systemic venous pressure but without clinical evidence of PLE [13]. These finding shows that the hemodynamic impairment and high systemic venous pressure is not directly related to the development of PLE. Operational complexity, proinflammatory cytokine release, reperfusion injury, myocyte damage, and vasomotor nephropathy might cause intestinal vascular and lymphatic injury and these might be potentiating factors in the pathogenesis of PLE [13,14]. PLE was diagnosed in three patients before the revision of Fontan operation in our patient group. It was improved in all of the patients at the time of discharge. Because of the small number of cases, and because multiple therapeutic interventions were performed simultaneously, we could not find what affect the temporarily clinical improvement postoperatively. However PLE recurred in two patients. In a patient whose PLE did not recur, the central venous pressure descended dramatically from 20 to 14 mmHg. However, the central venous pressure in the remaining two patients whose PLE recurred, did not differ before and after the operation (preoperatively 12 and 14, postoperatively 13 and 15 respectively). As we can see in this result, when a hemodynamic abnormality is detected in patients with PLE, hemodynamic improvement could result in the improvement of PLE. If hemodynamic lesion that can be treated by therapeutic intervention is detected it should be corrected. Medical treatment with high dose steroid or heparin may be tried.

### CONCLUSION

In conclusion, conversion of previous atriopulmonary-type Fontan connections to extracardiac or intraatrial conduit cavopulmonary anastomosis can be performed with low risk of

morbidity or mortality. Dramatic hemodynamic and functional class improvement can be expected in patients with failed Fontan circulation. If PLE is accompanied by failed Fontan circulation, the improvement of PLE could be expected with the hemodynamic improvement after TCPC conversion.

### REFERENCES

1. Fontan F, Baudet E. *Surgical repair of tricuspid atresia*. Thorax 1971;26:240-8.
2. Cromme-Dijkhuis AH, Hess J, Hählen K, et al. *Specific sequelae after Fontan operation after Fontan operation at mid-and long-term follow-up*. J Thorac Cardiovasc Surg 1993;106:1126-32.
3. Gentles TL, Mayer JE, Gauvreau K, et al. *Fontan operation in five hundred consecutive patients: Factors influencing early and late outcome*. J Thorac Cardiovasc Surg 1997;114:376-91.
4. Driscoll DJ, Offord KP, Feldt RH, Schaff HV, Puga FJ, Danielson GK. *Five-to fifteen-year follow-up after Fontan operation*. Circulation 1992;85:469-96.
5. de Leval MR, Kilner P, Gewillig M, Bull C. *Total cavopulmonary connection: a logical alternative to atriopulmonary connection for complex Fontan operations-experimental studies and early clinical experience*. J Thorac Cardiovasc Surg 1988;96:682-95.
6. Stamm C, Friehs I, Mayer JE, et al. *Long-term results of the lateral tunnel Fontan operation*. J Thorac Cardiovasc Surg 2001;121:28-41.
7. McElhinney DB, Reddy MV, Moore P, Hanley FL. *Revision of previous Fontan connections to extracardiac or intraatrial conduit cavopulmonary anastomosis*. Ann Thorac Surg 1996;1276-83.
8. Marcelletti CF, Hanley FL, Mavroudis C, et al. *Revision of previous Fontan connections to total extracardiac cavopulmonary anastomosis: A multicenter experience*. J Thorac Cardiovasc Surg 2000;119:340-6.
9. Mirura T, Hiramatsu T, Forbes JM, et al. *Effects of elevated coronary sinus pressure on coronary blood flow and left ventricular function: Implications after the Fontan operation*. Circulation 1995;92(suppl 2):298-303.
10. Peters NS, Somerville J. *Arrhythmias after the Fontan procedure*. Br Heart J 1992;85:199-204.
11. Mavroudis C, Backer CL, Deal BJ, Johnsrude C, Strasburger J. *Total cavopulmonary conversion and maze procedure for patients with failure of the Fontan operation*. J Thorac Cardiovasc Surg 2001;122:863-71.
12. Setty SP, Finucane K, Skinner JR, Kerr AR. *Extracardiac conduit with a limited maze procedure for the failing Fontan with atrial tachycardias*. Ann Thorac Surg 2002;74:1992-7.

13. Feldt RH, Driscoll DJ, Offord KP, et al. *Protein-losing enteropathy after the Fontan operation.* J Thorac Cardiovasc Surg 1996;112:672-80.
14. Powell AJ, Gauvreau K, Jenkins KJ, Blume ED, Mayer JE,

Lock JE. *Perioperative risk factors for development of protein-losing enteropathy following a Fontan procedure.* Am J Cardiol 2001;88:1206-9.

=국문 초록=

**배경:** 완전 대정맥-폐동맥 연결(total cavopulmonary connection, TCPC)은 폰탄 순환의 혈류를 개선시킴으로써 심방폐동맥 형태의 폰탄 연결보다 우수한 결과를 가져올 수 있다. 심방폐동맥연결 후 혈액역학 장애를 보이는 환자들에서 TCPC로의 전환 수술은 혈액역학적, 기능적 호전을 가져올 것으로 생각된다. 폰탄 순환장애가 있는 환자에서 이전의 폰탄 수술을 TCPC로의 전환술의 결과를 연구하였다. **대상 및 방법:** 1979년 10월부터 2002년 6월까지 연세대학교 의과대학 부속병원에서 8명이 폰탄순환 장애로 과거의 폰탄 수술을 완전대정맥-폐동맥 연결로 전환하였다. 환자들의 심장 기형은 삼첨판 폐쇄증(n=4)과, 기타 기능성 단심실(n=4)이었다. TCPC로 전환 수술 시 평균 나이는  $14.0 \pm 7.0$ 년이었으며 (4.6~26.2세), 폰탄 술식 후 대동맥-폐동맥 연결로 전환한 사이의 간격의 중앙값은 7.5년(2.4~14.3년)이었다. 모든 환자들이 다양한 정도의 우심부전의 증상과 징후를 나타내었다. 6명의 환자가 NYHA 기능적 분류의 III 또는 IV에 해당되었다. 발작성 심방세동 (n=1), 청색증(n=2), 심방내 혈전(n=2)과 단백소모성 장질환(n=3)이 동반되어 나타났다. 이전의 폰탄수술은 심장의도관(n=7)과 심방내외측통로(n=1)로 전환되었다. **결과:** 수술 사망은 없었다. 주요 합병증으로는 심부흥 골감염(n=1), 2주 이상의 지속적인 흉막삼출(n=1), 일시적 접합부빈맥(n=1)이 있었다. 수술 후 중심정맥압은 수술 전에 비해 감소하였다( $17.9 \pm 3.5$  vs  $14.9 \pm 1.0$ ,  $p=0.049$ ). 모든 환자를 추적 관찰하였으며, 최장 추적관찰 기간은 50.1개월(평균  $30.3 \pm 12.8$ 개월)이었다. 만기 사망은 없었다. 모든 환자들이 NYHA 기능분류 I 또는 II에 해당되었다. 발작성 상심실성빈맥이 심방내외측통로수술로 전환 받은 환자에서 발생하였다. 수술 전 단백소실성 장질환을 가지고 있던 환자 3명 중 2명에서 단백소실성 장질환이 재발하였다. **결론:** 폰탄 술식 후 폰탄순환의 장애에 의한 혈액장애는 과거의 폰탄 술식을 완전 대정맥-폐동맥 연결로 전환해서 혈액역학적 기능과 증상의 호전을 기대할 수 있었으며 수술 사망과 합병증의 위험은 높지 않다.

- 중심 단어 :** 1. 완전 대정맥-폐동맥 연결  
2. 폰탄 수술  
3. 외과적 문합술  
4. 단락술