

- 1 -

, *

. *



가

,

.

.

:

,



1

,

,

가

.

,

가

Nucci ⁸⁾ 1810

Duchenne 1990 60 71 , 2

. Uetni ⁹⁾

Nucci⁸⁾ 1990 1998

16 가

¹⁾ 1972

3 ^{1,5,6)}

1 가

가

^{3,8,9)} Coleman

³⁾ 2001

가 40 . 3 2 cm

가

:

6-2

Tel: 02) 2225-1352, Fax: 02) 487-0754, E-mail: zenyjr@yahoo.co.kr

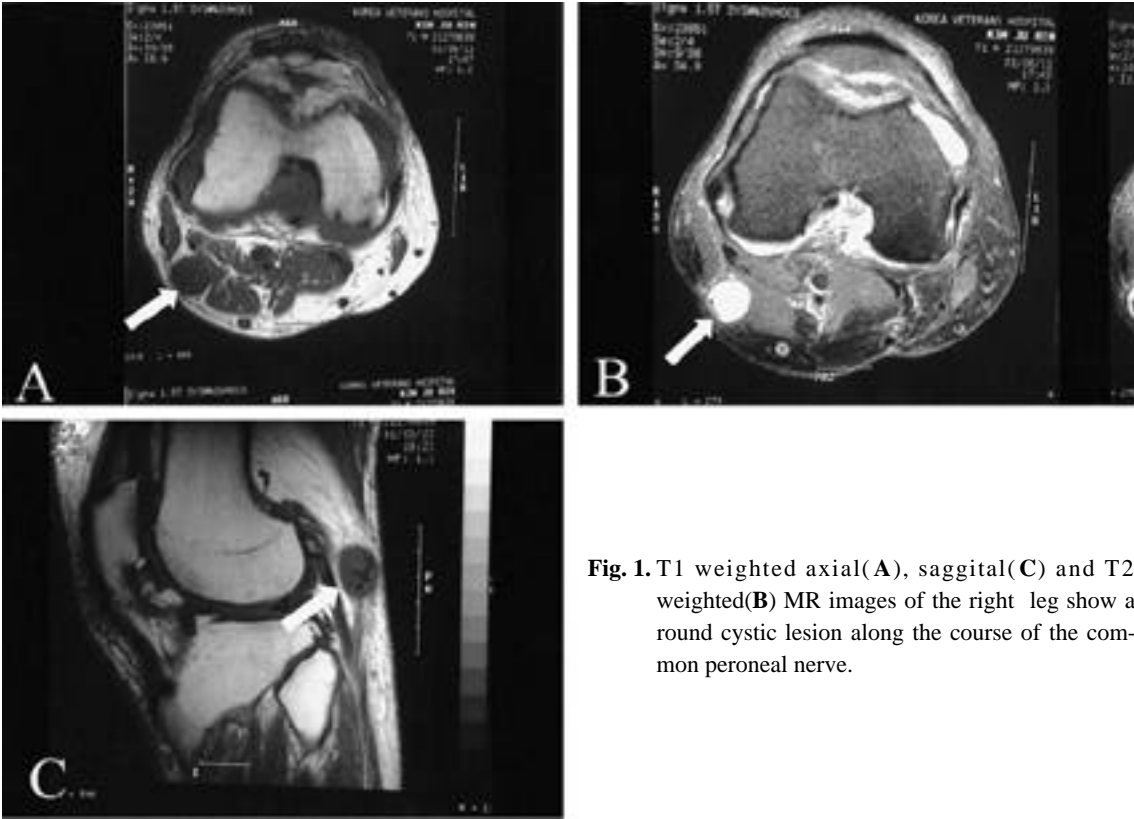


Fig. 1. T1 weighted axial(A), sagittal(C) and T2 weighted(B) MR images of the right leg show a round cystic lesion along the course of the common peroneal nerve.

(loupe)

(Fig. 2).

4.2x1.5x0.4 cm

(MRI)

2 cm

(H-E stain, x100),

(Fig. 3). S-100 stain

1

T1
(Fig. 1A, 1C), T2

(Fig. 1B),

(Fig. 1C).

3 cm
2 cm

3,8)

9 ~ 74

3,8)

4 가

11 , 23 , 28

1,5,6)

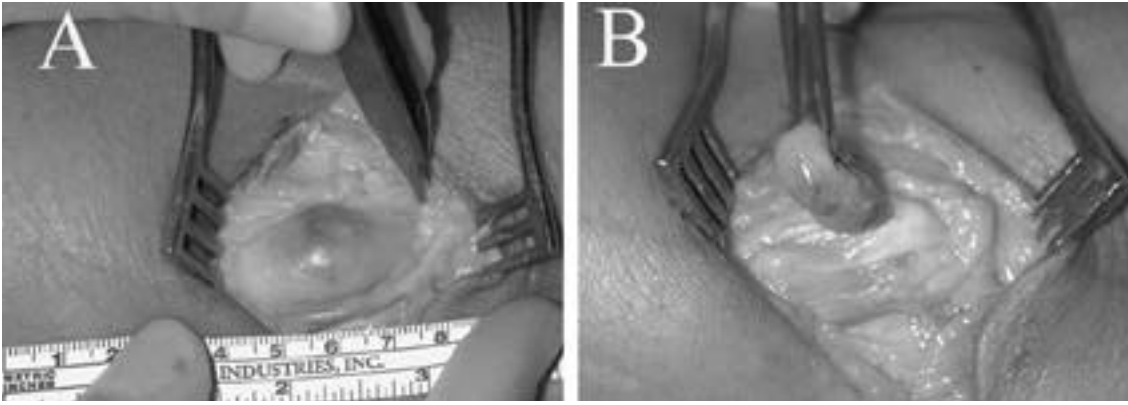


Fig. 2. At surgery, a cystic lesion, 3 cm in length was seen in the common peroneal nerve(A, arrow). After aspiration, the lesion was shrunken(B, 2 cm in length) and contained yellowish watery fluid. The mass was located in the common peroneal nerve and had no connection with the nerve(B).



Fig. 3. Histology of the resected tumor. The tumor consists of a thickened collagenous wall and its content of mucoid substance(H-E stain, $\times 100$).

Uetani⁹⁾
 가 2~15
 40
 cm
 ,
 ,
 1-10). Yamazaki
 (stretch
 10)
 ing), (elevation), (compression)
 가 3 cm
 , 1 cm
 4)
 71 .
 ,
 , Fansa⁴⁾
 가 ,
 (cystic ,
 degeneration) ,
 Aulisa²⁾
 3,8,9) ,
 가 ,
 2,8,9). Nucci⁸⁾ ,
 Robert 가 ,
 40% . Lowensteine⁷⁾
 .(Fig 가 ,
 2,B) , Stack
 , , 4

가 가 .
 ,
 (aspiration),
 , 30%
 ,
 3). 가
 3,8)
 ,
 가 1,5,8)
 ,
 ,
 .(Fig. 2)
 ,
 가

REFERENCES

- 1) **Ahn JH, You MH and Suk SI**: Intraneural Ganglion of the Peroneal Nerve. *J of Korean Orthop Surgery*. 7, 344-346, 1972.
- 2) **Aulisa L, Tamburrelli F, Padua R, Lupporelli S, Tonali P, Padua L**: Intraneural cyst of the peroneal nerve. *Childs Nerv Syst*. 14(4-5): 222-225, Apr-May, 1998.
- 3) **Coleman SH, Beredjekljan PK, Weiland AJ**: Intraneural ganglion cyst of the peroneal nerve accompanied by complete foot drop. A case report. *Am J Sports Med* 29(2): 238-241, Mar-Apr, 2001
- 4) **Fansa H, Plogmeier K, Gonschorek A and Feistner H**: Common peroneal nerve palsy caused by a ganglion. *Scand J Plast Reconstr Hand Surg* 32(4): 425-427, Dec, 1998.
- 5) **Jeong SK, Lee WC, Na CG and Park YK**: Intraneural Ganglion of the Common Peroneal Nerve. *J of Korean Orthop Surgery*. 22: 318-320, 1987.
- 6) **Lim HS, Lee SH, Lee SH and Chae DJ**: Intraneural Ganglion of the Peroneal Nerve. *J of Korean Orthop Surgery*. 25: 1790-1792.
- 7) **Lowenstein J, Towers J and Tomaino MM**: Intraneural Ganglion of the Peroneal Nerve: Importance of Timely Diagnosis. *Am J Orthop* 30(11), 816-819, 2001.
- 8) **Nucci F, Artico M, Santoro A, et al.**: Intraneural synovial cyst of the peroneal nerve: report of two cases and review of the literature. *Neurosurgery*, 26: 339-344, 1990.
- 9) **Uetani M, Hashmi R, Hayashi K, Nagatani Y, Narabayashi Y, Imamura K**: Peripheral nerve intraneural ganglion cyst: MR findings in three cases. *J Comput Assist Tomogr*. 22(4):829-832, Jul-Aug, 1998.
- 10) **Yamazaki H, Saitoh S, Seki H, Murakami N, Misawa T and Takaoka K**: Peroneal nerve palsy caused by intraneural ganglion. *Skeletal Radiol*. 28(1): 52-56, Jan, 1999.

**Intraneural Ganglion Cyst of the Peroneal Nerve
-A Case Report-**

**Jung-Ro Yoon, M.D., Jae-Ik Shim, M.D., Taek-Seon Kim, M.D., Sung-Jong Lee, M.D.,
Young-Bae Kim, M.D., Hak-Joon Kim, M.D., Tae-Jin Lee, MD*., and Dae-Chul Ko, M.D.**

*Department of Orthopaedic Surgery, Korea Veterans Hospital, Seoul, Korea
Department of Pathology, Jung-Ang University**

Ganglion cysts occurring within sheaths of peripheral nerves have been documented, but are relatively rare entities. The peroneal nerve at the level of the knee and proximal tibiofibular joint is most commonly involved. We report a case of the intraneural ganglion cyst in the peroneal nerve without neurologic deficit, which was excised successfully.

Key Words : Peroneal nerve, Intraneural ganglion.

Address reprint requests to

Jung-Ro Yoon, M.D
Department of Orthopedic Surgery, Korea Veterans Hospital
6-2, Dunchon-dong, Gangdong-gu, Seoul 134-791, Korea
TEL : 82.2-2225-1352, FAX : 82.2-487-0754, E-mail : zenyjr@yahoo.co.kr