

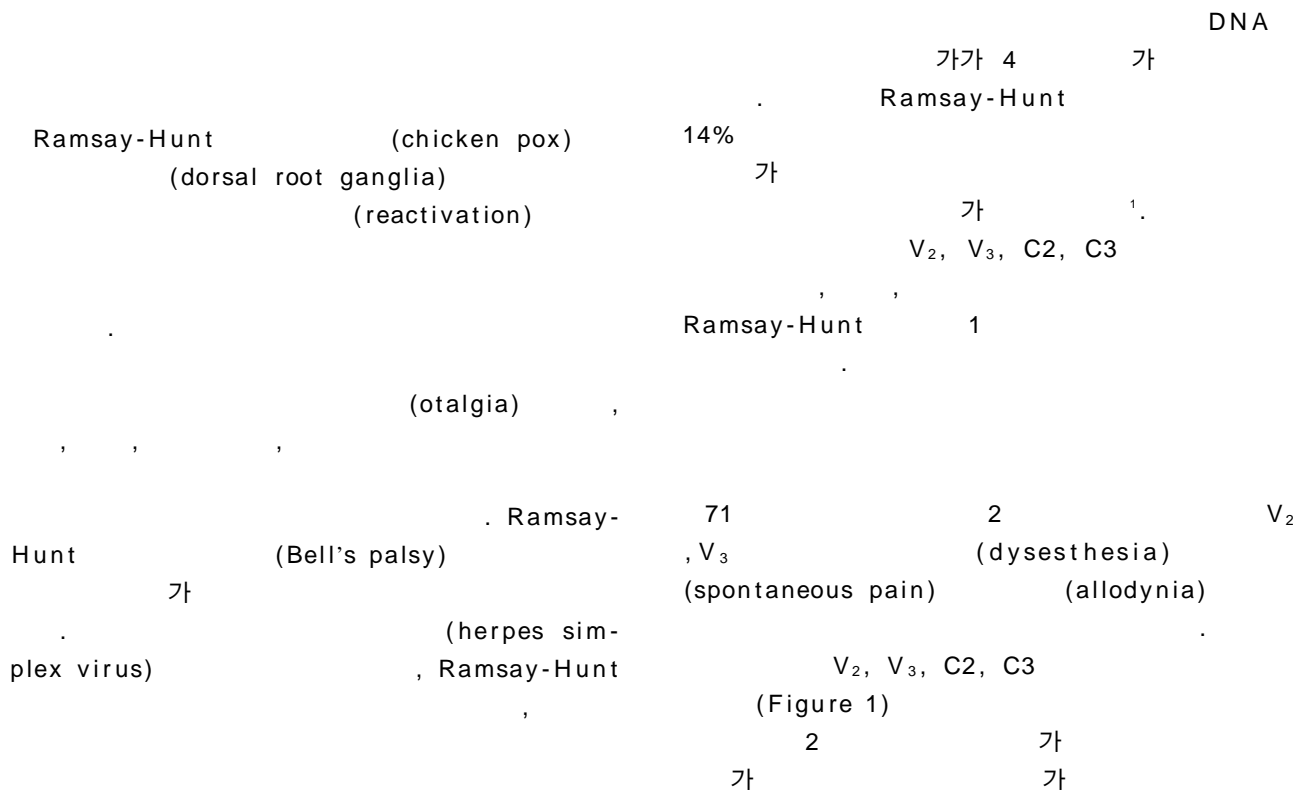
Ramsay-Hunt Syndrome involving the 2nd, 3rd cervical ganglia

Chung Seok Lee, M.D., Yong Seok Choi, M.D., Eun Hyang Song, M.D.,
Jeung Mee Kim, M.D., Jeong Ho Han, M.D., Doo Eung Kim, M.D.

Department of Neurology, Seoul Veterans Hospital

Ramsay-Hunt syndrome is a viral disease associated with peripheral facial nerve paralysis accompany by erythematous vesicular rashes on the ear(zoster oticus) or in the mouth. Based on clinical presentations that indicated involvement of more than one ganglion, the gasserian, geniculate, petrous, accessory, jugular and second and third dorsal root ganglia comprised a chain in which inflammation of a single ganglion could extend to nearby ganglia. A 71-year-old man presented with left. peripheral facial palsy with otalgia, vesicular eruption in V₂, V₃, C2, C3 dermatome, tinnitus, and hearing loss.

Key word : Ramsay-Hunt syndrome, V₂, V₃, C2, C3 dermatome



Address for correspondence
Chung Seok Lee, M.D.
 Department of Neurology, Seoul Veterans Hospital Dunchon-dong 6-2, Gangdong-gu, Seoul, 134-791, Korea
 Tel : +82-2-2225-1324 Fax : +82-2-2225-1327
 Email : nrlee7@freechal.com

IgG

V₂, V₃

Brackman

test)

가

House-
가
(blink reflex

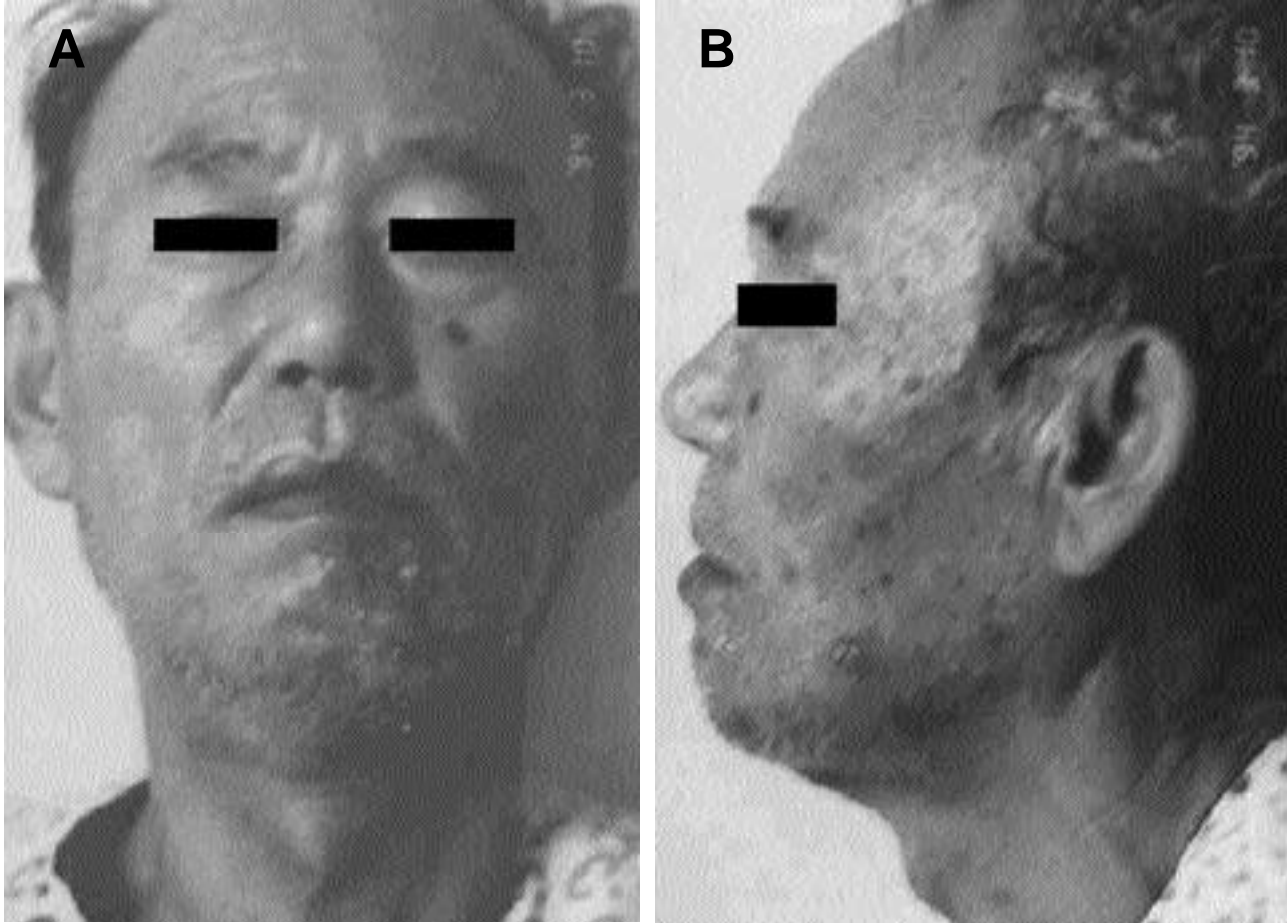


Figure 1. The front view(A) and lateral view(B) of the patient. The patient shows the vesicular rash in the left face and neck.

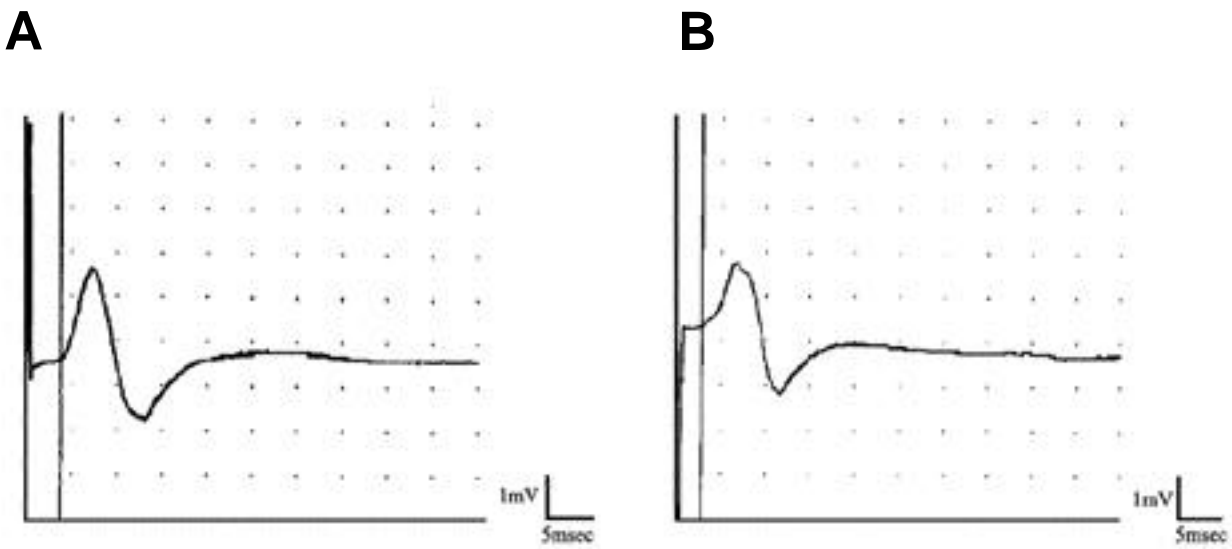


Figure 2. Facial nerve conduction study shows the prolonged latency(3.8ms) in left (A)and normal latency(2.8ms) in right.(B).

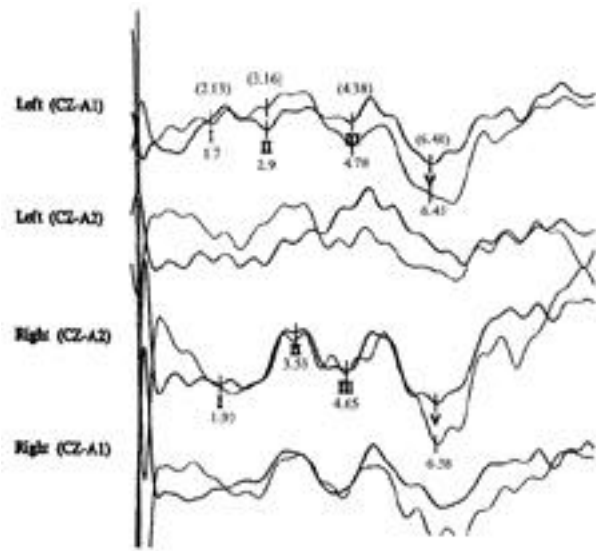


Figure 4. Right and left BAEP findings shows the prolonged absolute latencies to wave III, wave V and normal interlatencies in wave III-wave V, wave I-wave V. () : maximal normal range

가
 가 가
 PCR(polymerase chain
 reaction)
 9
 Ramsay-Hunt
 wave III, wave V
 (retrocochlear
 lesion)
 가
 10
 wave III, wave V
 가
 (cochlear nucleus)
 11 7
 15
 가 (pinna)
 가
 acyclovir
 3
 prednisolone

Table 1. Ramsay-Hunt's syndrome : original 1907 classification

Infection	Occur without neurologic signs Herpes of auricle and external auditory canal
Neurologic effects	Aural herpes with facial nerve paralysis
Functional loss	Herpes auricularis and facial palsy with to affected area
	acoustic nerve involvement (range from tinnitus and diminished hearing to severe involvement, such as Meniere's disease)

Ramsay-Hunt

REFERECES

1. Sweeney CJ, Gilden DH . Ramsay-Hunt Syndrome. *Neurol Neurosurg Psychiatry* 2001;71:149-154.
2. House JW, Brackmann DE. Facial nerve grading system. *Otolaryngo Head Neck Surg* 1985;93:146-147.
3. Brody IA, Wilkins RH. Ramsay-Hunt Syndrome. *Arch Neurol* 1968;18:215-23.
4. Krol TC, Mullen MG. Herpes zoster with facial paralysis: an unusual manifestation. *Arch Neurol* 1980;37:391.
5. Hunt JR. The symptom-complex of the acute posterior poliomyelitis of the geniculate, auditory, glossopharyngeal and pneumogastric ganglia. *Arch Intern Med* 1910;5:631-75.
6. Lapresle J, Lasjaunias P. Cranial nerve ischemic arterial syndromes. *Brain* 1986;109:207-215.
7. Lee DK, Kwak KH, Do JK, Oh HJ. Herpes zoster with multiple cranial and upper cervical nervous involvement. *Korean J Neurology* 1997;3:712-715.
8. Shin KW, Yang IA, Cho KS, Im SK. Clinical analysis of the prognosis Ramsa-Hunt syndrome. *Korean J Otolaryngol* 1995;38:57-63.
9. Murakami S, Honda N, Mizohuchi M, Nakashiro Y, Hato N, Gyo K. Rapid diagnosis of varicella zoster virus infection in acute facial palsy. *Neurology* 1998;51:1205-5.
10. Abramovichs, Prasher DK. Electrocochleography and brain-stem potentials in Ramsay-Hunt syndrome. *Arch Otolaryngol Head Neck Surg* 1986;112:925-928.
11. Seo DW. Auditory information processing to the cerebral cortex. The 5th annual spring meeting of the Korean society for clinical neurophysiology 2002;35-41.