

A Case of Painful Trigeminal Neuropathy as a Complication of Progressive Systemic Sclerosis

Kyong Jin Shin, M.D., Dong Chul Jun, M.D., Ju Han Kim, M.D., Seung Hyun Kim, M.D.

Department of Neurology, College of Medicine, Hanyang University

Progressive systemic sclerosis (PSS) is a multi-systemic disorder characterized by abundant fibrosis of the skin, blood vessels, and visceral organs. But it rarely affects the peripheral nervous system. We report a 36-year-old man of painful trigeminal neuropathy as a complication of PSS. He was referred from Rheumatology for the evaluation of abruptly developed bilateral facial pain. He had facial hypesthesia and paresthesia on neurologic examinations. In the blink reflex, ipsilateral and contralateral R1 and R2 responses were not detected during bilateral supraorbital stimulation. But normal latency and CMAP amplitude of facial NCV were found. Under the impression of trigeminal neuropathy caused by PSS, steroid therapy was tried, and his clinical symptoms and electrophysiologic findings were improved. PSS could be the cause of the painful trigeminal neuropathy.

Key Words : Progressive systemic sclerosis, Painful trigeminal neuropathy, Blink reflex

(progressive systemic sclero-
sis; PSS) 가
1-3
1,4-6 PSS
35 가 2
3
(CMAP)
R1, R2 R2
PSS (Fig. 1).

2
Subcommittee for scleroderma criteria of the
American Rheumatism Association Diagnostic and
Therapeutic Criteria Committee Preliminary
criteria for the classification of systemic sclerosis
(scleroderma) (PSS)
(prednisolone 10mg daily)
(methotrexate 16 mg weekly)
가

Address for correspondence
Seung Hyun Kim, M.D.
Department of Neurology, College of Medicine, Hanyang University
Hangdang dong, Sungdong Gu, Seoul 133-792
Tel : +82-2-2290-8367, Fax : +82-2-2299-2391
E-mail : kimsh1@hanyang.ac.kr

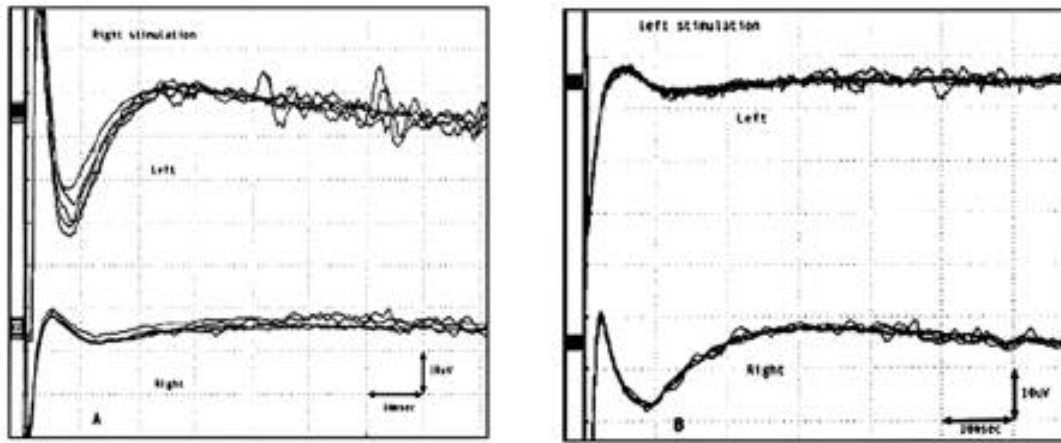


Figure 1. Blink reflex (A: right, B: Left) and facial NCV (C). In the blink reflex, ipsilateral R1 and R2 and contralateral R2 responses are not detected during right and left supraorbital nerve stimulation respectively. Normal latency and amplitude of CMAP are noted during right and left facial nerve stimulation.

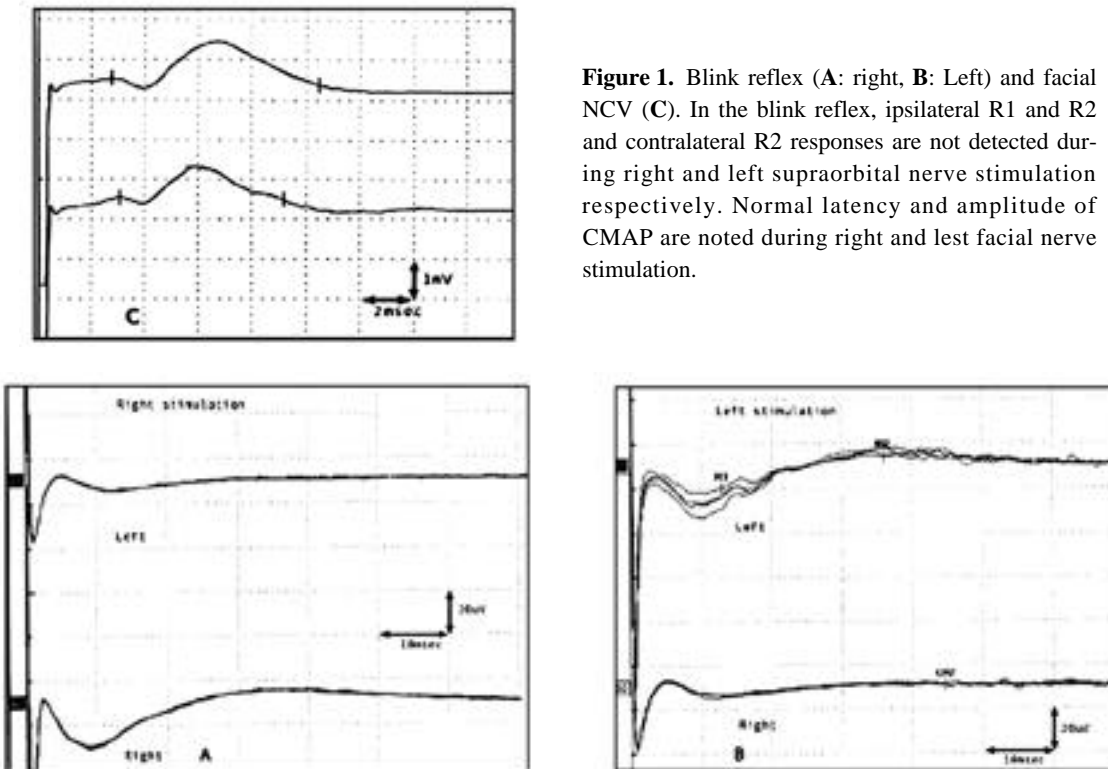


Figure 2. Follow up blink reflex after 3 months later. The ipsilateral R1 and R2 and the contralateral R2 responses, which were not found initially are detected during the left supraorbital nerve stimulation. However, the R1 response is prolonged and the ipsilateral and contralateral R2 responses are still not detected during the right supraorbital nerve stimulation.

prednisolone 30 mg car-
bamazepine 600 mg 가 .
3

가 , , ,
(47%),
(26%) (19%)
R1
(=11.0 msec), R2 (=31.5 msec) R2
, 1.7 Soubrier¹⁰ 4 PSS, 4
(=30.9 msec), 4 12
R1 (18.3 msec)
가 가 R2 PSS
(0.8% ~ 18.5%)⁴ Farrell⁷ 442
PSS 16

. PSS

7

PSS

PSS

PSS

neuropathy)

가 가

2 PSS

PSS

가

1,9

(entrapment

T1

Fischhoff

1,9

PSS 가

3

가

REFERENCE

1. Jimenez-Moreno J, Selva-O 'Callaghan A, Rovira-Canellas A, Solans-Laque R, Len O, Olias M. Trigeminal

sensory neuropathy in systemic sclerosis. *Br J Rheumatol* 1998;37:587-589.

2. Fischhoff DK, Sirois D. Painful trigeminal neuropathy caused by severe mandibular resorption and nerve compression in a patient with systemic sclerosis: case report and literature review. *Oral Surg Oral Med Oral Pathol Oral Radiol Endod* 2000;90:456-459.

3. Lee S. Polyneuropathy in progressive systemic sclerosis. *J Korean Neurol Assoc* 2000;18:102-105.

4. Gordon RM, Silverstein A. Neurologic manifestations in progressive systemic sclerosis. *Arch Neurol* 1970;22:126-134.

5. Sukenik S, Abarbanel JM, Buskila D, Potashnik G, Horowitz J. Impotence, carpal tunnel syndrome, peripheral neuropathy as presenting symptoms in progressive systemic sclerosis. *J Rheumatol* 1987;14:641-643.

6. Lee P, Bruni J, Sukenik S. Neurological manifestations in systemic sclerosis (scleroderma). *J Rheumatol* 1984;11:480-483.

7. Farrell DA, Medsger TA Jr. Trigeminal neuropathy in progressive systemic sclerosis. *Am J Med* 1982;73:57-62.

8. Tuffanelli DL, Winkelmann R. Systemic scleroderma: a clinical study of 727 cases. *Arch Dermatol* 1971;84:359-371.

9. Forster C, Brandt T, Hund E, et al. Trigeminal sensory neuropathy in connective tissue disease: Evidence for the site of the lesion. *Neurology* 1996;46:270-271.

10. Soubrier M, Vidailhet M, Clavelou P, et al. Trigeminal neuropathy and connective tissue diseases. *Ann Med Intern (Paris)* 1993;14:379-382.