

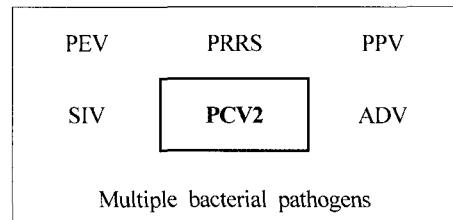
# 돼지 이유후 전신소모성 증후군 (Postweaning Multisystemic Wasting Syndrome : PMWS)

김 재 훈  
수의과학검역원 병리과

## Synonym of disease : other PCV2 related lesions

- PDNS (Porcine dermatitis and nephropathy syndrome)
- Acute PRRS hepatitis
- Hepatitis in CD/CD pigs
- Proliferative Necrotizing Pneumonia (PNP)

to reproduce the more clinically severe forms of PMWS.



PMWS

## History and epidemiology

PMWS is a recently described disease of growing pigs characterized by progressive weight loss and chronic pneumonia. PMWS was first identified in western Canada in 1995, and has been diagnosed in USA, Europe, and Asia. PMWS is a particular severe problem in UK, France, and Spain. The World Organization for Animal Health (Office International des Epizooties - OIE) is considering adding PMWS to the list of pig diseases that must be declared internationally by infected countries in order to control international spread by trade. Listing of PMWS might be approved by the International Committee of OIE at the next review in May 2002. If so, the 158 member countries of OIE would be required report any occurrence of PMWS and possibly also obey surveillance criteria when trading pigs and pig products.

Type 2 porcine circovirus (PCV2) is consistently demonstrable in typical PMWS lesions, and inoculation of pigs with PCV2 induces lesions and clinical signs consistent with PMWS

## Causative agents

PCV2 is most commonly demonstrated in cases of PMWS. Many experimental findings and anecdotal information suggest that co-infection with other agents is necessary

## Pathogenesis

Not clarified until now. There are genetic, antigenic and virulence differences among isolates of PCVs.

## Clinical signs

### PMWS

Starts at about 6~16 weeks of age, especially between 8~12 weeks. Pigs show chronic wasting, pale skin color, and enlarged lymph nodes. They usually develop jaundice and a decreased growth rate. In some less specific cases, there are some respiratory and digestive (diarrhoea, gastric ulcers) signs. The proportion of weaners affected varies but the mortality in those that are affected is high.

### PDNS

The most striking clinical sign in severely affected grower or finisher pigs is an extensive dermatitis mainly over the chest, abdomen, thighs and forelegs appearing as purplish red bumps of varying sizes and shapes. The pigs are depressed and may have a fever and be reluctant to move or eat. They may breathe heavily. Mortality is often around 15% but can be much higher. Pigs that recover may be permanently unthrifty

## Gross findings

### PMWS

The gross lesions are characteristic. The carcass is emaciated and jaundiced. The spleen and lymph nodes throughout the body are very enlarged, the kidneys sometimes are swollen with white spots visible and the lungs are rubbery and mottled.

Organ	Lesion
Skin	Icterus, pallor
Lung	Diffuse noncollapse, firm and rubbery Atelectatic or consolidated middle & cranial lobes
Lymph nodes	Enlargement (inguinal, mesenteric, bronchial) Homogeneous and white on cut surface
Liver	Normal, prominent interlobular septa
Kidney	Enlarged and pale, white foci
Spleen	Moderately enlarged
Other lesions	Gastric ulcer in pars esophagea

### PDNS

At autopsy examination, lymph nodes, particularly at the rear of the abdomen, may be red and enlarged and there may be fluid in the abdomen. The most consistent lesions are in the kidneys, which appear mottled with many small haemorrhages. Multiple skin spots (papules) may be seen, particularly on the hindlimbs.

## Histopathology

### PMWS

Microscopically the lesions are also characteristic.

Organ	Lesion
Lymph nodes	Histiocytic to syncytial cell infiltration, basophilic inclusion bodies (I/B), coagulative necrosis, vasculitis
Lung	Diffuse interstitial pneumonia, lymphohistiocytic to granulomatous infiltration, airway epithelial sloughing, airway fibroplasia, bronchiolitis obliterans

Organ	Lesion
Liver	Lymphohistiocytic (peri)cholangitis, apoptosis of hepatocytes, multifocal hepatitis
Kidney	Lymphohistiocytic interstitial nephritis, edema and/or fibrosis, vasculitis
Lymphoid organs	Lymphohistiocytic infiltration, depletion, I/B and/or syncytial cells

### PDNS

Photos of the histological changes have been published by Rosell et al (see Literature). A hyper-immune reaction in the blood vessel walls is the primary lesion of porcine dermatitis and nephropathy syndrome. This may progress to systemic necrotising vasculitis. When renal lesions are present, they take the form of severe diffuse fibrinous glomerulitis in acute cases, or interstitial fibrosis and glomerular sclerosis in chronic cases. Skin papules have been linked with dermal necrotising vasculitis.

Lymphocyte depletion is common in lymphoid tissues. Multinucleated syncytia may be present in trabecular or subcapsular sinuses, or in the follicular centres of lymph nodes. Occasionally, granulomas with epithelioid and syncytial cells have been observed.

## Diagnosis

### Clinical Dx.

- Reported age of onset : variable (2~20 weeks)
- Morbidity & mortality : variable (1~20% <) & 5~10%
- Clinical signs are not diagnostic: wasting, dyspnea, cough etc.
- Gross findings are not diagnostic : swelling of lymph-nodes, rubbery and noncollapsed lung

### Laboratory Dx.

- Histopathology : esp. in lung, lymph-nodes etc.
- IHC (Immunohistochemistry), ISH (*In situ* hybridization), VI (Virus isolation), PCR, Serology
- ☆ PMWS requires that pigs exhibit all of the following: clinical signs, histologic lesions, PCV2 infection within characteristic lesions, so PCV2 infection ≠ PMWS

### Differential diagnosis:

- Classical swine fever (Hog cholera)
- Aujeszky's disease
- Porcine Reproductive and Respiratory Syndrome (PRRS)
- Swine influenza virus (SIV) infection
- Other bacterial infection such as Glässer's disease, APP, Salmonellosis etc.

### Treatments and prevention

There are no vaccines available. Biosecurity precautions (isolating incoming pigs and having farm perimeter security) seems to be important in preventing herd outbreaks of PMWS.

• 한국수의병리학회 홈페이지(<http://vetpathology.or.kr>)에서 동영상으로 설명을 들을 수 있습니다.

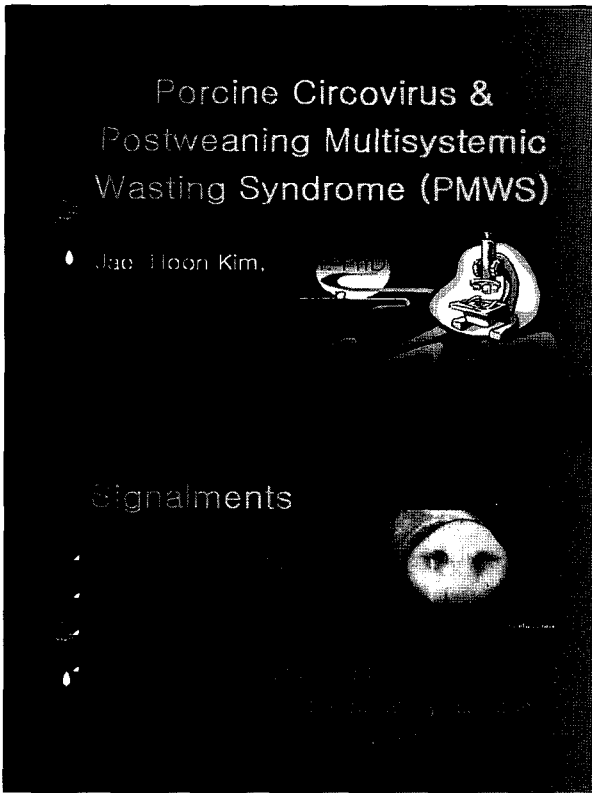


그림1, 2

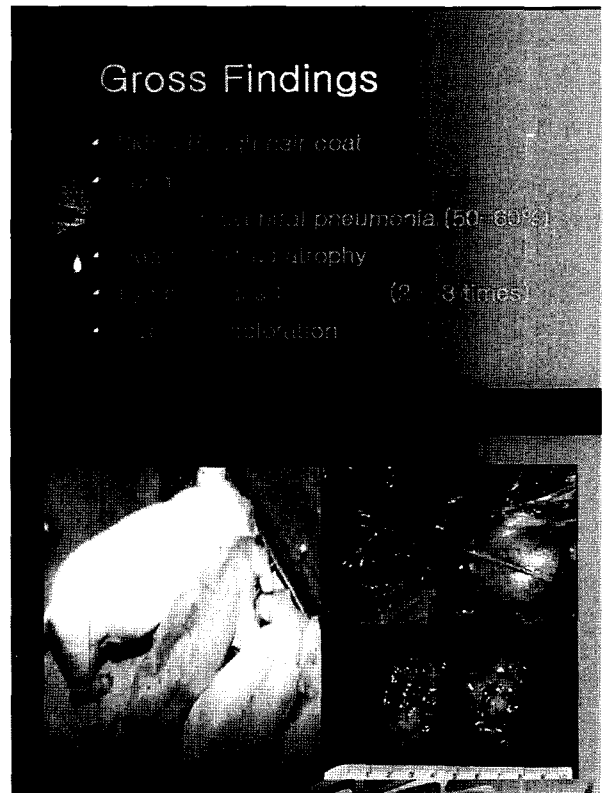


그림3, 4

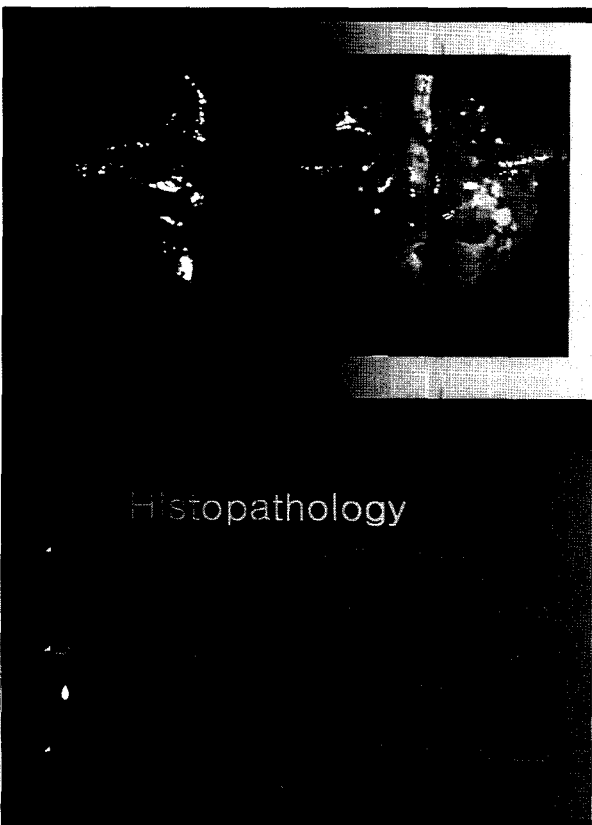


그림5, 6




그림7, 8






그림17, 18




그림19, 20

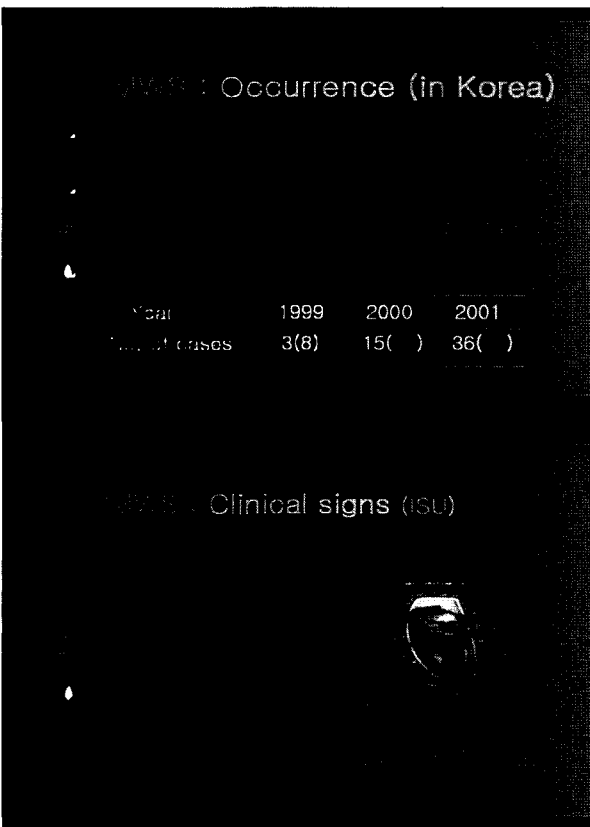


그림21, 22

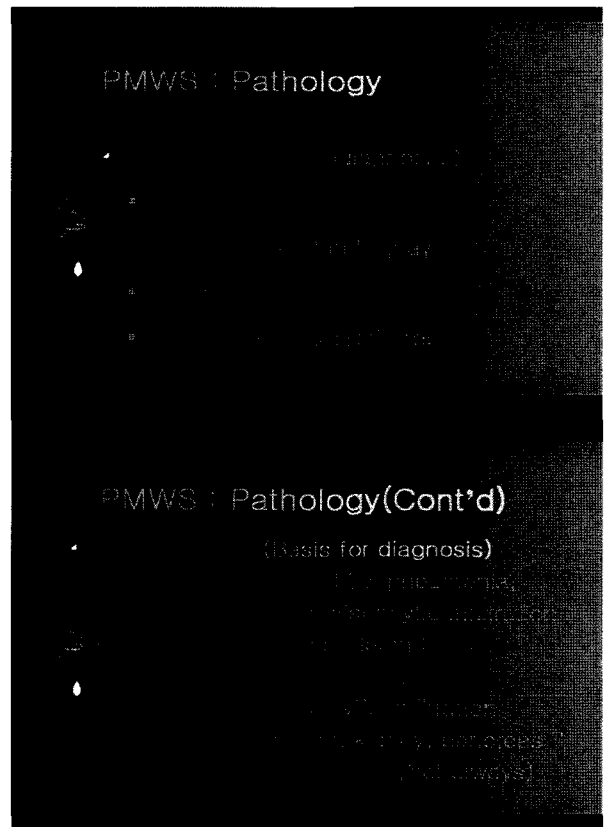


그림23, 24




그림25, 26

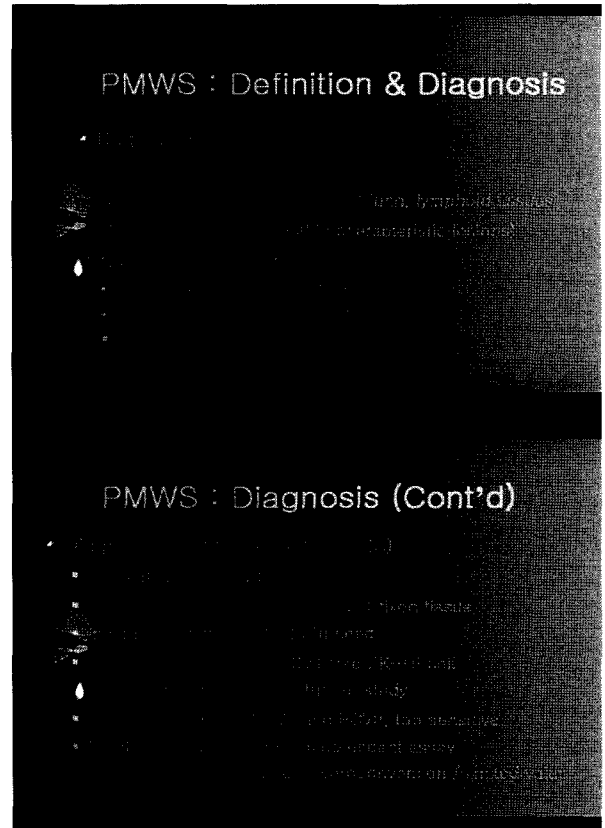


그림27, 28




그림29, 30

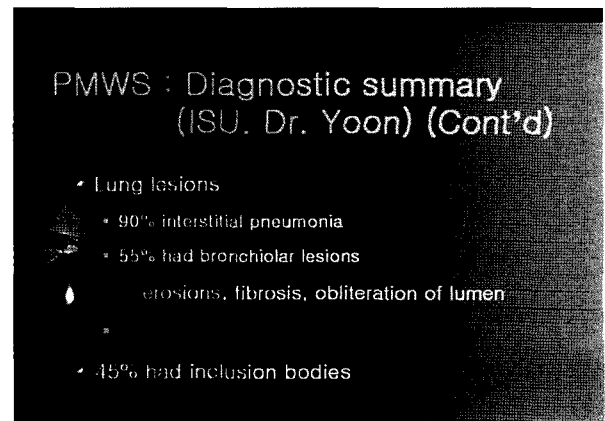


그림31