

## 거미낭으로 일과성 정신병 유발이 의심되고 리스페리돈 치료에 효과적이었던 증례

박원명\* · 배치운\*<sup>†</sup> · 전태연\* · 김광수\* · 유태열\*

### A Case of Transient Psychosis Suspected to be Induced by Arachnoid Cyst, Which was Responsive to Risperidone

Won-Myong Bahk, M.D.,\* Chi-Un Pae, M.D.,\*<sup>†</sup> Taeyoun Jun, M.D.,\*  
Kwang-Soo Kim, M.D.,\* Tae-Yul Lew, M.D.\*

#### ABSTRACT

There had been few reports of arachnoid cyst accompanying psychiatric disturbance and no report treated with low-dose risperidone administration. We report a patient, developed first-transient psychotic episode considered to be provoked by an arachnoid cyst, responsive to risperidone, which was found in the middle cranial fossa as follows.

A 57-year-old man was admitted by suddenly developed headache, auditory hallucination, delusion of persecution and, an arachnoid cyst in the anteromedial aspect of middle cranial fossa was found on MRI after admission. The psychotic episode was first to him and he was also negative to other clinical evaluation including endocrine abnormality, his psychotic symptom was suspected to be induced by arachnoid cyst and was well controlled to low-dose risperidone administration. He left hospital free from psychotic symptoms on 14 hospital days.

**KEY WORDS** : Arachnoid Cyst · Transient Psychosis · Risperidone.

#### 서 론

(arachnoid cyst)

1%

가

1986).

가

Mazza 1985).

(suprasellar area),

(Auer 1981).

가

(mental impairment)  
(Rocco 2001).

(Wong 1993 ; Lanczik 1989 ;

Blackshaw Bowen 1987)

\*가

Department of Psychiatry, St. Mary's Hospital, College of Medicine, The Catholic University of Korea, Seoul, Korea

<sup>†</sup>교신저자 : , 150 - 713 62  
) (02)3779 - 1250, ) (02)780 - 6577  
E - mail) pae@cmc.cuk.ac.kr

가

uated inversion recovery image(FLAIR image)

가

57

cyst)

(epidermoid

가

### 증 례

57

1mg

2mg

5

5

가

14

2mg

### 고 찰

(Folstein 1975)

MRI

27

가

가

. Tc99m - ECD

가

(single positron emission

computerized tomography : SPECT)

(magnetic re-

가

가

sonance imaging : MRI)

3 × 2.5 × 2cm

( 1).

fluid atten-

가

가

가 57

가

가

(McCarley 1993 ; Soniat 1951)

76%

Lanczik (1989)

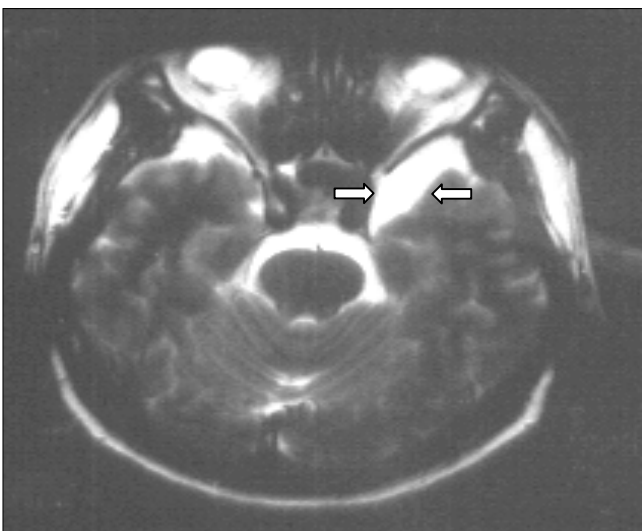


Fig. 1. T2-weighted image of MRI shows ovoid-cystic lesion in the middle cranial fossa.

가

2mg

중심 단어 :

참고 문헌

가  
(Sipahimalani Masand 1997 ; De Deyn 1999)  
Lanczik (1989)

P 300 (topographic mapping of EEG and  
P300)  
MRI, SPECT

가

가

가

결 론

57

가

3 × 2.5 × 2cm

가

가

**Auer LM, Gallhofer B, Ladurner G, Sager WD, Heppner F, Lechner H(1981)** : *Diagnosis and treatment of middle fossa arachnoid cysts and subdural hematomas. J Neurosurg 54 : 323-326*

**Beltramello A, Mazza C(1985)** : *Spontaneous disappearance of a large middle fossa arachnoid cyst. Surg Neurol 24 : 181-183*

**Blackshaw S, Bowen RC(1987)** : *A case of atypical psychosis associated with alexithymia and a left fronto-temporal lesion : possible correlations. Can J Psychiatry 32 : 688-692*

**De Deyn PP, Rabheru K, Rasmussen A, Bocksberger JP, Dautzenberg PL, Eriksson S, Lawlor BA(1999)** : *A randomized trial of risperidone, placebo, and haloperidol for behavioral symptoms of dementia. Neurology 53 : 946-955*

**Folstein MF, Folstein SE, McHugh PR(1975)** : *Mini-Mental State : a practical method for grading the cognitive state of patients for the clinician. J Psychiatr Res 12 : 189-198*

**Lanczik M, Fritze J, Classen W, Ihl R, Maurer K(1989)** : *Schizophrenia-like psychosis associated with an arachnoid cyst visualized by mapping of EEG and P300. Psychiatry Res 29 : 421-423*

**McCarley RW, Shenton ME, O'Donnell BF, Faux SF, Kikinis R, Nestor PG, Jolesz FA(1993)** : *Auditory P300 abnormalities and left posterior superior temporal gyrus volume reduction in schizophrenia. Arch Gen Psychiatry 50 : 190-197*

**Nardich TP, McLane DG, Radkowski MA(1986)** : *Intracranial arachnoid cyst. Pediatr Neurosci 12 : 112-122*

**Rocco C(2001)** : *Arachnoid cyst. In Neurological Surgery, 5th Ed, Ed by Winn M, Youmans JR, Philadelphia, W-B Saunders Company, pp967-994*

**Soniati TLL(1951)** : *Psychiatric symptoms associated with intracranial neoplasm. Am J Psychiatry 108 : 19-22*

**Sipahimalani A, Masand PS(1997)** : *Use of risperidone in delirium : Case reports. Ann Clin Psychiatry 9 : 105-107*

**Wong CW, Ko SF, Wai YY(1993)** : *Arachnoid cyst of the lateral ventricle manifesting positional psychosis. Neurosurgery 32 : 841-843*