

Granulosa Cell Tumor of Scrotal Tunics: A Case Report

Eun-Kyung Ji, MD^{1,2}
Kyoung-Sik Cho, MD¹

We report a case of adult granulosa cell tumor arising in the scrotal tunics. The patient was a 34-year-old man who presented with right scrotal swelling, first noticed four months previously. Under the initial clinical impression of epididymo-orchitis, antibiotic treatment was instituted but there was no response. The paratesticular nodules revealed by ultrasound and magnetic resonance imaging mimicked intratesticular lesion, and radical orchiectomy was performed. Although several cases of adult testicular granulosa cell tumor, have been reported, the occurrence of this entity in the paratesticular area has not, as far as we are aware, been previously described.

Index terms :

Scrotum, MR
Scrotum, neoplasm
Scrotum, US

Korean J Radiol 2001;2:117-120

Received October 20, 2000; accepted after revision March 9, 2001.

Department of ¹Diagnostic Radiology, Asan Medical Center, University of Ulsan, Seoul, Korea; Department of ²Diagnostic Radiology, Kangnam CHA Hospital, Pochon CHA University, Seoul, Korea.

Address reprint requests to:

Eun-Kyung Ji, MD, Department of Diagnostic Radiology, Kangnam CHA Hospital, 650-9 Yuksam-dong, Kangnam-gu, Seoul 135-081, Korea.
Telephone: (822) 3468-3126, 3117
e-mail: jiek@chamc.co.kr

Paratesticular tumors are relatively rare, occurring only about one-tenth as often as tumors of the testis (1), and imaging studies have therefore been limited to small series (2-6). Most paratesticular masses are benign and include sperm granuloma, fibrous pseudotumor, adenomatoid tumor of the epididymis or tunica albuginea, lipoma, leiomyoma, and inflammatory nodule (3, 7). About 3-16% of solid paratesticular masses are malignant (7, 8), and among these, rhabdomyosarcoma is the most common. We recently encountered a patient with adult-type granulosa cell tumor of the scrotal tunics. Although extratesticular gonadal stromal tumor in the pelvis has been reported (9), the literature in English contains no description of a paratesticular granulosa cell tumor. In this report, we describe the ultrasound (US) and magnetic resonance (MR) findings of such a tumor.

CASE REPORT

A 34-year-old man with painless right scrotal swelling, first noticed four months earlier, was admitted to our hospital. The patient had no history of scrotal trauma, voiding difficulty, other genitourinary diseases or weight loss. Physical examination showed that the right side of the scrotum was noticeably enlarged, without tenderness. Laboratory studies were unremarkable, with normal levels of alpha-fetoprotein (1.70 ng/ml; normal range: < 20 ng/ml) and beta-human chorionic gonadotropin (3.42 mIU/ml; normal range: < 5 mIU/ml). Under the impression of right epididymo-orchitis, he was treated with antibiotics for two weeks but showed no improvement.

Scrotal US revealed a well-defined heterogeneous hypoechoic intratesticular lesion of the right testis, with large hydrocele and diffuse irregular epididymal swelling. Also noted were slightly heterogeneous echogenic nodular projections attached to the inner scrotal wall (Fig. 1A). The left testis and epididymis were normal. For further evaluation, MR imaging was performed, and this demonstrated nodules in the testis, epididymis and inner scrotal wall. The nodules were isointense on T1-weighted images

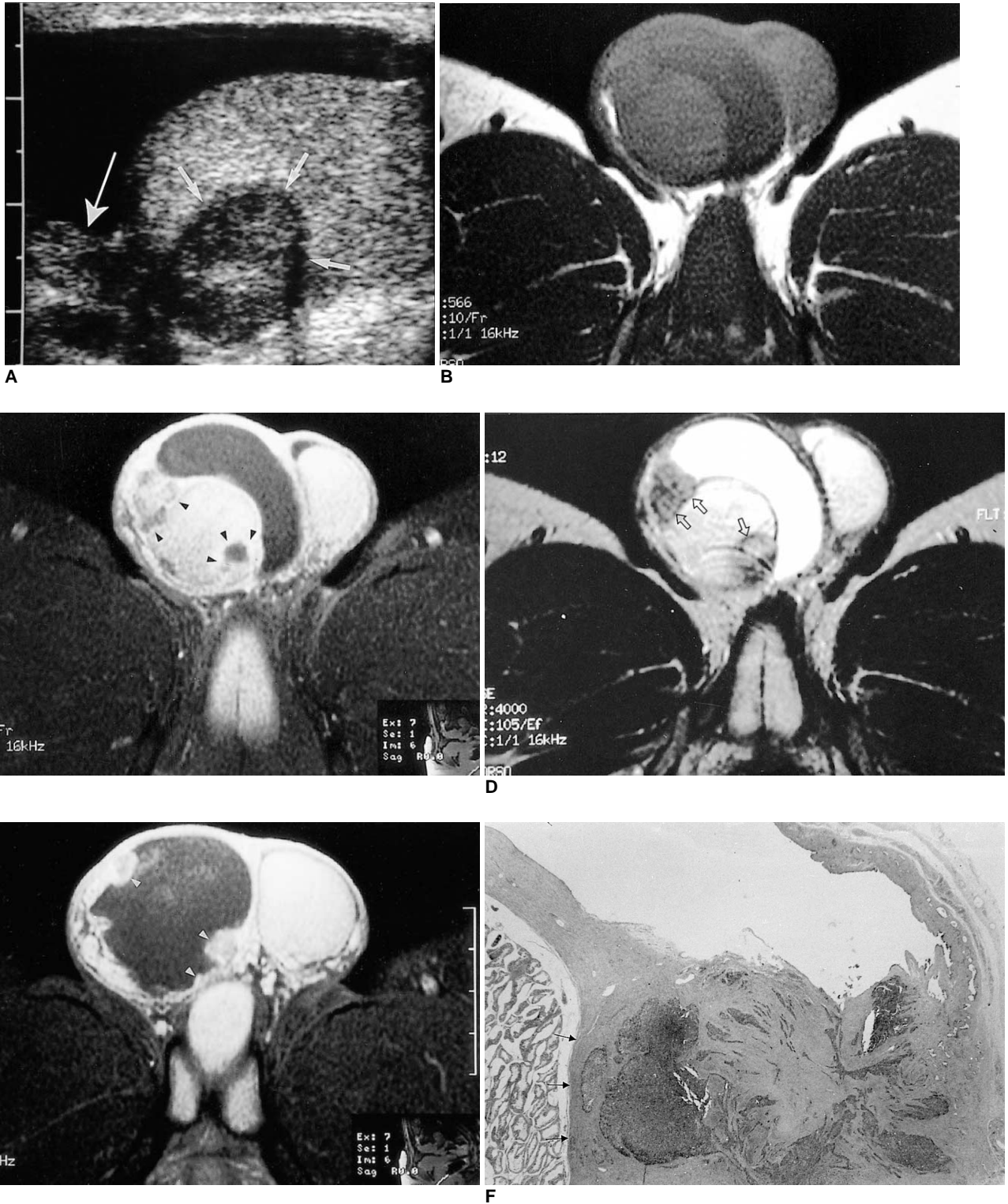


Fig. 1. Axial MR images of the scrotum.
A. Sagittal sonogram of the right side of the scrotum. A well-defined hypoechoic mass (short arrows) in the testis and a small hypoechoic nodule adjacent to the upper pole of the testis (long arrow) are seen. Extensive hydrocele is present.
B, C. T1-weighted (**A**), Gd-enhanced T1-weighted (**B**), and T2-weighted (**C**) MR images reveal well-defined nodules in the testis and adjacent to it. In image **B**, strong peripheral enhancement is observed (arrowheads). Note that on the T2-weighted image there is a dark rim that separates normal testis from the nodule (arrows).
E. In the lower portion of the scrotum there is extensive hydrocele, and small enhancing nodules (arrowheads) are seen along the inner margin of the scrotal wall.
F. Pathologic findings of the tumor. Histopathologic specimen shows a nodule between the tunica vaginalis and the testis. Note the preservation of the inner margin of the tunica albuginea (arrows) (H and E, original magnification $\times 40$).

and slightly hyperintense on T2-weighted images. T2-weighted imaging of the intratesticular lesion revealed a low-signal-intensity rim. After infusion of gadopentetate dimeglumine (Gd) (Magnevist; Berlex, Wayne, N.J., U.S.A.), the peripheral portions of these nodules were markedly enhanced (Fig. 1B-E).

Because malignancy was suspected, the patient underwent right radical orchiectomy, and right hydrocele with testis was dissected out without difficulty. On pathologic examination of the resected specimen, variable-sized multiple nodules were seen on the surface of the tunica vaginalis and albuginea; the largest one was attached to the posterolateral portion of the testis. Microscopic examination revealed that the nodules were confined to the tunica vaginalis and albuginea, without penetrating the testis, and between this and the nodules there was a clear plane of separation (Fig. 1F). The testis and epididymis were normal. The tumor cells were oval, or round to elongated, with occasional longitudinal nuclear grooves and Call-Exner bodies, and mitosis was frequently observed (nine mitoses/ten high-power fields, on average). Immunohistochemical staining demonstrated diffuse strong positivity for inhibin, vimentin and cytokeratin. A comparison of the microscopic findings and those of MR imaging indicated that the hypointense rim seen at the periphery of the nodules on T2-weighted images corresponded with intact tunica albuginea.

DISCUSSION

Although granulosa cell tumor is the most common sex-cord stromal tumor to occur in the ovary, it is extremely rare in the testis and its origin is poorly understood. To the best of our knowledge, the literature in English is limited to only 19 cases of adult granulosa cell tumor of the testis (10). Moreover, the radiologic findings of this disease entity are not well known. We are aware of only two previous reports of the US findings of adult-type testicular granulosa cell tumor, and both of these described the tumor as a well-defined hypoechoic testicular mass (11, 12).

In our case, the tumor appeared to arise from the scrotal tunics, an unusual location for a sex-cord stromal tumor. It was, however, because of the presence of typical large indented nuclei with longitudinal nuclear grooves and Call-Exner bodies, as well as positive immunoreactivity for inhibin, keratin and vimentin, that granulosa cell tumor was diagnosed (13). Fourteen percent of all paratesticular tumors arise from the scrotal tunics and among these, benign fibroma, representing a fibrous reaction to chronic periorchitis, is the most common lesion (14). Although granulosa cell tumor arising from the scrotal tunics has not been pre-

viously reported, extratesticular sex-cord stromal tumor in the pelvis has been described (9). The suggested explanation is that the tumor originated in a residual part of the primitive gonad or a third undescended testis which was completely destroyed by the process, and we believe that in our case the same explanation is possible.

Pathologic examination indicated that this tumor had originated from and was confined to the scrotal tunics. The testis and epididymis were normal and easily separated from the tumor. Nevertheless, because the largest nodule was deeply invaginated into the testis, displacing the epididymis, which was compressed and not visualized, the location of this tumor - according to the findings of US and MR imaging - was intratesticular and epididymal. It was because the main lesion was in the testis and epididymis, and multiple small nodules were attached to the inner scrotal wall, that malignancy was suspected. On the other hand, because of extensive hydrocele, the lesion also mimicked an inflammatory condition such as tuberculous epididymo-orchitis. The only clue to the origin of the mass was the low-signal-intensity rim between the lesion and the testis revealed by T2-weighted imaging.

To our knowledge, this is the first reported case of paratesticular granulosa cell tumor, and it would therefore be premature to state that the US and MR features of our case are specific to granulosa cell tumor of the scrotal tunics. Although the formulation of a treatment plan might not require specific diagnosis, we suggest that the presence of a mass seen as an intratesticular lesion associated with multiple enhancing nodules attached to scrotal tunics indicates the possibility of a paratesticular tumor, and that granulosa cell tumor should be included in the differential diagnosis. We believe that MR imaging findings of a peripheral low-signal-intensity rim on a T2-weighted image might help determine the origin of the mass.

References

1. Hricak H, Hamm B, Kim B. *The epididymis, spermatic cord, and paratesticular tissue: congenital anomalies and tumors. In Imaging of the scrotum.* New York: Raven Press, 1995:129
2. Makarainen H, Tammela T, Karttunen T, et al. Intrascrotal adenomatoid tumors and their ultrasound findings. *J Clin Ultrasound* 1993;21:33-37
3. Holden A, List A. Extratesticular lesions: a radiological and pathological correlation. *Australas Radiol* 1994;38:99-105
4. Yeager B, Arger P, Mintz M, et al. The impact of sonography on the management of extratesticular abnormalities of the scrotum. *J Clin Ultrasound* 1989;17:573-577
5. Vick C, Bird K, Rosenfield A, Viscomi G, Taylor K. Scrotal masses with uniformly hyperechoic pattern. *Radiology* 1983;148:209-211
6. Haller J, Tscholakoff D, Gundry C, et al. Sonography of unusual extratesticular lesions. *Urol Radiol* 1989;11:190-193
7. Frates MC, Benson CB, DiSalvo DN, et al. Solid extratesticular

- masses evaluated with sonography: pathologic correlation. *Radiology* 1997;204:33-37
8. Beccia D, Krane R, Olsson C. Clinical management of non-testicular intrascrotal tumors. *J Urol* 1976;116:476-479
 9. Maurer R, Taylor CR, Schmucki O, Hedinger CE. Extratesticular gonadal stromal tumor in the pelvis: A case report with immunoperoxidase findings. *Cancer* 1980;45:985-990
 10. Jimenez-Quintero LP, Ro JY, Zavala-Pompa A, et al. Granulosa cell tumor of the adult testis: a clinicopathologic study of seven cases and a review of the literature. *Hum Pathol* 1993;24:1120-1125
 11. Nistal M, Lazaro R, Garcia J, Paniagua R. Testicular granulosa cell tumor of the adult type. *Arch Pathol Lab Med* 1992;116:284-287
 12. Gaylis FD, August C, Yeldandi A, Nemcek A, Garnett J. Granulosa cell tumor of the testis: Ultrastructural and ultrasonographic characteristics. *J Urol* 1989;141:126-127
 13. McCluggage WG, Shanks JH, Whiteside C, et al. Immunohistochemical study of testicular sex cord-stromal tumors, including staining with anti-inhibin antibody. *Am J Surg Pathol* 1998;22(5):615-619
 14. Feimanis MG, Bohm-Velez M, Mendelson EB, Erickson ER, Campanella SD. Ultrasound appearance of extratesticular myosarcoma. *J Clin Ultrasound* 1991;19:101-104