

# Maximizing cosmetic dentistry with bleaching and composite resin bonding



Wynn H. Okuda, D.M.D.

National Vice President, American Academy of Cosmetic Dentistry(AACD)  
Accredited Member, AACD  
Fellow, International College of Dentists

Throughout the world, the golden age of dentistry is starting to take place. Consumers are realizing how important a dynamic and beautiful smile can be in enhancing their personal and professional life. Regardless of race, it has been proven in psychological literature that there is substantiated correlation of between career success and attractiveness; in particular, facial attractiveness (Patzner, 1995, 1996, 1997; Chia, Allred, Grossnickle & Lee, 1998; Krebs & Adinolfi, 1975; etc.).

Since the early 1990's the American consumers have started to become obsessed with having the perfect smile. Cosmetic dental techniques such as bleaching, and bonded restorations such as porcelain veneers, direct composite veneers, became very popular. The influx of corporate manufacturers played a big role in helping to perfect the products that were used in order for the dentists to achieve good success and long lasting results. Presently, this phenomena of having a glamorous smile is now no longer restricted to just the wealthy individual and Hollywood actors and actresses. A recent survey taken by American Academy of Cosmetic Dentistry shows that 92% of those surveyed agree that an attractive smile is an important social

asset. 74% agree that an unattractive smile can hurt a person's chances for career success. Also, 85% agree that an unattractive smile makes a person less appealing to people of the opposite sex.

However, only 50% of those surveyed are satisfied with their smile<sup>1</sup>. Therefore, many consumers are conscious about the importance of good looking teeth and the impact it can make on them personally and professionally. However, this is not just limited to the American consumers. Many societies around the world, including Korea, are now seeing the value of how good appearing, healthy teeth can have on physical attractiveness and psychological well being.

Because many of these countries have not yet experienced the same "cosmetic dental boom" as America, the consumers of those countries may not be ready to invest in creating the "ultimate smile" (Figure 1a - 1d). Even without having to go to the extent of creating a full-mouth cosmetic rehabilitation, a dentist can create a beautiful end result with limited cosmetic dental treatment. By understanding basic principles in creating facial attractiveness, a dentist can routinely employ a combination of simple cosmetic dental techniques such as, bleaching, composite bonding,



and porcelain veneers and posterior esthetic procedures to achieve a nice result.

### Bleaching

With the proper diagnosis, case selection, and technique, bleaching can be the simplest, least invasive and least expensive approach to obtaining brighter teeth (Figure 2a & 2b). In order for the patient to be an appropriate bleaching candidate, the dentition should be relatively healthy with very little anterior restorations present. In addition, the teeth should already be in harmonious proportion to the face (Figure 3)<sup>2</sup>. It is the opinion of the author that if the patient with very unesthetic dental proportions (Figure 4a - 4c) is allowed to bleach their teeth, it can contribute detrimentally to their facial appearance. By brightening their unattractive teeth, it will bring unwanted attention to their already unattractive appearance. This could potentially lead to psychological trauma due to the negative response of a cosmetic dental procedure. However, on the appropriate patient, bleaching can be a tremendous enhancement procedure. However, on the appropriate patient, bleaching can be a tremendous enhancement procedure.

In the bleaching process, the basic process of oxidation takes places whereby causing the molecules of discoloration to be released. To accelerate this oxidation reaction, the use of heat and light devices has proved to be helpful. For over 20 years, bleaching, whether in-office or home bleaching, has helped many patients with discolored teeth. However, because of its new found popularity in the early 90's, aggressive marketing by manufacturers of bleaching materials

intended to be used without dental professional evaluation and monitoring became widespread. This disturbing trend that took place in America led to the use of bleaching for inappropriate dental conditions, poorly fitting mouthguards and very unesthetic and painful results. Through this experience, we have found that bleaching materials applied inappropriately may make existing dental problems worse<sup>3</sup>. Therefore, it is important that the dentist should understand the importance of proper diagnosis and the limits to the usage of bleaching agents (Figure 5a & 5b).

A good visual examination coupled with the appropriate number of radiographs will help determine the appropriateness of bleaching as the treatment modality of choice. The diagnostic work-up of pre-treatment photographs, periodontal examination and a dental prophylaxis (teeth cleaning) to remove superficial staining is important to complete prior to starting any bleach procedure. The present condition of all existing restorations should be noted and the medical history should focus on any pre-existing conditions that may be affecting tooth discoloration. In addition, the dentist should be aware of all personal habits of the patient such as tobacco, beverage and food. Foods that are heavily pigmented could contribute to discoloration as well. The pre-treatment records should also reflect baseline color of the dentition as well as note any pre-existing tooth sensitivity. These records are extremely important for legal and treatment purposes<sup>4</sup>.

There are many etiologies of discoloration; however, this can broadly be broken down into two categories- extrinsic and intrinsic stains<sup>5,6</sup>. In extrinsic stains, many



highly colored foods can affect tooth color. Coffee, tea, red wines can cause brown and black discoloration. Tobacco produces a yellow-brown to black stain along the cervical areas of teeth depending on the frequency of usage. In addition, superficial discoloration can occur along clinical crowns due to excessive iron supplementation, poor oral hygiene and the accumulation of dental plaque<sup>5</sup>. However, with a thorough cleaning and polishing, these stains can be readily removed from most smooth surfaces of the dentition.

The most difficult discolorations to remove are the intrinsic stains. Intrinsic stains are discolorations that occur when the tooth structure itself is penetrated by discoloring agents, usually during the adult tooth formative years. The variety of etiological factors include pulpal trauma, congenital problems (for example, phenylketouria, ochronosis), genetic abnormalities (for example, dentinogenesis imperfecta, amelogenesis imperfecta) and drug-induced stains (for example, tetracycline, minocycline, sulfur drugs). These associated factors can cause irreversible pigmentation in the adult dentition in varying colors and degrees of chromacity<sup>6</sup>. Thus, the modality of esthetic dental treatment is dependant on the severity of the color problem. Because enamel and dentin are inherently porous structures, the scientific basis for bleaching is good; however, even with the best bleach methods several types of stains are impossible to remove with long-term results. Knowing the potential limits to teeth bleaching is important to creating success in cosmetic dental treatment.

### The usage of bleach in combination with composite bonding

Because not all cosmetic dental cases can be treated by just teeth bleaching alone, it is important to understand how to use a variety of cosmetic dental materials in order to create esthetic end-results. In the last ten years, the science of composite resins have made tremendous strides. In the past, composite resins were not considered a reliable material. However, not only has the strength of composite resins gotten stronger, but also the color stability of these materials has increased with much improved technological advances. With the increased incorporation of filler particles, the shrinkage of the composite material as it converts from monomer to polymer has decreased. These advances has contributed to increasing the long-term survival of composite restorations by decreasing the adhesive stresses between the tooth and the composite resin restoration<sup>3</sup>. In addition, the range of available colors, opacifiers, tints and translucent resins have made composite resins a comprehensive, esthetic material with good long-term results that are used in conservative situations<sup>7</sup>.

When using composite resins in combination with bleach therapy, the dentist must be careful in the approach to this combined therapy. As teeth are bleached, the surface of the enamel is temporarily altered making it impossible to permanently adhere composite resin at the time. The surface alteration to the enamel lasts for a two week duration of time. Thereafter, it is possible to permanently bond composite resin to the adult dentition<sup>8</sup>. It is recommended that the bleached teeth be thoroughly cleaned prior to any bonded restorative procedure.



Using the newer flowable composite resins, the dentist is able to easily blend the new restoration to the tooth very conservatively. One of the greatest advantages to using flowable composite resins is the ease of usage in restoring conservative dental problems. Because there are different types of flowable composite resins, it is important that the dentist use the correct flowable resin for various dental problems (Figure 6a - 6e).

With the increase in the number of categories of composite resins, the dentist now has numerous options in creating conservative restorations. Earlier dental composite resins used the average particle size of 20 micrometers. Due to the large particle size, these composites were not very polishable, therefore allowing the uptake of stain and alteration of color of the composite. The modern composite resins have an average particle size that is reduced to less than 1.0 to 0.1 microns. When used in combination with fumed silica particles of 0.04 microns, a new category of hybrid composite resins is created that is now challenging the great properties of microfill composite resins<sup>9</sup>. This new category of "microhybrid" resins are claimed to provide surface smoothness and translucency similar to microfill resins with the strength of the traditional hybrid resins. The small particle size gives tremendous confidence to the dentist that the composite resin restoration will last a reasonable number of years<sup>10</sup>.

In situations where strength and high polish are needed in one material, these new microhybrids can be helpful in restoring conservative esthetic dental problems (Figure 7a - 7e). After bleaching of both dental arches with a night guard vital bleach tray, the new microhybrid resin was used to esthetically

enhance the appearance of this patient's smile. With composite resins it is possible to naturally blend the restoration to the surrounding dentition.

#### **Comprehensive usage of composite resin with home bleach therapy in esthetic dental rehabilitation**

Composite resins can be used to comprehensively reconstruct a patient's full smile. In conjunction with bleaching of the lower arch, state-of-the-art composite resins can be used in a direct resin veneer application.

In this case study, the patient had previously undergone orthodontic treatment to enhance her appearance. However, in getting the teeth in good esthetic alignment, an anterior openbite resulted (Figure 8a). The patient was referred to the author for correction and further esthetic evaluation because of the patient's unhappiness with her final esthetic appearance after orthodontic treatment. After utilizing cosmetic computer imaging and extensive patient consultation, a definitive esthetic and functional diagnosis was made. In determining the desired facial esthetic end result, a facial analysis was done (Figure 8b). The results of the analysis showed that the patient's teeth were not proportional to her face. In order to create a dynamic facial esthetic result, the dimensional size of the patient's teeth needed to be enlarged. By changing the morphology of the teeth, the resultant smile will be in better proportion to the patient's face, therefore creating a more dynamic face. In addition, the analysis also showed the need to modify the perio-esthetic line along the upper right cuspid and premolars in order to create better balance in the smile.

After proper healing of the periodontal plastic surgery procedure, it was decided that direct



composite resin veneers was the treatment of choice due to the patient's limited time availability. With the need to have her new esthetic smile ready in time for the Miss USA and Miss Universe national beauty pageant, direct hand-sculpted composite resin veneers allowed the author to solve her esthetic problems in a one-day appointment.

Direct hand-sculpted composite resin veneer procedure utilizing a combination of hybrid composite resin and microfill composite resin was performed such that the end result would create proper facial proportion and facial balance. Since the size of the patient's teeth from the upper right second premolar to the upper left second premolar were being increased in size, no tooth preparation was needed, and no dental anesthesia was used. Direct composite resin veneers were hand-sculpted one veneer at a time in the patients mouth (Figure 8c & 8d). Each composite resin veneer was fabricated to full polish then evaluated facially so that the objective of creating proper facial/dental proportion was being met (Figure 8e).

First, in order to meet the strength requirements needed for long-term occlusal success and to close the openbite problem the patient exhibited post-orthodontically, hybrid composite was bonded to the cleaned enamel surface along the lingual surfaces. By bonding hybrid composite to the facial and lingual surfaces, it helped to increase the overall strength of the restorations. Then, layers of different color microfill composite was bonded onto the hybrid layer to create a natural high polished surface. To fulfill the needs of the smile, ten direct handsculpted composite resin veneers were bonded from the upper right second premolar to the upper left second premolar, with no

teeth preparation (Figure 8f & 8g). This was an extremely conservative technique that maximized the esthetic end result. The result is a beautiful esthetic finish that is facially generated (Figure 8h). With the new, dynamic smile, this patient won the Miss USA and Miss Universe title in 1997 (Figure 8i). Cosmetic dentistry helped increase her facial attractiveness to change her life forever.

In creating cosmetic dentistry with combination therapy using bleaching and composite resin, fantastic result can be achieved. Provided that the dentist takes the time to understand the proper use of current esthetic dental materials and good cosmetic dental procedural technique, long lasting esthetic results can be obtained. In addition, it is important that the dentist esthetically diagnose the case correctly. In order to achieve consistent success with cosmetic dentistry, obtaining good education is extremely important for dentists. Conferences such as the Pan Pacific Dental Institute Conference(Hawaii, 2001) and the American Academy of Cosmetic Dentistry Annual Session (Hawaii, 2002)can provide state-of-the-art education in the important area of cosmetic dentistry.

As we enter the new millennium, state-of-the-art cosmetic dentistry has changed the opinion that patients have on dentists. Our ability to re-create nature as well as enhance the beauty of our patient's faces has helped elevate the stature of the dental profession. Providing consistent esthetic dental results no longer has dentists associated with pain, but as artists (Figure 9). By providing patients with the combined therapy of bleaching and composite resin bonding, the dentist is able to provide quality cosmetic dental care using limited dental treatment.

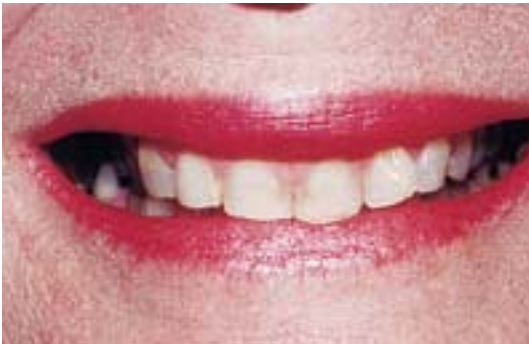

Figure 1a. The typical aged dentition of the middle-aged woman.

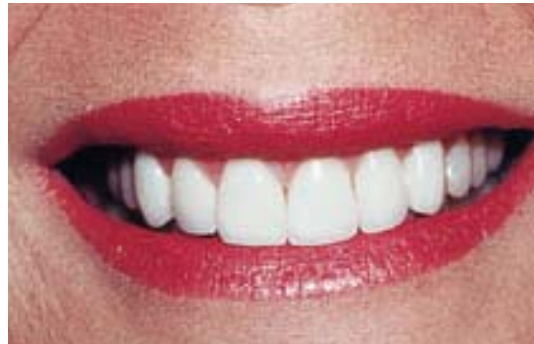

Figure 1b. "The Ultimate Smile" - Full mouth cosmetic and reconstruction rehabilitation with bonded porcelain restorations.

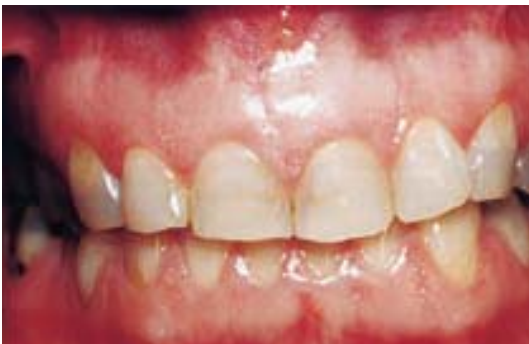

Figure 1c. Pre-treatment - esthetics and functional-related problems.

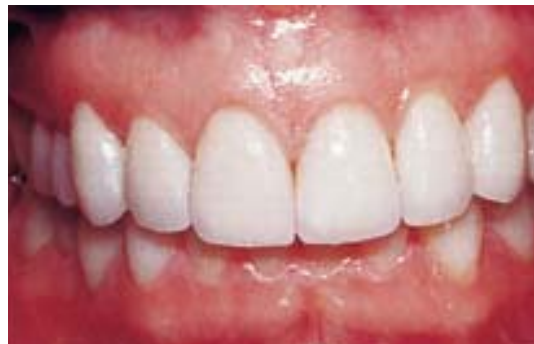

Figure 1d. Post-treatment - esthetic and functional correction with bonded porcelain restorations.

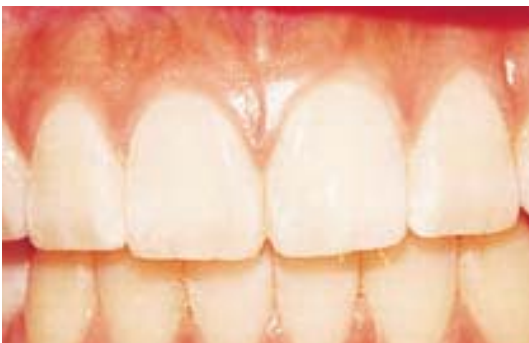

Figure 2a. Pre-treatment - Intrinsic stained dentition.

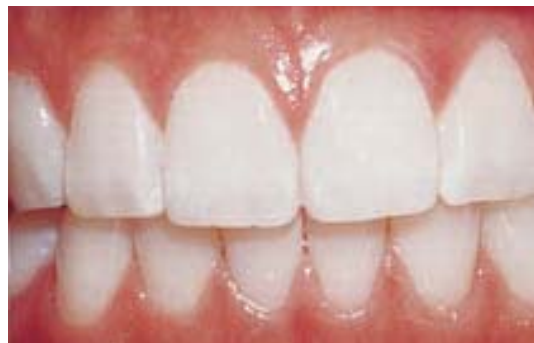

Figure 2b. Post-treatment-Home bleach treatment.



Figure 3. Indirect porcelain veneers completed to create harmonious proportion of dentition to the face. When optimal proportions are obtained, a dynamic facial appearance is created.

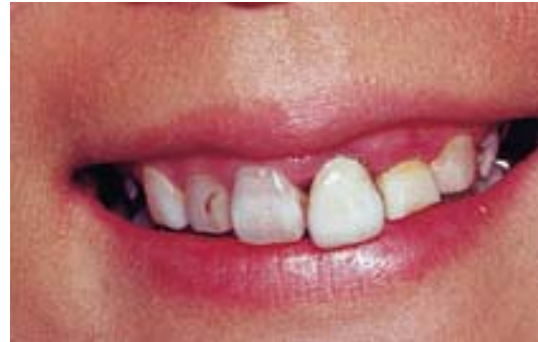

Figure 4a. Pre-treatment- Multiple esthetic related problems. Patient is not a bleach candidate.

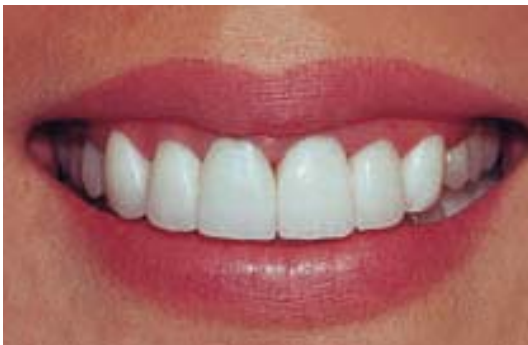

Figure 4b. Post-treatment-Cosmetic and reconstructive rehabilitation.



Figure 4c. Post-treatment - Due to correct approach to cosmetic rehabilitation, patient has regained their self-esteem and self-confidence.

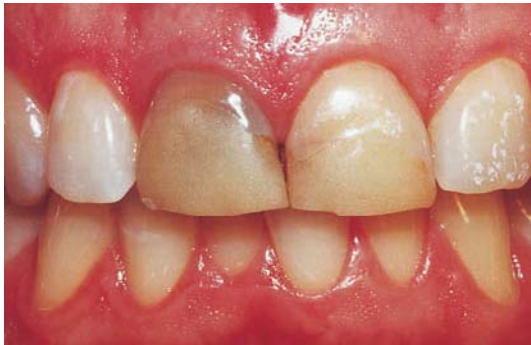

Figure 5a. Pretreatment- Proper diagnosis determines that central incisors are not good candidate for bleaching.

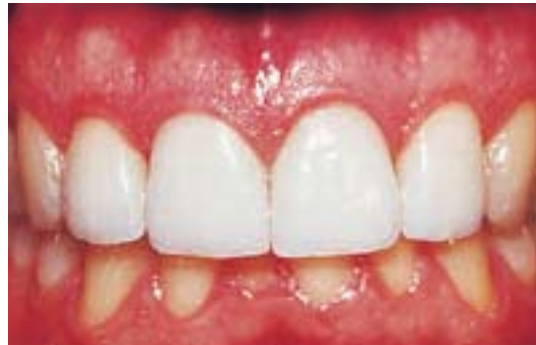

Figure 5b. Post-treatment - Incisors brightened by properly restoring with porcelain veneers.

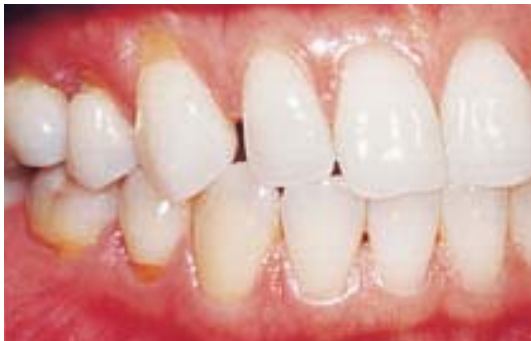

Figure 6a. Pre-treatment - Existing abfraction and diastema problems in the intrinsic stained dentition.

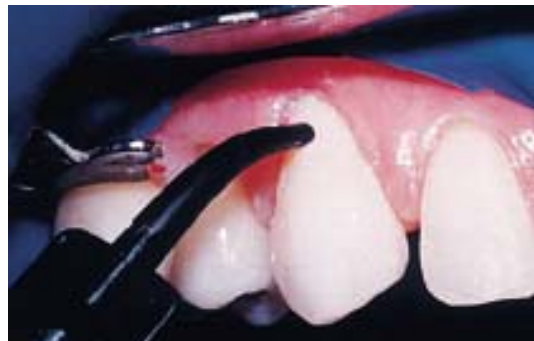

Figure 6b. Flowable composite resin(Permaflo by Ultradent Corp.) used to restore abfraction.

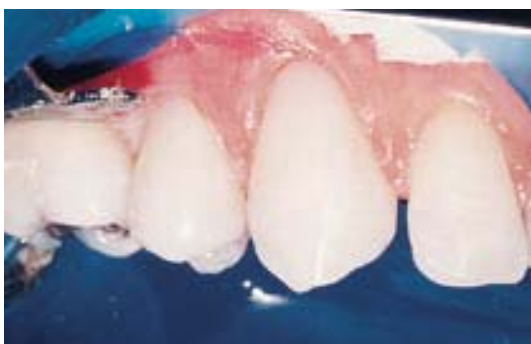

Figure 6c. Abfraction problems along cuspid and premolar is corrected with composite resin.

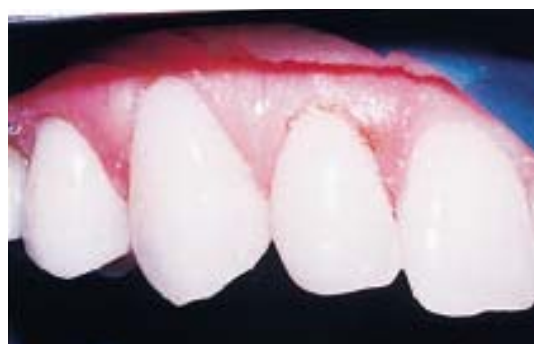

Figure 6d. Diastema is closed using conservative composite resin technique.



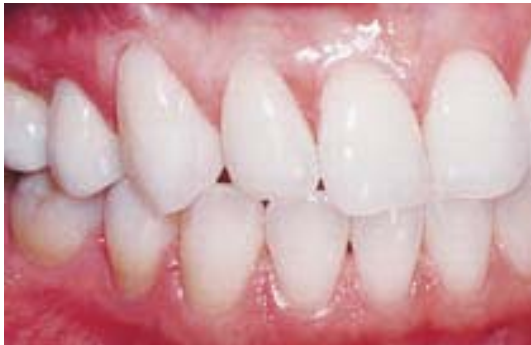

Figure 6e. Post-treatment - Following the home bleach treatment, abfraction and diastema problem is conservatively treated with composite resin.

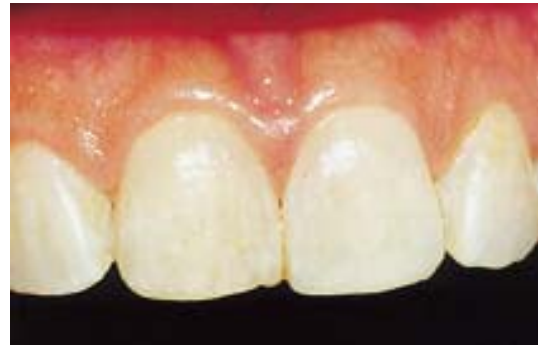

Figure 7a. Pre-treatment - Intrinsic stained dentition, with unesthetic asymmetrical central incisors.

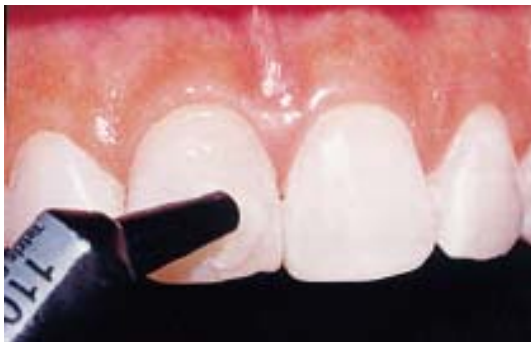

Figure 7b. Placement of microhybrid composite resin(Tetric-Ceram by Ivoclar - Vivadent) after home bleach treatment increased brightness (value) of dentition.

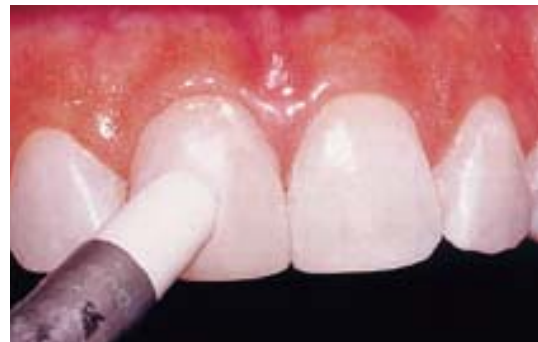

Figure 7c. Composite resin is sculpted using a silicone brush.

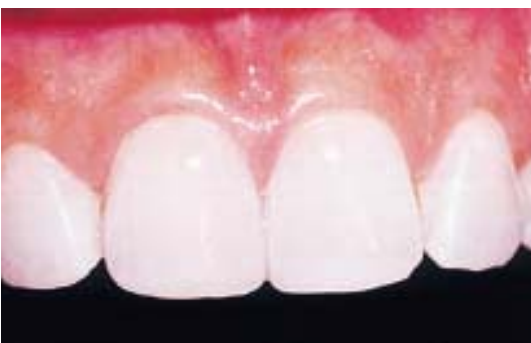

Figure 7d. Esthetic enhancement with conservative treatment using home bleaching and new microhybrid composite resin.

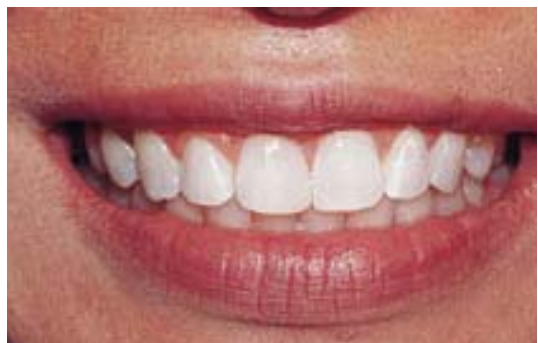

Figure 7e. Smile is enhanced using conservative cosmetic treatment.

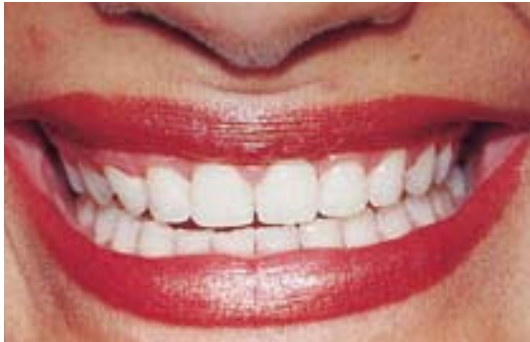

Figure 8a. Although teeth are in good alignment, the perioesthetic line is not symmetrical and an open bite exists from the upper right second premolar to the left second premolar.



Figure 8b. A facial analysis determined that the existing teeth were proportionately too small for the patient's face.

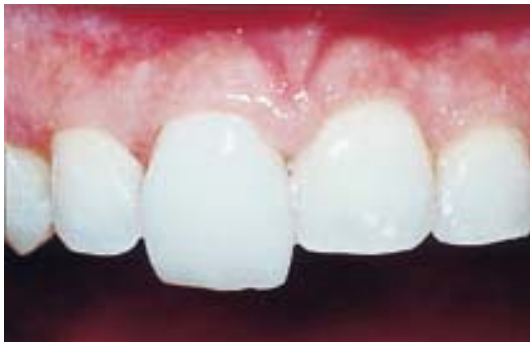

Figure 8c. To increase the morphology of the teeth, direct composite resin veneers were hand-sculpted individually to full polish.

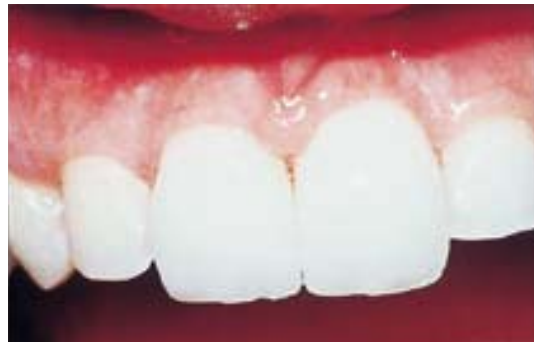

Figure 8d. After the first composite resin veneer was completed, the next direct composite resin veneer was sculpted on the upper left central incisor to perfectly match the first.

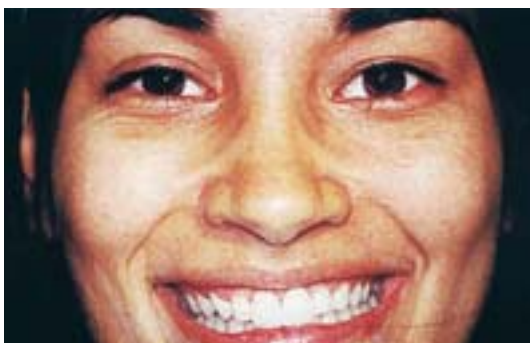

Figure 8e. After sculpting the two central incisors, it was confirmed that the size of the direct composite resin veneers matched the face proportionately.

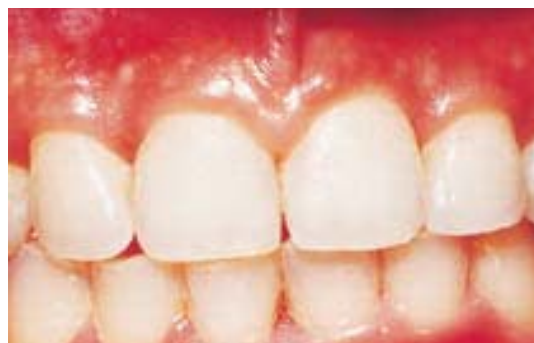

Figure 8f. Pre-treatment - Existing teeth are proportionately too small for the patient's face.

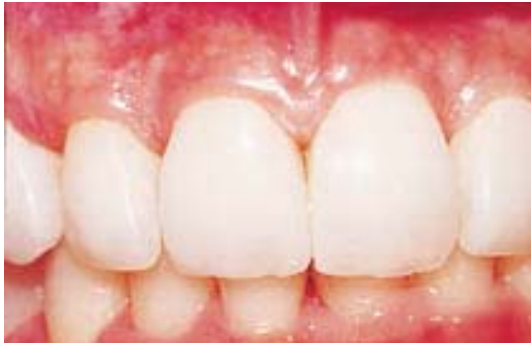

Figure 8g. Post-treatment - Direct composite resin veneers were hand-sculpted to create a beautiful end result.

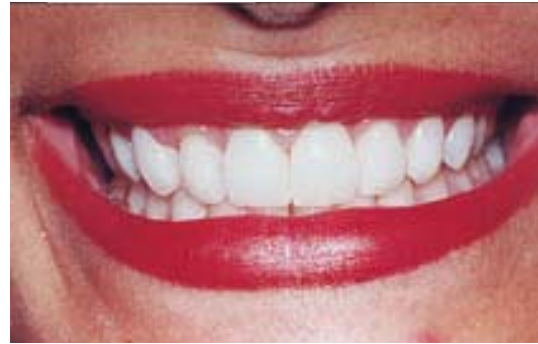

Figure 8h. In one appointment, direct composite resin veneers were bonded from the upper right second premolar to the left second premolar to create a proportionately more dynamic smile.




Figure 8i. With state-of-the art cosmetic dental procedures, dentists are able to help people become famous.



Figure 9. Using conservative procedures, such as teeth bleaching and direct composite resin veneers, the dentist can create beautiful esthetic results and be considered an artist.



## REFERENCES

1. American Academy of Cosmetic Dentistry, 1997 Consumer Survey.
2. Goldstein, RE, Garber, DA. Complete Dental Bleaching. Chicago. Quintessence Publishing Co, Inc.; 1984.
3. Goldstein, RE. Esthetics in Dentistry. Vol. 1, Second edition, Philadelphia. Decker; 1998. pp. 277 - 338.
4. Jordan, RE, Boksman, L. Conservative vital bleaching treatments of discolored dentition. Compend Contin Educ Dent; 1984. 5: pp. 803 - 808.
5. Giunta JL, Tsamtsouris A, stains and discolorations of teeth: review and case reports. J Pedod 1978; Winter:175-182.
6. Cheek CC, Heymann HO. Dental and Oral Discoloration Associated with Minocycline and Other Tetracycline Analogs. J Esthet Dent 1999;11(1):43-48.
7. Mopper, WK. The subtleties of anterior dentin bonded Class III restorations. Pract Periodont Aesthet Dent. 2 (6): pp. 17 - 20.
8. Barghi, N, Godwin, JM. Reducing the adverse effect of bleaching on composite enamel bond. J Esthet Dent. 1994; 6 (4): pp. 157 - 61.
9. Fahl N, Denehy GE, Jackson RD. Protocol for Predictable Restoration of Anterior Teeth with Composite Resins. Pract Periodont Aesthet Dent 1995;7(8):13-21.
10. Terry D. Direct Reconstruction of the Maxillary Anterior Dentition with Composite Resin: A Case Report. Pract Periodont Aesthet Dent 1999;11(3):361-367.

## 최신정보

### 레진 결합되고 유리섬유로 강화된 Composite fixed 국소의치: 임상적 연구

- Pekka K, Vallittu, DDS, PhD, CDT, and Camilla Sevelius, DDS

· **문제점:** 오랜동안 레진 결합되고 유리섬유로 보강된 composite fixed 국소의치(FDPs)가 개발되어 왔다. 이 보철물이 임상적으로 유용한지에 대한 data가 없다.

· **목적:** 예비 연구에서 31개의 FDPs의 임상적 기능을 평가하였다.

· **재료 및 방법:** 31명의 환자에서 하나 내지 세 개의 상실된 상,하악 치아를 회복하는데 보철물을 제작하였다. 보철물들은 연속적인 unidirectional E-유리섬유 multiphase polymer matrix와 광중합 콤포짓 레진 veneer의 framework로 구성되었다. 보철물들을 24개월 까지 6개월 단위로 검사하였다(평균 검사 기간은 14개월). 보철물의 부분적인 혹은 전체적인 debonding이나 framework 파절을 치료 실패로 간주하였다.

· **결과:** 두 개의 보철물에서 debonding이 일어났는데 하나는 부적절한 교합 조절이 원인이고 다른 하나는 원인을 모른다. 24개월 때의 Kaplan-Meier 유지가능성은 93%였다. Framework 파절은 없었다.

· **결론:** 이 예비 실험의 결과로 유리섬유로 강화된 FDPs가 주조금속 framework를 가진 FDPs를 대신할 수 있을 가능성을 보여 준다.