

I.

76.6% 95.5%
. 1985 Miller^{7,29)}
citric acid 5

2mm

87 - 100%

2

가

가

가

1 - 11),

12 - 16),

17 - 21),

가

25 - 26)

1956

Grupe Warren¹²⁾

, 1968

1974 Edel³⁰⁾

Cohen Ross ²⁷⁾

double papillae

가

repositioned flap

. 1985 Langer and Langer¹⁸⁾가

가

가

56

4

2 - 6mm

28).

1983 Holbrook Oschsenbein³⁾ one -
step free gingival graft

. 1986 Nelson¹⁹⁾

가

88%

Nelson 1992 Harris²⁰⁾ plain gut
 가 tetracycline HCl
 3
 가 (2) Trap door approach 가
 가 1.5 - 2.0mm window
 가 가
 가
 II.
 1. 3 - 5mm 가
 16 thin gut
 20 dry
 . Probing depth, foil 가
 foil Dry foil 가
 2. 가
 (1) 2 0.12% chlorhexi-
 dine gluconate 가
 7 - 10
 가
 Divergent 2 0.12% chlorhexidine gluconate
 3
 5mm 가

Table 1. The change of Pocket depth(mm)

	Pre - Op	Post - Op		Pre - Op	Post - Op
1	1	1	11	1	1
2	1	1	12	1	1
3	2	1	13	2	2
4	2	1	14	2	1
5	1	1	15	1	1
6	2	2	16	1	1
7	1	1	17	2	1
8	1	2	18	1	1
9	2	1	19	1	1
10	1	1	20	2	1
			Average	1.40	1.15
			St. Deviaion	0.50	0.37

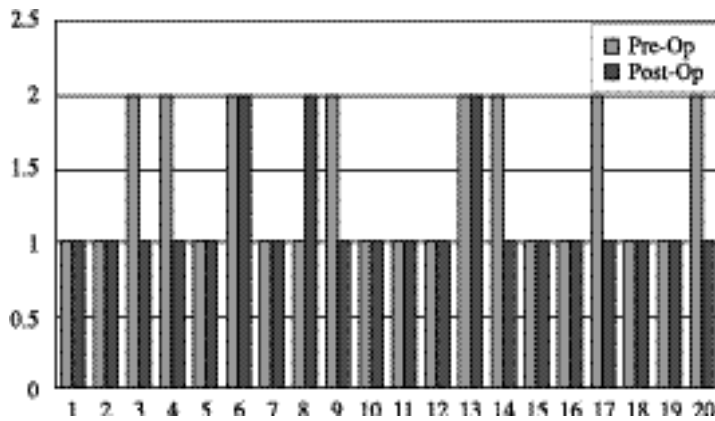


Figure 1. The change of Pocket depth(mm)

(3)

1.40 ± 0.50 ,

$1.15 \pm 0.37\text{mm}$ 가

($p >$

0.05)(Table 1, Figure 1).

2.

SPSS(v.8.0) for window

Wilcoxon's matched - pairs signed

1mm

rank test

$5.9 \pm 0.97\text{mm}$

가 ($p < 0.05$)(Table 2, Figure 2).

III.

3.

1.

72.2% 가

Table 2. The amount of keratinized gingiva(mm)

	Pre - Op	Post - Op		Pre - Op	Post - Op
1	<1	5	11	<1	5
2	<1	8	12	<1	6
3	<1	7	13	<1	5
4	<1	6	14	<1	4
5	<1	6	15	<1	6
6	<1	7	16	<1	7
7	<1	6	17	<1	6
8	<1	6	18	<1	5
9	<1	5	19	<1	5
10	<1	7	20	<1	6
Average				5.90	
St. Deviaion				0.97	

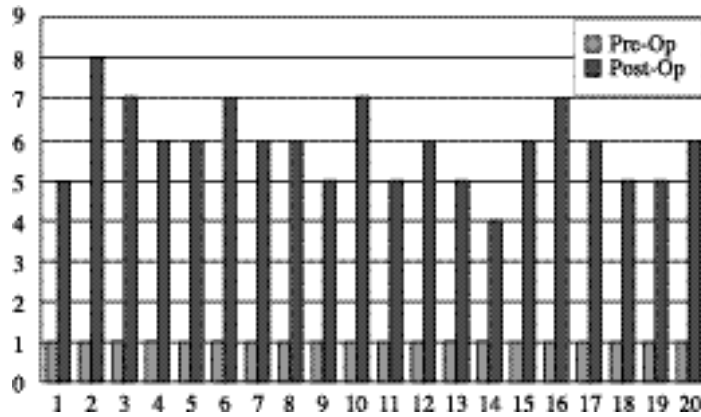


Figure 2. The amount of keratinized gingiva(mm)

Table 3. The amount of clinical recession(mm)

	CEJ - GM Pre - Op	CEJ - GM Pre - Op		CEJ - GM Pre - Op	CEJ - GM Pre - Op
1	4	1	11	4	1
2	4	1	12	4	1
3	5	2	13	3	1
4	8	4	14	7	2
5	5	0	15	5	2
6	8	2	16	8	4
7	3	0	17	6	2
8	3	0	18	5	2
9	6	1	19	4	1
10	4	0	20	5	1
Average				5.05	
St. Deviaion				1.64	
				1.40	
				1.14	

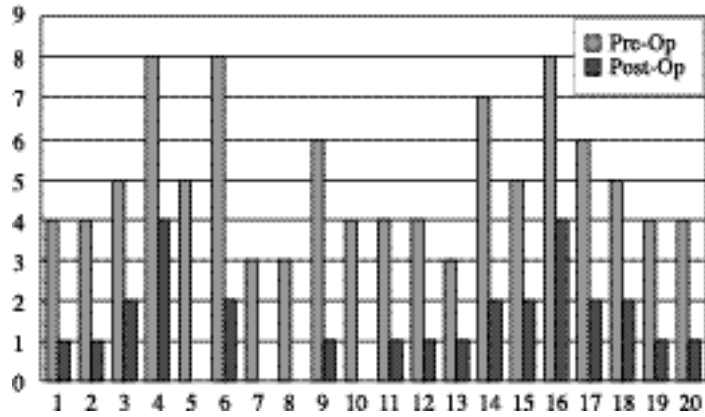


Figure 3. The amount of clinical recession(mm)

Table 4. The shrinkage of CT from original position(mm)

	Original ht. CT graft	Rerraining Keratinized Tissue	Shrinkage		Original ht. CT graft	Rerraining Keratinized Tissue	Shrinkage
1	12	5	7	11	12	5	7
2	12	8	4	12	12	8	4
3	11	7	4	12	11	7	4
4	10	6	4	14	10	6	4
5	9	6	3	15	9	6	3
6	10	7	3	16	10	7	3
7	8	6	2	17	8	6	2
8	9	6	3	18	9	6	3
9	11	5	6	19	11	5	6
10	10	7	3	20	10	7	3
				Average	10.25	6.05	4.20
				St. Deviaion	1.19	0.89	1.15

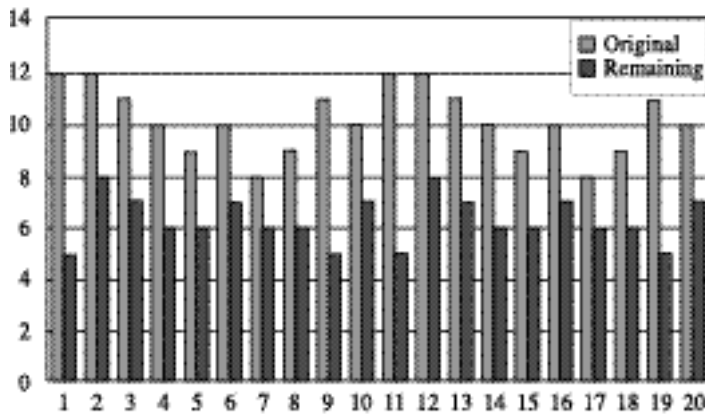


Figure 4. The shrinkage of CT from original position(mm)

Table 5. The change of vestibular depth(mm)

	Pre - Op		Post - Op		Pre - Op		Post - Op	
1	6	12	11	8	11			
2	9	12	12	6	12			
3	9	11	13	6	10			
4	10	14	14	5	9			
5	6	9	15	5	8			
6	9	14	16	5	9			
7	6	8	17	7	12			
8	6	9	18	7	13			
9	6	11	19	6	11			
10	7	10	20	5	9			
	Average			6.70	10.70			
	St. Deviaion			1.53	1.84			

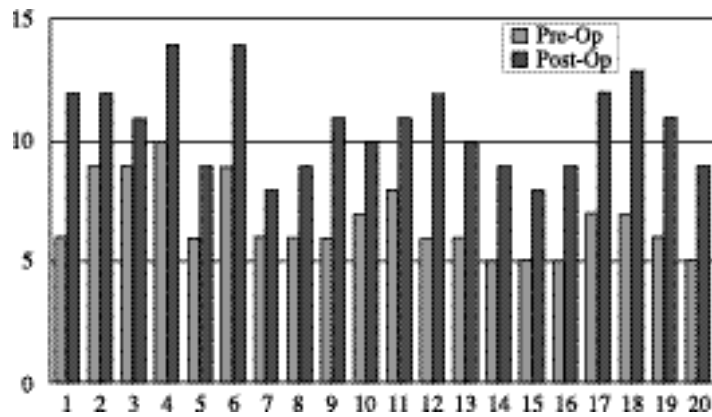


Figure 5. The change of vestibular depth(mm)

(p< 0.05).

IV.

4.

가

Sullivan

shrinkage 4.2 ± 1.15mm

Atkins^{1,32)} 4가

40.1%

(p<0.05).

Miller³³⁾ Sullivan

Atkins

가

5.

가

가

6.7 ± 1.52mm

가

Class

10.7 ± 1.84mm

가

(p<0.05).

가

Class , 가

Class , 가

Class 가

Class 5.90mm

Class Class 4.0mm 가 ,

Class Class 72.2% Raetzke²²⁾ (80%),

Class Nelson¹⁹⁾ (88%)

class , 가 Miller

standing connective tissue graft Free 가 , 가

가 16 , 20 V.

6

Edel 가

. Langer Langer ,

Nelson¹⁹⁾ free standing

Raetzke²²⁾ connective tissue graft

envelope . Janke³⁵⁾ 1. 가

(p > 0.05).

2. 1mm

가 5.9 ± 0.97mm

. Allen²⁴⁾ suprapariosteal envelope 가 (p < 0.05).

technique 3. 72.2% 가 (p < 0.05).

4. 1.15mm 40.1% 4.2 ±
(p<0.05).
5. 1.52mm 10.7 ± 1.84mm 6.7 ±
(p<0.05). 가

VI.

1. Sullivan HC, Atkins JH. : Free autogenous gingival grafts. III. Utilization of grafts in the treatment of gingival recession. *Periodontics* 1968 6:152 - 159
2. Miller PD. : Root coverage using a free soft tissue autograft following citric acid application. part I. Technique *Int J Periodont Rest Dent* 1982 2(2):65 - 70
3. Holbrook T, Ochsenbein C. : Complete coverage of the denuded root surface with a one stage gingival graft. *Int J Periodont Rest Dent* 1985 5(2):15 - 37
4. Corn H, Marks MH. : Gingival grafting for deep - wide recession - A status report . Part I. Rationale, case selection & root preparation. *Compend Contin Educ Dent* 1983 4:53 - 69
5. Corn H, Marks MH. : Gingival grafting for deep - wide recession - A status report . Part II. Surgical problems. *Compend Contin Educ Dent* 1983 4:167 - 182
6. Miller PD. : Root coverage using a free soft tissue autograft following citric acid application. part II. Treatment of the carious root. *Int J Periodont Rest Dent* 1983 3(5):39
7. Miller PD. : Root coverage using a free soft tissue autograft following citric acid application. part III : A successful and predictable procedure in areas of deep - wide recession. *Int J Periodont Rest Dent* 1985 5(2):14 - 37
8. Borghetti A, Gardella J. : Thick gingial autograft for the coverage of gingival recession : A Clinical evaluation. *Int J Periodont Rest Dent* 1990 10:217 - 229
9. Tolmie PN, Rubins RP, Buck GS, Vagianos V. & Lanz JC. : The pre - dictability of root coverage by way of free gingival autograft and citric acid application: An evaluation by multiple clinicians. *Int J Periodont Rest Dent* 1991 11:261 - 277
10. Paul L, Michaelides, Suzan G, Wilson. : An autogenous gingival graft technique. *Int J Periodont Rest Dent* 1994 14:113 - 125
11. Kirk L, Pasquinelli. : The histology of New attachment utilizing a thick auto - genous soft tissue graft in an area of deep recession. A case report. *Int J Periodont Rest Dent* 1995 15(3):249 - 257
12. Grupe H, Warren R. : Repair of gingival defects by a sliding flap operation. *J periodontol* 1956 27:92 - 99
13. Guinard EA, Caffesse RG. : Treatment of localized gingival recessions. III. Comparison of results obtained

- with lateral sliding and coronal repositioned flaps. *J periodontol* 1978 49:351 - 356
14. Shiloach J. : The clinical effects of citric acid and laterally positioned pedicle grafts in the treatment of denuded root surface. A pilot study. *J Periodontol* 1980 51:652 - 654
 15. Tarnow DP. : Semilunar coronally repositioned flap. *J Clin Periodontol* 1986 3:182 - 185
 16. Harris RJ, Harris AW. : The coronally positioned pedicle graft with inlaid margins. : A predictable method of obtaining root coverage of shallow defects. *Int J Periodont Rest Dent* 1994 25:229 - 241
 17. Langer B, Calagna LJ. : The subepithelial connective tissue graft. A new approach to the enhancement of anterior cosmetics. *Int J Periodont Rest Dent* 1982 2:22 - 34
 18. Langer B, Langer L. : Subepithelial connective tissue graft technique for root coverage. *J Periodontol* 1985 56:715 - 720
 19. Nelson SW. The subpedicle connective tissue graft : A bilaminar reconstructive procedure for the coverage of denuded root surfaces. *J Periodontol* 1987 58:95 - 102
 20. Harris RJ. : The connective tissue and partial - thickness double pedicle graft: A predictable method of obtaining root coverage. *J Periodontol* 1992 63:477 - 486
 21. Jahnke PV, Sandifer JB, Gher ME, Gray JL, Richardson CA. Thick free gingival and connective tissue autografts for root coverage. *J Periodontol* 1993 64:315 - 322
 22. Raetzke PB. Covering localized areas of root exposure employing the envelope technique. *J Periodontol* 1985 56:397 - 402
 23. Allen AL. : Use of the supraperiosteal

- riostel envelope in soft tissue grafting for root coverage. I. Rationale and technique. *Int J Periodont Rest Dent* 1994 14:217 - 227
24. Allen AL. : Use of the supraperiosteal envelope in soft tissue grafting for root coverage II. Clinical result. *Int J Periodont Rest Dent* 1994 14:303 - 315
 25. Tinti C, Vincenzi G, Cortellini P, Pini Prato GP, Clauser C.: Guided tissue regeneration in the treatment of human facial recession. A 12 case report. *J Periodontol* 1992 63:554 - 560
 26. Trombelli L, Schincaglia G, Scapoli C, Calura G.: Healing response of human buccal gingival recessions treated with expanded polytetrafluoroethylene membranes: A retrospective report. *J Periodontol* 1995 66:14 - 22
 27. Cohen D.W.and Ross S.E.:The double papilla positioned flap in periodontal therapy. *J. periodontol.* 1968 39:65
 28. Corn H.:Edentulous area pedicle grafts in mucogingival surgery. *Periodontics.* 1964 2:229 - 242
 29. Miller,P.D:Root coverage using a free soft tissue autograft following citric acid application. Part . Technique. *Int. Periodont. Rest. Dent.* 1982 2(2):65 - 70
 30. Edel A.:Clinical evaluation of connective tissue grafts used to increase the width of keratinized gingiva. *J. Clin. Periodontol.* 1974 1:185 - 196
 31. Han T.J., Takri H. and Carranza F.A.Jr.:The strip gingival autograft technique. *Int. J. Periodontics Restorative Dent.* 1993 13(2):180 - 187
 32. Sullivan H. and Atkins J.:Free autogenous gingival grafts. Principles of successful grafting. *Periodontics* 1968 6:121 - 129
 33. Miller,P.D:A classification of marginal tissue recession. *Inter. J. Periodontics Restorative Dent.* 1985 2:9 - 13
 34. Han T.J., Honigman A.S.:Root coverage using free standing connective tissue grafts. Accepted for Publication.
 35. Jahnke PV, Sandifer JB, Gher ME, Gray JL, Richardson CA : Thick free gingival and connective tissue autografts for root coverage. *J Periodontol* 1993 64:315 - 322

- Abstracts -

The Clinical Study on the Root Coverage Effects with Free Standing Connective tissue Graft

Cheol Park, Sung - Bin Lim, Chin - Hyung Chung

Department of Periodontology, College of Dentistry, Dankook University

A mucogingival grafting procedure has been developed to cover denuded root surface. The subepithelial connective tissue graft technique is very predictable and allows for a good esthetic results and minimum patient discomfort on the palate.

However, in areas where there is a lack of vestibular depth and keratinized attached tissue, the presence of frena or heavy muscle attachment, covering the connective tissue graft with a mucosal flap is very difficult. The purpose of this study is to evaluate an alternative technique of root coverage using the free connective tissue graft.

The results were as follows:

1. Probing depths didn't seem to vary significantly from the preoperative to postoperative period.
2. The amount of keratinized tissue showed an increase of 5.9 ± 0.97 mm from the preoperative level.
3. Total clinical exposed root coverage

increase 72.2% compare with preoperative level.

4. The shrinkage from gingival margin is 4.2 ± 1.15 mm and the mean shrinkage rate is 40.1%.
5. The depth of the vestibule increased with the average distance from cementoamel junction to mucogingival junction being 7.4 ± 1.65 mm.