

# MR Imaging of Medullary Streaks in Osteosclerosis: A Case Report

Hak Soo Lee, MD<sup>1</sup>  
Kyung-Bin Joo, MD<sup>1</sup>  
Tae Soo Park, MD<sup>2</sup>  
Ho Taek Song, MD<sup>1</sup>  
Yong Soo Kim, MD<sup>1</sup>  
Dong Woo Park, MD<sup>1</sup>  
Choong Ki Park, MD<sup>1</sup>

We present a case of medullary sclerosis of the appendicular skeleton in a patient with chronic renal insufficiency for whom MR imaging findings were characteristic. T1- and T2-weighted MR images showed multiple vertical lines (medullary streaks) of low signal intensity in the metaphyses and diaphyses of the distal femur and proximal tibia.

**I**n renal osteodystrophy, musculoskeletal manifestations associated with chronic renal insufficiency are common and may be related to the stage of the disease or its treatment. They encompass a range of conditions which includes secondary hyperparathyroidism, osteosclerosis, osteoporosis, osteomalacia, soft-tissue and vascular calcification, amyloid deposition, tendon rupture, infection, and avascular necrosis (1, 2). While the various characteristic imaging features seen in chronic renal insufficiency have been reported, only a few studies (1–3) have described the bone marrow pattern revealed by MR imaging in renal osteodystrophy.

In this report, we describe the radiologic findings, including those of MR imaging, of medullary sclerosis of the appendicular skeleton in a patient with chronic renal insufficiency after hemodialysis.

## CASE REPORT

A 34-year-old man who for nine years had been undergoing hemodialysis for chronic renal insufficiency, and 20 days earlier had fallen over, visited our hospital complaining of pain in both knees. Physical examination revealed mild tenderness in the suprapatellar area, the popliteal fossa of the left knee and the infrapatellar area of the right, and in both knee joints movement was limited. Laboratory data included a serum calcium level of 9.0 (normal range, 8.2–10.7) mg/dL, phosphorous of 5.8 (normal range, 2.5–4.5) mg/dL, and alkaline phosphatase of 550 (normal range, 30–110 IU/L. Serum protein was 5.9 (normal range, 6.4–8.5) g/dL, and serum BUN and creatinine were 86 (normal range, 7–20) and 14.2 (normal range, 0.7–1.4) mg/dL, respectively. Intact parathyroid hormone (PTH) was 1941 (normal range, 10–65) pg/mL, serum 1,25-dihydroxyvitamin D was 4.1 (normal range, 20–60) pg/mL, and serum aluminum was 35.8 (normal range, < 60) ug/L.

Plain radiographs of both knee joints showed arterial calcification of pipe-stem appearance in both lower legs, and fine calcifications in the suprapatellar area of the left knee (Fig. 1A) and the infrapatellar area of the right. The bony density of the distal femur and proximal tibia was slightly increased. US revealed focal thickening, decreased echogenicity with obliteration of the normal fibrillar pattern, and scattered calcifica-

### Index words:

Bones, primary metabolic abnormalities  
Bone marrow, MR  
Bones, sclerosis

### *Korean J Radiol* 2000; 1: 172-174

Received March 10, 2000; accepted after revision June 27, 2000.

Departments of <sup>1</sup>Radiology, and <sup>2</sup>Orthopedic Surgery, College of Medicine, Hanyang University

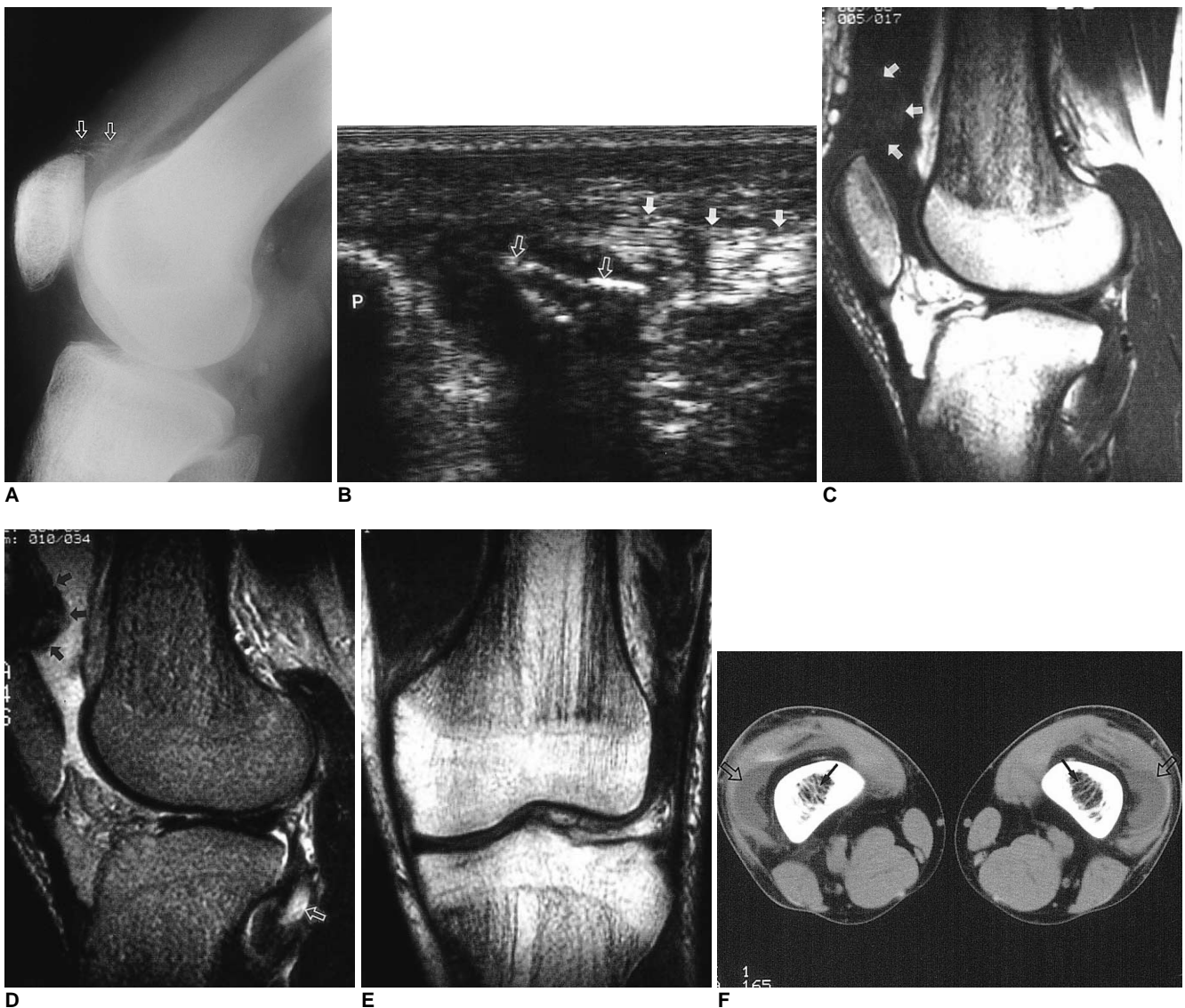
### Address reprint requests to:

Kyung-Bin Joo, M.D., Department of Radiology, Hanyang University Hospital, 17, Haengdang-Dong, Seungdong-Ku, Seoul 133-792, Korea.  
Telephone: (822) 2290-9164  
Fax: (822) 293-2111  
e-mail: hslee@medikorea.net

## MR Imaging of Medullary Streaks in Osteosclerosis

tions with posterior shadowing at the distal insertion site of the left quadriceps tendon and the proximal insertion site of the right patellar. In the right knee, there was also complete discontinuity of this tendon (Fig. 1B). Sagittal T1-weighted MR imaging (TR/TE = 600 ms/35 ms) of the left knee demonstrated obliteration of the normal laminated appearance and focal thickening, with inhomogeneously increased signal intensity from the insertion site of the

quadriceps tendon to the base of the patella (Fig. 1C). Sagittal T2-weighted MR imaging (TR/TE = 2500 ms/80 ms) revealed slightly increased signal intensity in the thickened area, and T2-weighted MRI also showed an area of abnormal increased signal intensity within the popliteus muscle of the left knee (Fig. 1D). Sagittal and coronal T1- and T2-weighted MRI also demonstrated multiple vertical lines (medullary streaks) of low signal intensity in the



**Fig. 1.** A 34-year-old man with chronic renal insufficiency and pain in both knees.

**A.** Lateral radiograph of the left knee shows fine calcific opacities (open arrows) at the superior aspect of the patella.

**B.** Longitudinal US of the right knee reveals discontinuity of the normal fibrillar patterns (arrows) and arc-like calcifications (open arrows), with posterior shadowing at the proximal insertion site of the patellar tendon. P= patella

**C.** T1-weighted sagittal MR image of the left knee shows focal thickening with inhomogeneous increased signal intensity (arrows) at the insertion site of the quadriceps tendon.

**D.** T2-weighted sagittal MR image of the left knee shows a slight increase in signal intensity at the insertion site of the quadriceps tendon (arrows) and abnormal increased signal intensity within the popliteus muscle (open arrow).

**E.** T1-weighted coronal MR image shows medullary streaks of low signal in the metaphyses and diaphyses of the distal femur and proximal tibia. The epiphysis of the femur and tibia were relatively spared.

**F.** Unenhanced CT scan shows irregularly thickened trabeculae (arrows) in the bone marrow of the distal femora. Also note the presence of joint effusion (open arrows) in the suprapatellar bursae of both knees.

metaphyses and diaphyses of the distal femur and proximal tibia. The lines were rough and irregular (Fig. 1E).

For further evaluation of the nature or cause of the vertical lines seen on MR images, CT scans of both femora were obtained. Unenhanced scans showed coarse and thickened trabeculae in the metaphyses of both distal femora, with a moderate amount of joint effusion in the suprapatellar bursae (Fig. 1F). We believe that the vertical lines of bone marrow of the femur and tibia revealed by MR imaging were related to the thickened trabeculae seen on CT scans.

## DISCUSSION

In patients with chronic renal insufficiency, abnormalities involving the musculoskeletal system are numerous and frequent (1, 2). Osteosclerosis is a well known feature of renal osteodystrophy, occurring in 9–34% of patients (1), and although the cause is not clearly understood, PTH has been implicated because of its stimulation of osteoblastic activity (1). In patients with osteosclerosis, iliac crest biopsy reveals trabecular thickening and significant fibrosis (4). Osteosclerosis has a strong predilection for the axial skeleton, where cancellous, rather than cortical, bone is predominant. The areas of the axial skeleton that demonstrate osteosclerosis include the vertebral bodies (rugger jersey spine), pelvis, ribs, and clavicle, and the appendicular skeleton, particularly the metaphyseal regions of long bones, may also be involved (1, 4). As in our case, the epiphysis of the distal femur and proximal tibia are usually spared. Calcification can be seen in the ocular tissues, arteries, subcutaneous and periarticular soft tissues, and viscera. The factors causing soft and vascular calcification include hypercalcemia, local tissue damage, alkalosis, and increased calcium-phosphorous product in the extracellular fluid. As in our case, arterial calcification occurs in medium and intimal elastic tissues, giving a pipe-stem appearance without prominent luminal involvement (1). In cases involving chronic renal insufficiency, spontaneous rupture and avulsion of a tendon can occur. The factors causing tears in a tendon are PTH excess, tendon calcification, and chronic acidosis with connective elastosis. These changes result in diminished tendon tensile strength and accelerated degeneration (1). In our case, the rupture of the popliteus tendon might have been caused by recent trauma rather

than chronic renal insufficiency.

In patients with chronic renal insufficiency including osteosclerosis, brown tumors, skeletal deformity, fatty marrow inversion, osteonecrosis, transient bone marrow edema and occult stress fracture, MRI is helpful in the evaluation of bone marrow abnormalities (2, 3). Ito et al. (5) reported that in chronic renal failure, T1 relaxation time was related to the cellular histologic findings of the vertebrae. The prolonged T1 relaxation time of the vertebrae observed in cases involving osteosclerosis was due to hypercellularity, the presence of thickened or many small irregular trabeculae, or peritrabecular fibrosis. Olmastroni et al. (3) reported that the thickened irregular trabeculae in the proximal femoral metaphyses were observed in three of 14 patients with renal osteodystrophy who underwent MR. Trabecular bone thickening was clearly demonstrated by MR as very low signal intensity cortical sleeves or medullary streaks.

In summary, the vertical lines of low signal intensity revealed by MRI in the metaphyses and diaphyses of the proximal tibia and distal femur appeared to correspond to the trabecular thickening that may be caused mainly by secondary hyperparathyroidism. We have described the MR imaging findings of medullary osteosclerosis of the long bone as medullary streaks, and in renal osteodystrophy, other radiologic findings include spontaneous tendon rupture.

## References

1. Murphey MD, Sartoris DJ, Quale JL, Pathria MN, Martin NL. Musculoskeletal manifestations of chronic renal insufficiency. *RadioGraphics* 1993;13:357-379
2. Tigges S, Nance EP, Carpenter WA, Erb R. Renal osteodystrophy: imaging findings that mimic those of other diseases. *AJR* 1995;165:143-148
3. Olmastroni M, Seracini D, Lavoratti G, Marin E, Masi A, Vichi G. Magnetic resonance imaging of renal osteodystrophy in children. *Pediatr Radiol* 1997;27:865-868
4. Resnick D, Niwayama G. *Parathyroid disorders and renal osteodystrophy*. In Resnick D, Niwayama G, eds. *Diagnosis of bone and joint disorders*. 2nd ed. Philadelphia: Saunders, 1988: 2219-2285
5. Ito M, Ito M, Hayashi K, Noguchi M, Kitamori H. Evaluation of spinal bone changes in patients with chronic renal failure by CT and MR imaging with pathologic correlation. *Acta Radiol* 1994; 35:291-295