

## Metastatic Cervical Lymphadenopathy from Uterine Leiomyosarcoma with Good Local Response to Radiotherapy and Chemotherapy

Yoon Kyeong Oh, M.D. \*, Hee Chul Park, M.D. \*, Keun Hong Kee, M.D. †  
Ho Jong Jeon, M.D. †, You Hwan Park, M.D. † and Choon Hai Chung, M.D. †

\*Department of Therapeutic Radiology, †Pathology, and †Internal Medicine,  
Chosun University Medical School, Kwangju, Korea

The metastasis of uterine leiomyosarcoma to the neck node has not been reported previously and the radiotherapy has been rarely used for the metastatic lesion of the other sites. We report a case of neck metastasis from a uterine leiomyosarcoma, which developed 10 months after surgery and postoperative pelvic radiotherapy. It also involved the parapharyngeal space, adjacent spine, and spinal canal. The metastatic neck mass was inoperable, and was treated by neck radiotherapy (6,000 cGy) and chemotherapy including taxol and carboplatin. The mass has regressed progressively to a nearly impalpable state. She has never developed spinal cord compression syndrome, and has maintained good swallowing for eight months since the neck radiotherapy and chemotherapy. Since the extensive metastatic neck mass showed good local response to high dose radiotherapy and chemotherapy, both treatments may be considered for an unresectable metastatic leiomyosarcoma.

**Key Words** : Uterine leiomyosarcoma, Neck metastasis, Radiotherapy, Chemotherapy

Uterine leiomyosarcomas are rare female neoplasms that account for about 1% of all uterine malignancies and approximately 25% of uterine sarcomas.<sup>1)</sup> Patients with early-stage disease who undergo locoregional treatment experience a high recurrence rate. Most of the treatment failures are extrapelvic and are often the first sign of recurrent disease.<sup>2)</sup>

There is only limited information in the literature about the incidence of metastases to distant sites. Metastases to the lungs occur more commonly than other sites. The metastasis to the brain, skull, spine, tongue, or parotid gland has been reported separately as a case.<sup>3)</sup> The metastatic cervical lymphadenopathy from the uterine leiomyosarcoma has not been reported previously. Whenever tumor recurrence or metastases develop, palliative surgery, radiotherapy, or chemotherapy may be attempted.

The literature about the radiotherapy for the inoperable

metastatic leiomyosarcoma is not available. We report the case of a patient with leiomyosarcoma of the uterus who developed metastases to the neck node involving the parapharyngeal space, adjacent spine, and spinal canal. The metastatic mass was inoperable. It was treated by radiotherapy and chemotherapy including taxol and carboplatin, and responded slowly and markedly.

### CASE REPORT

A 45-year-old, para 3, premenopausal woman underwent a simple total abdominal hysterectomy for a pelvic tumor, presumed to be a uterine myoma, on August 4, 1998. The postoperative histopathologic examination revealed leiomyosarcoma of the uterus (Fig. 1). The tumor was 11×11 cm in size and had extensive necrosis. The lesion was confined to the uterus without extension outside the uterus and staged as stage Ic. The resection margin was negative. She then received postoperative pelvic radiotherapy using a 6 MV linear accelerator, with a total dose of 5,040 cGy in 28 fractions. She didn't visit the hospital regularly afterwards.

On May 25, 1999, she complained of a 2-month history

This work was supported by research fund (1999-44) of Chosun University Hospital.

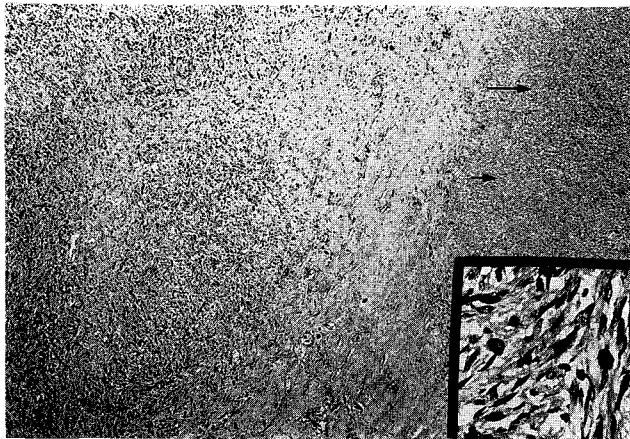
Submitted October 30, 2000 accepted December 13, 2000

Reprint requested to: Yoon Kyeong Oh, Department of Therapeutic Radiology, Chosun University Hospital

Tel : 062)220-3245, Fax : 062)227-7757

E-mail : ykoh@mail.chosun.ac.kr

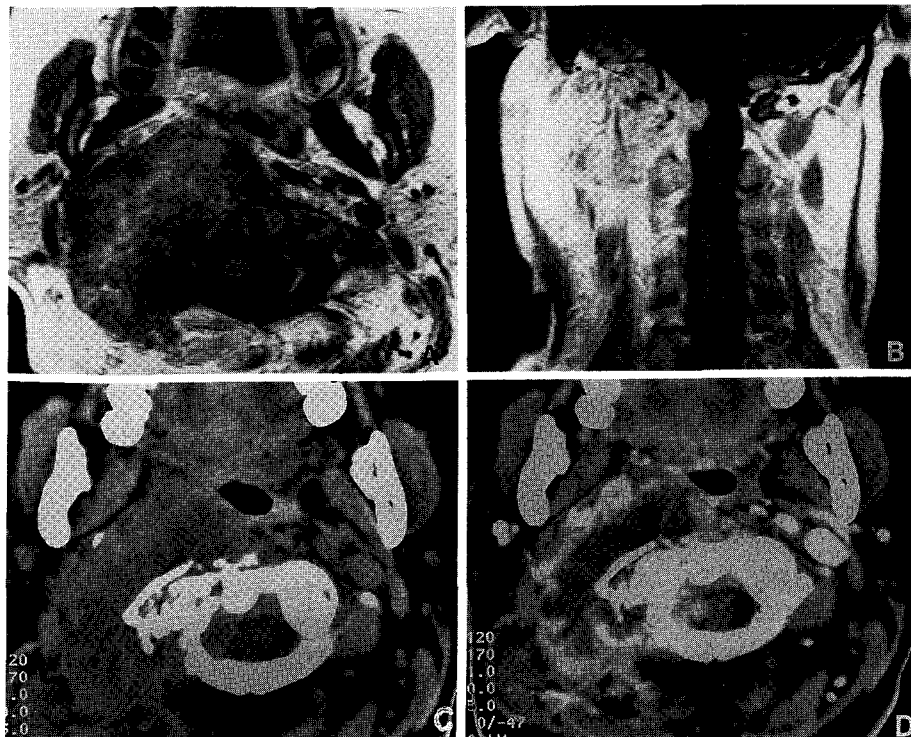
of limited neck motion with a right neck mass. The chest roentgenogram showed metastatic nodules in both lungs. Magnetic resonance imaging of the neck revealed huge right cervical lymphadenopathy, involving the parapharyngeal space



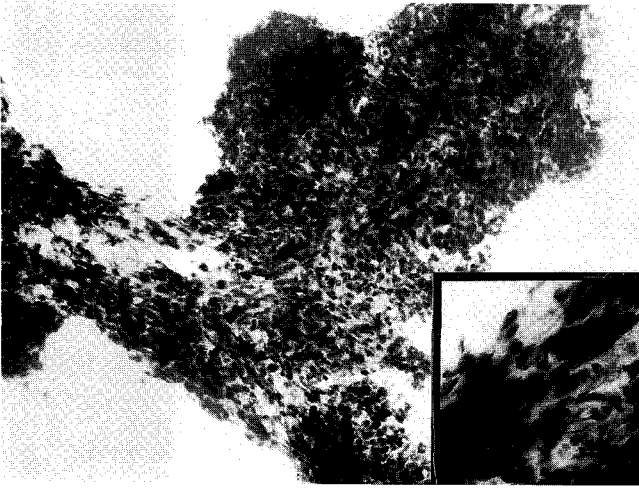
**Fig. 1.** The histopathologic finding of the uterine tumor. The tumor cells composed of spindle cells bearing hyperchromatic and pleomorphic nucleus. Massive necrosis (arrow) was noted (H-E,  $\times 40$ ). Inset: High power view of tumor cells. Many atypical mitoses were seen (H-E,  $\times 400$ ).

and adjacent spine and spinal canal (Fig. 2A, 2B). On physical examination, a diffuse, large, fixed, nontender  $10 \times 9$  cm mass was palpated; the oropharynx was nearly obstructed by the bulging mass, mainly on the right side. A fine-needle biopsy of the right neck mass was performed and the mass was confirmed as metastatic leiomyosarcoma (Fig. 3).

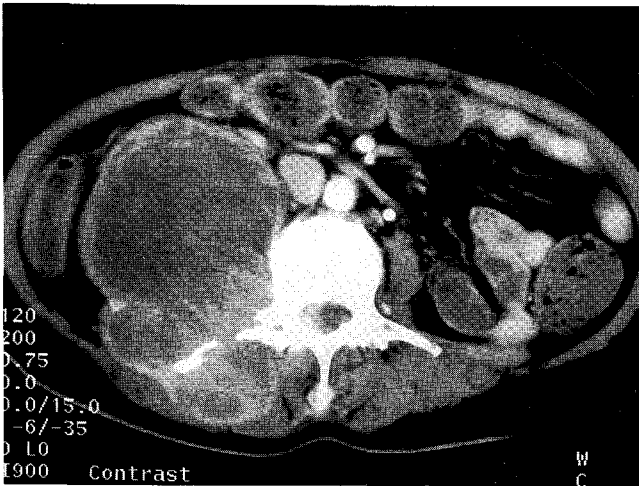
She received neck radiotherapy to limited fields, including the metastatic neck mass, between June 4 and July 15, 1999. The total radiation dose was 6,000 cGy in 30 fractions; the spinal cord was excluded from the field after 4,400 cGy. The medial part of the mass was treated with 4,400~5,000 cGy due to spinal cord tolerance. Follow-up computed tomography imaging shortly after the radiotherapy demonstrated necrosis of the mass (Fig. 2C, 2D). At that time, the mass began to regress and has since regressed progressively to a nearly impalpable state. The difficulty in swallowing also improved with regression of the parapharyngeal mass. She was treated with carboplatin  $320 \text{ mg/m}^2$  and taxol  $135 \text{ mg/m}^2$  every 4 weeks in 3 cycles after radiotherapy, starting August 19, 1999. The pulmonary metastatic nodules were stable with chemotherapy. Then chemotherapy



**Fig. 2.** Magnetic resonance imaging of the neck before radiotherapy to the neck (A and B) and computed tomography imaging shortly after radiotherapy: pre-enhancement (C) and post-enhancement (D).



**Fig. 3.** Cytologic findings of fine needle aspiration of the neck mass: A cluster of tumor cells with spindle shaped cells suggesting metastatic leiomyosarcoma. Inset: High power view of tumor cells showed hyperchromatism and high N/C ratio.



**Fig. 4.** Computed tomography imaging of the abdomen, seven months after neck metastasis, showing a huge mass involving the right psoas muscle.

was interrupted for two months due to economic problems. At two months following the third cycle of the chemotherapy, the right neck mass grew back slowly in the area previously given 5,000 cGy; however, she could walk, has never developed spinal cord compression syndrome, and has maintained good swallowing for eight months since the neck radiotherapy.

Before the fourth round of chemotherapy, the pulmonary metastatic nodules were enlarged and computed tomography imaging of the abdomen revealed a huge mass involving the right psoas muscle, with erosion of the upper lumbar spinal

bodies (L2, 3) and destructive changes to the right transverse process of L3 (Fig. 4). After the fourth round of chemotherapy, the pulmonary metastatic nodules decreased in size. The patient died of disease at nine months after the neck radiotherapy.

## DISCUSSION

Uterine leiomyosarcomas are rare female neoplasms. According to recent definitions, uterine smooth-muscle tumors with five or more mitoses per 10 high-power fields and nuclear atypia are defined as leiomyosarcomas.<sup>1)</sup> Different prognostic parameters have been reported in uterine leiomyosarcoma. The most important prognostic factor is the extent of the tumor at diagnosis, determined by tumor stage.<sup>3~5)</sup> The importance of other prognostic factors, including age at diagnosis, menopausal age, and mitotic count, remains controversial.<sup>5)</sup> Invasion of tumor cells into vascular spaces is associated with reduced survival. Knowledge of lymph node status has minimal impact on the clinical management of women with uterine leiomyosarcoma.<sup>6)</sup>

Gadducci investigated treatment failures in 26 patients with early-stage I-II uterine leiomyosarcoma ( $\geq 10$  mitoses per high power field) retrospectively.<sup>2)</sup> The patients underwent total abdominal hysterectomy and bilateral salpingo-oophorectomy adjuvant external pelvic irradiation. Thirteen (50%) patients developed recurrent disease, after a median time of 10 months from surgery (range = 4 to 72 months). Recurrence was pelvic in 3 (23%) patients, extrapelvic in 9 (69%) patients, and both in 1 (8%) patient. Disease-free survival was better for premenopausal patients than for postmenopausal patients, and better for patients with  $< 20$  mitoses per 10 high power fields than for those with  $\geq 20$ .

Our case was initially stage Ic, premenopausal; the tumor showed extensive necrosis and more than 20 mitotic figures per 10 high power fields. The neck metastases were diagnosed 10 months after surgery.

The therapy of choice in uterine leiomyosarcoma is the removal of the uterus and the extrauterine lesions. Postsurgical adjuvant pelvic radiotherapy significantly decreased the vaginal and pelvic recurrence rates.<sup>7)</sup> A combination of surgery, radiotherapy, and chemotherapy can reduce pelvic recurrence as well as enhance survival.<sup>4)</sup> Whenever tumor recurrence or metastases develop, palliative surgery, radiotherapy, or chemotherapy may be attempted. Berchuck et al.

<sup>8)</sup> reported the effects of radiotherapy and chemotherapy to be beneficial in some patients with advanced or recurrent leiomyosarcoma. They also showed, however, that radiotherapy and chemotherapy were ineffective for palliation in the vast majority of patients with leiomyosarcoma.

The literature about the radiotherapy for the inoperable metastatic leiomyosarcoma is very rare. We treated the metastatic mass by 6,000 cGy in 30 fractions rather than 3,000 cGy in 10 fractions because the metastatic mass had grown slow and she did not develop the the spinal cord compression syndrome. If the patient's condition would be poor or the metastatic mass would show the rapid progression, the short course radiotherapy could be done. Because she could walk, has never developed spinal cord compression syndrome, and has maintained good swallowing for eight months since the neck radiotherapy and chemotherapy, both treatments may be considered for metastatic uterine leiomyosarcoma.

Information about chemotherapy in metastatic leiomyosarcoma is very limited. The activity of paclitaxel was determined in 33 chemotherapy-naive patients with advanced or recurrent uterine leiomyosarcoma.<sup>9)</sup> Eight patients (24.2%) had stable disease for at least 2 courses of therapy. Three complete remissions were reported (9.1%).

A patient who had a high-grade uterine leiomyosarcoma with extensive intra-abdominal and pulmonary metastases at the time of diagnosis underwent supracervical hysterectomy, bilateral salpingo-oophorectomy, and tumor-reducing surgery.<sup>10)</sup> She then received seven monthly courses of induction chemotherapy with paclitaxel 135 mg/m<sup>2</sup> and carboplatin, achieving remission with a small amount of residual disease. In our case, the same regimen was used. The right neck mass regressed progressively and pulmonary metastatic nodules were stable during 3 cycles of chemotherapy.

In conclusion, high dose radiotherapy and chemotherapy

with paclitaxel and carboplatin for metastatic leiomyosarcoma of the neck showed good palliative effect for eight months, and may be used for metastatic leiomyosarcoma.

## REFERENCES

1. Mayerhofer K, Obermair A, Windbichler G, et al. Leiomyosarcoma of the uterus: A clinicopathologic multicenter study of 71 cases. *Gynecol Oncol* 1999;74:196-201
2. Gadducci A, Fabrini MG, Bonuccelli A, et al. Analysis of treatment failures in patients with early-stage uterine leiomyosarcoma. *Anticancer Res* 1995;15:485-488
3. Nanassis K, Alexiadou-Rudolf CA, Tsitsopoulos P. Spinal manifestation of metastasizing leiomyosarcoma. *Spine* 1999; 24:987-989
4. Bai P, Sun J, Chao H. A clinical analysis of 153 uterine sarcomas. *Chung Hua Fu Chan Ko Tsa Chih* 1997;32:163-167
5. Larson B, Silfversward C, Nilsson B, Petterson F. Prognostic factors in uterine leiomyosarcoma. A clinical and histopathological study of 143 cases. The Radiumhemmet series 1936-1981. *Acta Oncol* 1990;29:185-191
6. Goff BA, Rice LW, Fleischhacker D, et al. Uterine leiomyosarcoma and endometrial stromal sarcoma. Lymph node metastases and sites of recurrence. *Gynecol Oncol* 1993;50:105-109
7. Jerezek B, Jassem J, Kobierska A. Sarcoma of the uterus. A clinical study of 42 patients. *Arch Gynecol Obstet* 1996;258:171-180
8. Berchuck A, Rubin SC, Hoskins WJ, Saigo PE, Pierce VK, Lewis JL. Treatment of uterine leiomyosarcoma. *Obstet Gynecol* 1988;71:845-850
9. Sutton G, Blessing JA, Ball H. Phase II trial of paclitaxel in leiomyosarcoma of the uterus. A gynecologic oncology group study. *Gynecol Oncol* 1999;74:346-349
10. Kudelka AP, Temrungruanglert W, Vadhan-Raj S, et al. Remission of advanced uterine leiomyosarcoma with pulmonary metastases with carboplatin and paclitaxel. *Anticancer Drugs* 1996;7:885-889

국문 초록

## 자궁 평활근육종의 경부림프절 전이와 방사선치료 및 화학요법에의 반응

조선대학교 의과대학 치료방사선과학교실\*, 병리학교실<sup>†</sup>, 내과학교실<sup>‡</sup>

오윤경\* · 박희철\* · 기근홍<sup>†</sup> · 전호중<sup>‡</sup> · 박유환<sup>‡</sup> · 정춘해<sup>‡</sup>

자궁 평활근육종의 경부림프절로의 전이는 지금까지 보고되지 않았으며 타 부위로의 전이 시에도 방사선치료는 드물게 이용되어왔다. 저자들은 자궁 평활근육종 환자에서 수술과 골반부 방사선치료를 시행 받고 10개월 후에 경부림프절 전이가 발생하여 인접한 후두주위공간, 척추골, 척추관을 함께 침습하였기에 방사선치료와 화학요법의 경험과 함께 보고하는 바이다. 전이된 종양은 수술이 불가능하여 방사선치료가 의뢰되었으며 총 6,000 cGy의 경부 방사선치료와 taxol과 carboplatin으로 화학요법을 시행하였다. 전이 암은 점차로 크기가 감소하여서 거의 만져지지 않을 정도로 되었다. 환자는 경부 방사선치료와 화학요법을 시행 받은 후 8개월간 척수압박증상을 발생하지 않았고, 연하곤란은 회복되어서 좋은 상태를 유지하였다. 광범위한 경부전이 암이 고선량 경부방사선치료와 화학요법에 좋은 국소 반응을 보였기에 수술이 불가능한 전이성 평활근육종 환자에서 이 두 가지 치료법이 고려될 수도 있겠다.

**핵심용어** : 자궁 평활근육종, 경부전이, 방사선치료, 화학요법