

Prosthetic rehabilitation in patient with soft palatal defect

The Catholic U. of Korea, College of Medicine, Department of Dentistry, & Columbia University School of Dental and Oral Surgery, New York, N.Y.

Myung-Woo Chang, DDS, Jongjin Kim, DDS, John D. Piro, DDS, Robert F. Wright, DDS

I. Introduction

Velopharyngeal closure¹⁾ refers to a sphincteric action sealing the oropharynx from the nasopharynx during swallowing and phonation by synergistic behavior of the middle third of the soft palate in superior and posterior direction, the lateral pharyngeal wall medially, and the posterior wall of the pharynx anteriorly.

Functional valving cannot be attained with velopharyngeal deficiencies which may be classified on the basis of functional and/or structural integrity. The Glossary of prosthodontic terms defines *palatopharyngeal inadequacy*¹⁾ as "a condition where there is lack of effective closure between soft palate and one or more of the pharyngeal walls during swallowing or speech sounds that require high intraoral pressure." Palatopharyngeal incompetence and palatopharyngeal insufficiency are often described for defining this palatopharyngeal inadequacy. *Palatopharyngeal insufficiency*¹⁾ refers to patients with an acquired or congenital anatomic defect of soft palate that makes the palatopharyngeal sphincter incomplete, but with movement of remaining tissues within normal physiological limits.

The soft palatal defect is functional one constantly changing in size and shape during physiologic func-

tion. The functional deficits may include hypernasality of speech and leakage of food and fluids into the nasal passages during deglutition. Most acquired soft palate defects results from surgical resection of neoplastic disease and from trauma. Beumer²⁾ described that the reconstructive surgery of acquired soft palatal defects is not indicated because of excessive tissue loss and the need to monitor the tumor site for recurrent disease. Also surgical reconstruction of these defects can result in a deficient, non-functioning palatopharyngeal mechanism. Therefore, a pharyngeal obturator prosthesis can be used for those patients with congenital and acquired soft palate defects. (Fig.1) During function, the adjacent structure of the remaining soft palate, posterior and lateral pharyngeal walls close around prosthesis, thereby separating the nasopharynx and oropharynx. This article describes a prosthetic treatment for rehabilitation in individuals with palatopharyngeal insufficiency.

Physiology of the palatopharyngeal closure^{2,3,6)}

There are three elements to explain in closure of the palatopharyngeal structure. These are the posterior pharyngeal wall, the lateral pharyngeal wall and the soft palate. During speech, the

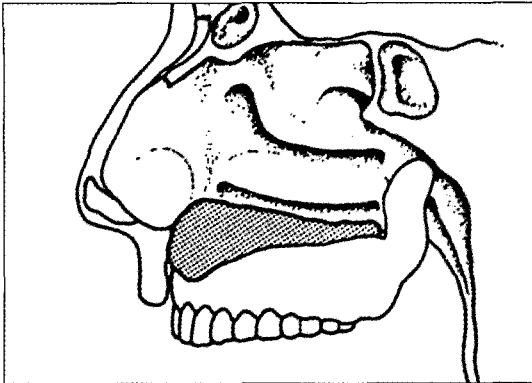


Fig. 1. Pharyngeal Obturator Prosthesis (Permitted by DR. Tomas Taylor)

anterior two thirds of the palate is raised, decreasing the anteroposterior diameter of the velopharyngeal sphincter and creating a levator eminence owing to the bunching of active levator veli palatini muscle, which inserts into the middle one third of soft palate⁷. Recent studies also confirmed that the levator veli palatini muscle moved the lateral pharyngeal walls posteriorly and medially to close the lateral opening into the nasopharynx⁸. The attachment of the superior constrictor muscle at the pharyngeal tubercle inserts into the center of oral cavity and region of Passavant's ridge⁴ when it is present. Passavant's ridge is a compensatory mechanism occurring in approximately one third of speakers with palatopharyngeal incompetence and only occasionally in normal speaker. Synchronous with the palatal elevation, a medial movement of lateral pharyngeal wall creates a tight palatopharyngeal closure. This constructive action of the palate is probably mediated by upper fibers of the superior constrictor muscle and levator veli palatini muscle. The narrowing of the pharyngeal isthmus by the posterior-medial movement of the lateral pharyngeal walls is more important than the forward

movement of the posterior pharyngeal wall for pharyngeal reduction. The palatopharyngeus muscle narrows the lateral pharyngeal wall during speech and swallowing. Therefore, the

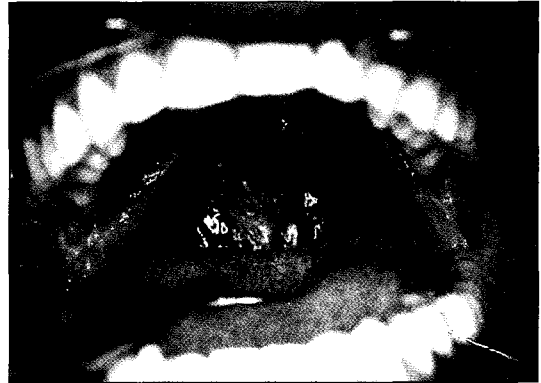


Fig. 2. The tumor of the soft palate was resected.

palatopharyngeal closure during speech is the result of two types of motion : a midsagittal palatopharyngeal contact and medial motion of localized regions of both lateral pharyngeal walls against the palate. It is important to recognize that the level of maximum lateral pharyngeal wall movement is approximately at the level of hard palate. The level of this lateral pharyngeal wall movement is an critical factor in planning prosthetic rehabilitation.

II . Methods and Materials

A 30 year old man was referred to the Maxillofacial Prosthetics Center at Columbia University School of Dental and Oral Surgery in 1998. He was diagnosed with Polymorphous Low-Grade Adenocarcinoma (PLGA) of the soft palate. The tumor of the soft palate was resected (Fig. 2), followed by postoperative full course of external-beam radiotherapy at Columbia University's affiliate, Harlem Hospital of New York City in 1997.

On oral examination, the patient exhibited considerable movement of the residual palatopharyngeal complex during function. The lateral and posterior pharyngeal walls exhibit normal movement. Most of his speech was not intelligible and the patient's voice quality was apparently hyper-

nasal. The construction of an obturator prosthesis was decided to assist the patient in attaining palatopharyngeal closure for speaking and swallowing.

Prosthesis Construction

The preliminary impression of the palate is made with an irreversible hydrocolloid impression material. The palatal portion of the stock tray was extended with wax so the soft palatal defect would be recorded. The metal framework of prosthesis was designed and constructed with the focus on securing maximum retention and stability, and employing all possible area for indirect retention (Fig. 3).

Palatal extension section was constructed of a cast metal bar which should be extended horizontally to pass posterior limit of the soft palate into the nasopharynx.(Fig. 2) This portion should not contact mucosa at any point. After the framework was fitted on the remaining dentition, the molding of the obturator segment with modeling plastic (Kerr Co., Emeryville, CA) was

performed. The modeling plastic was as warm as the patient can tolerate, as pharyngeal tissue did not contact except in swallowing. The height of the bulb was increased until a depression was evident in superior aspect from contact with the posterior portion of the vomer. The bulb was molded anteriorly and medially until the bulge of inferior tubinate was indicated. When the molding process was completed, the modeling plastic was heated again to obtain a functional impression by having the patient perform side-to-side and forward bending movements of the head. The patient was then instructed to speak, swallow, and breathe through nose. The prosthesis was chilled and removed. All extensions of the modeling plastic were relived 2 to 3 mm with a sharp scalpel. A mouth temperature thermoplastic wax (Adaptol, Jelenko Co., New Rochelle, NY) was added to the obturator (Fig. 4). This was tempered in warm water, and the prosthesis was inserted in the mouth.

The patient was instructed the functions securing a physiologically adapted impression of nasopharynx in all body posture such as swallowing

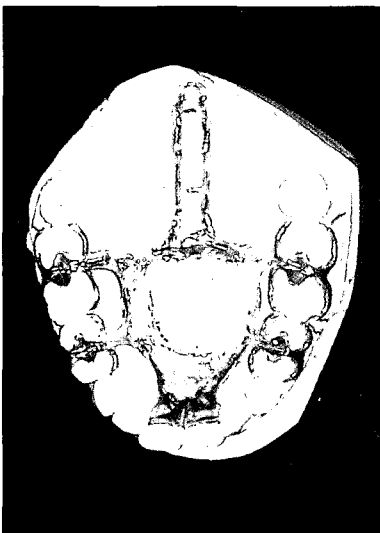


Fig. 3. Metal framework of prosthesis was constructed.

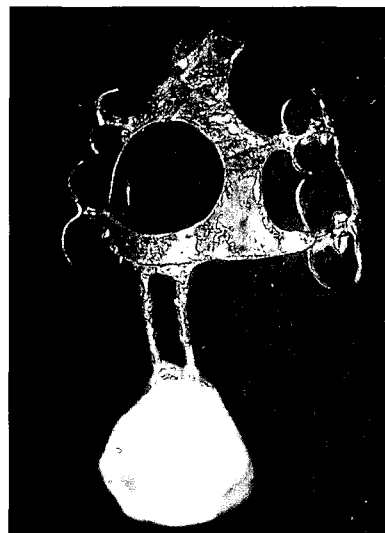


Fig. 4. Functional impression with thermoplastic wax

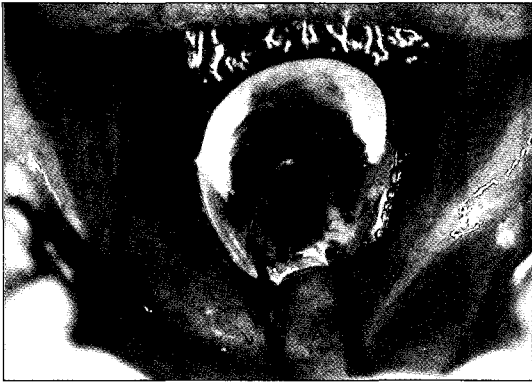

Fig. 5. The prosthesis was inserted.

and head movements. The prosthesis was left in the mouth for 5 minutes, at which time the patients performed the functional movement several times. The prosthesis was removed and chilled with cold water. When the speech and swallowing were acceptable, the prosthesis is tempered and reinserted in the mouth for an extended period. The patient wore the prosthesis for at least one hour and was instructed to speak, eat, drink, and perform the head movements. The patient was given a glass of cold water and the functional impression was removed. The impression was stored in the ice cold water. The obturator was processed with heat-polymerizing clear methyl methacrylate (Fig. 5). The superior surface should be convex to avoid the collection of nasal secretions. The posterior surface of the prosthesis should contact the posterior pharyngeal wall only in function. The inferior surface should be concave for tongue movement. The lateral surface should also contact the lateral pharyngeal wall only in function. On insertion of the completed prosthesis, the possibility of leakage of food and liquids into the nasal cavity was emphasized, and need to remove and clean frequently for hygiene was advised. The patient was instructed to wear the prosthesis constantly. The patient demonstrated an increase in speech intelligibility and an improved deglutition with use of a obturator prosthesis. The periodic

recall examination included an evaluation of the area of irritation, and assessment of retention, stability, support, and speech.

III . Conclusion

The pharyngeal obturator is fabricated to separate the nasopharynx and oropharynx during normal speech and deglutition. The palatopharyngeal closure decreases nasal air flow, increase oral pressure for consonant articulation, and improve voice quality. It is proven that the pharyngeal obturator is effective to improve palatopharyngeal insufficiency with soft palatal defects during physiologic function in selected cases.

References

1. The Glossary of Prosthodontic Terms. J Prosthet Dent 1994:91
2. Maue-Dickson, W., and Dickson, D.R. : Anatomy and Physiology related to cleft palate : Current research and clinical implication. Plast Reconstr Surg 65:83, 1980
3. Beumer, J., Curtis, T.A., and Firtell, D.N. : Maxillofacial Rehabilitation : Prosthodontic and Surgical Consideration. St. Louis, 1979, The C.V. Mosby Co.
4. Calnan, J. : The error of Gustav Passavant. Plast Reconstr Surg 13: 275, 1954
5. Lavorato, A., and Lindholm, C. : Fibroptic visualization of motion of the eustachian tube. Trans Am Acad Ophthalmol Otolaryngol 84:534, 1977
6. Beumer III, J., Curtis, T.A., Marunick, M.T., Maxillofacial Rehabilitation Prosthodontic and Surgical Consideration. Ishiyaku Euro America, Inc, 1996
7. Calnan, J.S. : Movement of soft palate. Brit J Plast Surg 5:286, 1953

연구개 결함을 가진 환자의 보철적 수복

장명우 · 김종진 · John D. Piro · Robert F. Wright

가톨릭대학교 의과대학 치과학교실, Columbia 치과대학 보철과

연구개는 그 주위조직과 더불어 생리적 기능에 있어 음성, 연하, 및 호흡 등에 중요한 역할을 한다. 종양 등의 이유로 인한 연구개의 외과적 절제는 그 해부학적 크기와 모양의 영구적인 변화로 인해 여러기능의 상실을 초래한다..

이에 따른 결함은 과도한 비음, 연하중 음식물이나 유동물의 비관으로의 누출 등을 들 수 있다. 연구개와 그 주위조직의 생리적인 기능의 숙지 및 이를 응용한 보철물(Palatopharyngeal Obturator)의 적절한 제작은 이러한 기능적 결함을 수복하는데 이용되어진다. 본 증례에서는 종양으로 인해 연구개를 절제한 환자의 보철적 수복에 있어, 구강내 온도에 따라 그 형상이 변화하는 인상재를 이용하여, 측-후 인두벽의 운동을 기능적으로 인기하는 방법을 이용하였다. 이러한 방법으로 제작된 보철물은 종양으로 인한 연구개의 절제 후 생리적인 기능의 장애를, 올바른 Palatopharyngeal 폐쇄를 유도함으로써 음질의 향상, 연하 등의 기능을 회복시키는데 큰 도움이 될 수 있음을 보여준다.