

이식 신장에서 시행한 Tc-99m MAG3 SPECT

계명대학교병원 핵의학과

류종걸 · 김 순 · 전석길

Tc-99m MAG3 SPECT on Transplanted Kidney

Jong Gul Ryu, M.D., Soon Kim, M.D. and Seok Kil Zeon, M.D.

Department of Nuclear Medicine, Keimyung University School of Medicine, Taegu, Korea

Abstract

Purpose: This study was designed to evaluate the usefulness of a technetium-99m mercaptoacetyltriglycine (Tc-99m MAG3) single photon emission computed tomography (SPECT) performed on transplanted kidney. **Materials and Methods:** Thirty renal transplant patients were included in this study. Planar scan was performed for 30 minutes using 555 MBq Tc-99m MAG3. A post-voiding SPECT scan was acquired on the third, seventh, fourteenth and twenty eighth day after transplantation. **Results:** SPECT scan showed interpretable image quality in 26 of 30 patients (86.7%) and 84 in 120 scans (70%). Fourteen of 26 patients with interpretable SPECT image showed decreased or increased radioactivity, but only 5 had abnormal findings on the planar scan. Focal SPECT defects were seen in allografts with normal function (n=3), acute tubular necrosis (n=3), and acute rejection (n=2). The defects are thought to reflect focally underperfused renal parenchyme or, in normal allografts, an artifact from uneven radioactivity distribution. Four of 10 patients with renal arterial variation showed focally decreased radioactivity and SPECT helped guide further studies that confirmed the exact cause. Five of 10 patients with acute tubular necrosis or acute rejection showed focally decreased radioactivity, but its relation to the patients' clinical course was not clear. Focally increased radioactivity was observed in 5 allografts with normal function and 1 with double ureter in which local clearance delay was observed. **Conclusion:** Tc-99m MAG3 SPECT renal scan can detect additional focal abnormalities compared to planar scan. Further study is necessary to elucidate the exact clinical significance of the SPECT findings. (*Korean J Nucl Med* 1999;33:519-26)

Key Words: Tc-99m MAG3, SPECT, Renal transplant, Parenchymal abnormality

Introduction

Radionuclide renal imaging agents such as technetium-99m dimercaptosuccinic acid (Tc-99m DMSA)¹⁾ and Tc-99m glucoheptonate (GHA)^{2,3)} have been used in evaluating abnormalities of the renal cortex or parenchyme. In contrast, Tc-99m mercaptoacetyltriglycine (MAG3), an imaging agent

Received Apr. 16, 1999; revision accepted Oct. 8, 1999
Corresponding Author: Seok Kil Zeon, M.D., Department of Nuclear Medicine, Keimyung University School of Medicine, 194 Dong San Dong, Taegu, 700-712, Korea
Tel: 82-53-250-7764, Fax: 82-53-250-7132
E-mail: Zeon@dsmc.or.kr

excreted through renal tubule, has been used for evaluating global renal function.^{4,5)} Occasionally, a renal parenchymal abnormality can be seen on the Tc-99m MAG3 planar scan.⁶⁾ Since resolution of the single photon emission computed tomography (SPECT) scan is far superior to that of the planar scan, SPECT scan is more beneficial in the evaluation of renal parenchymal abnormality that can be detected on Tc-99m MAG3 planar scan.

Thus, this study was designed to analyze whether the Tc-99m MAG3 SPECT image of a transplanted kidney can consistently offer interpretable image quality and/or additional information to planar scan.

Materials and Methods

One hundred and twenty planar and SPECT scans on 30 patients who had undergone renal transplantation were performed prospectively on the third, seventh, fourteenth and twenty eighth day after surgery to evaluate the allograft renal function. There were 15 male and 15 female, and mean age was 35.0 years old (range: 15-57).

Following a bolus injection of 555 MBq Tc-99m MAG3 (Mallinckrodt Medical Inc., USA), an anterior scan was taken in the supine position. Using a gamma camera (Dual Head Genesys and Dual Head Vertex, ADAC Lab. Co., USA) equipped with a low energy, high resolution parallel-hole collimator, two-phase planar dynamic study was acquired; the first at two seconds per frame for 120 seconds, and the second at one minute per frame for 28 minutes. Immediately after the planar scan, post-voiding SPECT scan was performed. The reason for bladder voiding was to avoid back-projection artifact due to radioactivity in the urinary bladder or renal pelvis. It was possible to carry out the SPECT scan on an average of 7.8 minutes following the planar scan. For the SPECT study,

each projection data were obtained in a $64 \times 64 \times 16$ matrix, and 128 projections were acquired (3° steps, 20 seconds/projection). Acquired data were filtered with Butterworth filter, and reconstructed into transverse, coronal and sagittal images after attenuation correction.

A renogram, the time-activity curve of the allograft kidney, was obtained in each scan and included in this study. Diagnosis of acute tubular necrosis (ATN) and acute rejection (AR) was dictated by clinical course and/or renal biopsy.

Analysis was performed to find out whether Tc-99m MAG3 SPECT scan could provide consistent interpretable image quality, and whether radioactivity distribution throughout renal parenchyme was normal, focally decreased or focally increased. Follow-up SPECT images were analyzed and categorized as persistently abnormal, resolved of abnormality, or new abnormal radioactivity distribution. A comparative analysis of the findings from each SPECT scan with that of the corresponding planar scan was performed. Any arterial variation of the donor kidney was analyzed with the scan findings. Furthermore, the pattern of parenchymal radioactivity distribution observed on the scans were compared with clinical settings, which were categorized as normal functioning allograft kidney, ATN or AR.

Results

Among the total 30 patients, 26 (86.7%) had Tc-99m MAG3 SPECT scans that showed interpretable image quality. Of the 26 patients, 16 (61.5%) had normal renal function while 7 had ATN and 3 AR. Sixteen (61.5%) of the 26 patients showed interpretable image quality in all four of the consecutive studies, while the images were interpretable in three studies for 3, two studies in 4, and only one study in one patient. Out of a total

of 10 patients who had global excretion impairment from either ATN or AR, 9 (90%) showed interpretable image quality in all four studies.

Eighty-four of 120 scans (70%) showed interpretable image quality. Thirty-two of these interpretable scans were images of allografts with global excretion impairment from ATN or AR at the time of scan acquisition, while remaining 52 scans were of normal functioning allografts.

Sixteen of the 30 patients showed normal findings in both SPECT and planar scans. The remaining 14 patients exhibited abnormal findings of focally decreased or increased radioactivity on SPECT scans. Planar scan could only detect 5

patients with abnormal findings (remaining 9 patients demonstrated normal findings), all of which were focal decreased radioactivity and were also detected by SPECT (Table 1).

Eight patients showed focally decreased radioactivity on their SPECT scans (Table 2); 3 demonstrated normal renal function, 2 had AR (Fig. 1) and 3 ATN (Fig. 2). Of the 3 normal functioning allografts, 2 had been identified as having a polar artery, while a case of double renal arteries had been demonstrated in 1 allograft each of the 2 AR cases and 3 ATN cases, respectively. Consequently, 1 of the 8 patients with decreased activity on SPECT had a normal functioning allograft

Table 1. Comparison of Tc-99m MAG3 SPECT with Planar Scan Findings in 26 Patients Who Underwent Renal Transplantation

SPECT scan	Planar scan			Total
	Normal*	Decreased [†]	Increased [‡]	
Normal	12	0	0	12
Decreased	3	5	0	8
Increased	6	0	0	6
Total	21	5	0	26

* no abnormality in distribution of radioactivity.

[†] focally decreased radioactivity.

[‡] focally increased radioactivity.

Table 2. Sequential Assessment of Renal Transplants with Focally Decreased Radioactivity on Tc-99m MAG3 SPECT Scans

Function, Anatomy	Sequential assessment			
	3 days	7 days	14 days	28 days
Normal, polar artery	decreased	improved	improved	NI
Normal, polar artery	decreased	decreased	improved	normal
Normal, unremarkable	decreased	decreased	decreased	decreased
AR, double artery	decreased	normal	normal	normal
AR, unremarkable	decreased	decreased	improved	improved
ATN, double artery	normal	normal	decreased	decreased
ATN, unremarkable	decreased	aggravated	normal	normal
ATN, unremarkable	decreased	decreased	decreased	decreased

NI, not interpretable image quality; AR, acute rejection; ATN, acute tubular necrosis.

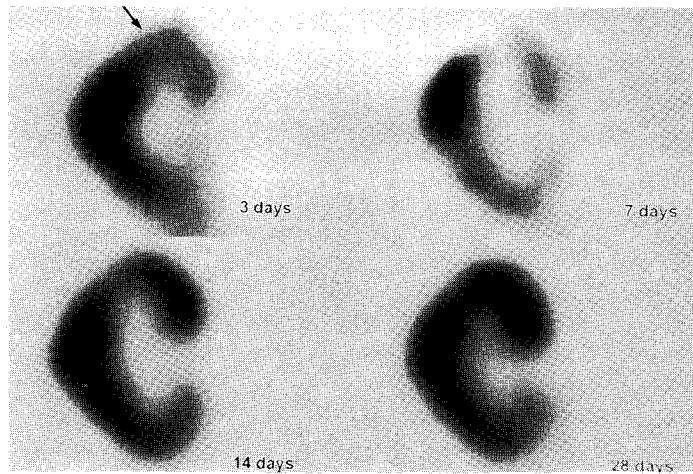


Fig. 1. Coronal tomographs of sequential Tc-99m MAG3 renal SPECT studies in a 57 years old man with acute rejection of the allograft kidney. There is a focal area of decreased radioactivity (arrow) in the upper pole on the initial scan (3 days after surgery), which continuously improves on follow-up scans.

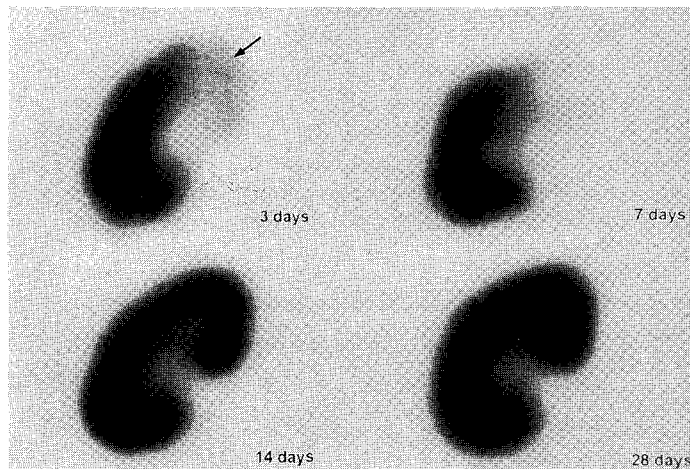


Fig. 2. Coronal tomographs of sequential Tc-99m MAG3 renal SPECT studies in a 35 years old woman with acute tubular necrosis of the allograft kidney. There is focally decreased radioactivity (arrow) in the upper pole on the initial and first follow-up scans (3 and 7 days), which were completely resolved in further follow-up scans.

without any arterial variation. Seven of the 8 patients demonstrated areas of decreased activity on the first SPECT, performed on day 3 following surgery, of which 5 were resolved or reduced in

size and 2 were persistent on follow-up scans. The remaining 1 patient had normal findings on the first postoperative study but demonstrated focally decreased radioactivity on all of the follow-up

scans.

Of the 30 subjects included in this study, 10 patients (33.3%) had received donor kidneys with arterial variation (Table 3). Four were kidneys with a renal polar artery, and 6 had a double renal artery. Two kidneys with each type of arterial variation demonstrated SPECT findings of focally decreased radioactivity.

Ten of the thirty patients revealed ATN (n=7) or AR (n=3), and among them 5 patients (50%) showed focally decreased radioactivity.

Six patients showed focally increased radioactivity on SPECT scans; two patients were resolved on follow-up studies; four patients revealed persistent findings (Table 4). These two resolved patients showed normal renal function, one of them had polar artery in the donor kidney. One of the four patients with persistently increased radioactivity had ATN with double ureter in the donor kidney (Fig. 3). The remaining three of four

patients showed normal renal function with two of patients having double renal artery.

Discussion

Because SPECT imaging offers three dimensional image, which is far superior to planar scan, SPECT is considered better than planar scan in evaluating renal parenchymal abnormalities appearing on Tc-99m MAG3 planar scan. Neubauer et al^{7,8)} reported that it was possible to evaluate the renal parenchymal abnormality with Tc-99m MAG3 SPECT scan on transplanted kidney.

Tc-99m MAG3 is excreted rapidly via tubular excretion and thus dose not usually allow SPECT acquisition.^{9,10)} However, since it is a high photon flux renal tracer, SPECT can be done with high speed tomographic devices such as multi-head gamma camera, which can shorten the acquisition time. The earlier the starting time of the SPECT

Table 3. Renal Arterial Variation and Tc-99m MAG3 SPECT Scan Findings of Renal Transplant

	SPECT scan findings				Total
	Focal decreased	Focal increased	Normal	NI	
Polar artery	2	1	0	1	4
Double arteries	2	2	1	1	6
Total	4	3	1	2	10

NI, not interpretable image quality.

Table 4. Sequential Assessment of Renal Transplants with Focal Increased Radioactivity on SPECT Scans

Function, Anatomy	Sequential assessment			
	3 days	7 days	14 days	28 days
Normal, polar artery	normal	increased	increased	normal
Normal, unremarkable	increased	increased	normal	normal
ATN, double ureter	normal	increased	increased	increased
Normal, double artery	NI	increased	increased	increased
Normal, double artery	NI	NI	NI	increased
Normal, unremarkable	NI	NI	increased	increased

ATN, acute tubular necrosis; NI, not interpretable image quality.

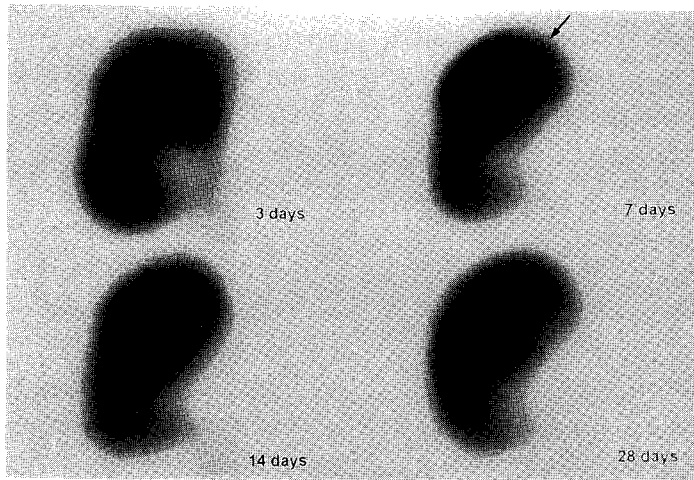


Fig. 3. Coronal tomographs of sequential Tc-99m MAG3 renal SPECT studies in a 29 years old woman with double ureters. There is normal distribution of radioactivity throughout the transplanted kidney and good visualization of the double ureters on the initial scan (3 days), but follow-up scans reveals non-visualization of upper ureter and persistent focally increased radioactivity (arrow) in the upper pole.

scan, the better the quality image obtained. As all patients void their bladder immediately after the routine planar scan, the SPECT scans could be obtained quickly. As a result, the SPECT studies were initiated at an average of 7.8 minutes following the planar scan.

In this study, SPECT scans were performed in patients with normal allograft function as well as in patients with abnormal renal function. Some of the patients had renal arterial variation and it was expected that sequential SPECT scans could provide information about the clinical significance and course of arterial variation. Subclinical abnormality could exist even in the presence of normal global renal function, and SPECT scan may be able to demonstrate this abnormality.

SPECT scans showed interpretable image quality in 26 of all 30 patients (86.7%) and in 84 of the total 120 scans (70%), indicating that SPECT scan provides interpretable image quality with relative consistency. Especially, in cases of global excre-

tion impairment such as ATN or AR, interpretable quality images were easily acquired due to intense remnant radioactivity in the renal parenchyme. This finding corresponds to the results reported by Neubauer et al.^{7,8)} Even in cases with normal renal function, SPECT scan showed interpretable image quality at the rate of 61.9%.

Of total 30 patients, 14 showed abnormal findings of focal decreased or increased radioactivity. But only five of the 14 patients (35.7%) showed abnormality on planar scans, and planar scans demonstrated none of the focal increased radioactivity seen in the SPECT scans. Consequently, it is obvious that SPECT scan detects much more additional findings than planar scan.

Eight (26.7%) of the thirty patients showed focally decreased radioactivity on SPECT scans of transplanted kidney (Table 2). Two of them had polar artery in the donor kidney, and the area of perfusion from this artery showed decreased radioactivity. The cause of this decreased radioac-

tivity was assumed to be due to a lack of vascular supply.⁸⁾ Five patients (62.5%) had ATN or AR with (n=2) or without combined arterial variation. Perfusion abnormality associated with these lesions was assumed to be the cause of decreased radioactivity.^{7,8,11)} No cause was determined in the remaining one case. Five (62.5%) of eight patients with focally decreased radioactivity showed resolved or reduced in size on follow-up scans, which were assumed to be an ischemic area. The other three patients (37.5%) had persistent findings of decreased radioactivity, which were consequently concluded to be an infarcted area. But we could not rule out the possibility of normal uneven radioactivity distribution in these cases. Further study such as Tc-99m DMSA renal scan maybe necessary to confirm exact nature of focal decreased radioactivity.

Ten (33.3%) of the thirty patients had arterial variation in the donor kidneys (Table 3), similar to the results reported by Zeon et al.¹²⁾ Four had renal polar artery, and six had double renal artery. Six of the ten patients did not show focally decreased radioactivity in initial and follow-up SPECT scans, which suggested that there was at least no ischemic area and further study was not needed. In the remaining four patients, SPECT scan showed focally decreased radioactivity in the transplanted kidney. Three of four cases were resolved on follow-up scans; the area with decreased radioactivity was assumed to be ischemic area. The remaining one patient showed persistent findings of focally decreased activity, which was believed to be an infarcted area. In these cases with decreased radioactivity, it was thought that further confirmatory study was needed to differentiate ischemia or infarction from normal variation of uneven distribution. Sequential SPECT scans could be a guidance for further study that confirmed exact cause of decreased radioactivity.

Among the ten patients with ATN or AR, five showed focally decreased radioactivity on the SPECT scan. Whereas, of the 20 patients with normal allograft function, three showed focally decreased radioactivity. Focally decreased radioactivity was more frequent in patients with ATN and AR, but relationship between focally decreased radioactivity and clinical course was not clear (Table 2).

Six (20%) of the thirty patients showed focally increased radioactivity on SPECT scans (Table 4); two (33.3%) of them were resolved on follow-up SPECT scans. In all but four patients (66.7%), areas of increased radioactivity persisted. One of six patients had double ureter in the donor kidney; on the first SPECT scan, distribution of radioactivity was normal with two visible ureters. But on follow-up SPECT scan, one of the two ureters was not visible and an increased radioactivity was seen in that area. On the next follow-up SPECT scans, areas of increased radioactivity persisted. Focal excretion impairment was believed to be the cause of this increased radioactivity (Fig. 3), but other causes such as venous stasis or an artifact could not be ruled out. Further study is needed define the exact cause.

요 약

목적: 이식 신장에서 시행한 Tc-99m MAG SPECT 스캔의 유용성을 평가하고자 하였다. **대상 및 방법:** 신장 이식환자 30명, 120 스캔을 연구대상으로 하였다(남:여=15:15, 평균연령 35.0세). 수술 후 3일, 7일, 14일 및 28일에 555~740 MBq의 Tc-99m MAG3를 순간주사하여 평면스캔을 시행하고, 배뇨한 후 즉시 SPECT 스캔을 실시하였다(평균 SPECT 스캔 시작 시간: 평면스캔 후 7.8분). **결과:** SPECT 스캔은 전체 환자 30명 가운데 26명(86.7%)에서, 전체 120 스캔 가운데 84 스캔(70%)에서 판독 가능한 영상화질을 보여, 비교적 일관성 있게 판독 가능

한 영상화질을 제공할 수 있음을 알았다. 30명 가운데 16명(53.3%)의 이식신장은 SPECT 및 평면스캔에서 정상 소견을 보였고, 나머지 14명(46.7%)은 SPECT 스캔에서 국소방사능 감소 혹은 증가의 이상소견을 보였는데, 이 가운데 평면스캔에서도 이상소견을 보인 환자는 5명(35.7%) 뿐이었고, 모두 국소방사능 감소 소견이었다. 따라서, SPECT 스캔이 평면스캔에 비해 훨씬 더 많은 추가적인 국소 이상을 검출할 수 있다는 사실을 알 수 있었다. SPECT 스캔에서 국소방사능 감소 소견을 보인 환자는 8명이었으며, 정상 신기능을 보인 환자가 3명, 급성 세뇨관괴사3명, 그리고 급성 거부반응이 있었던 환자가 2명 이었다. 국소방사능 감소는 국소적 관류이상에 의한 것으로 추정되었으나, 정상적인 불균일 방사능 분포의 가능성을 배제하지는 못하였다. 공여신장에 동맥변이가 있었던 환자는 30명 가운데 10명이었고, 이 가운데 4명이 국소방사능 감소 소견을 보였다. 연속적으로 시행한 SPECT 스캔은 방사능 감소의 정확한 원인을 확인 하는 추가검사의 시행여부를 결정하는데 도움이 될 수 있을 것으로 생각되었다. 급성 세뇨관괴사나 급성 거부반응이 있었던 환자는 30명 가운데 10명이었으며, 이 가운데 국소방사능 감소 소견을 보인 환자는 5명으로 정상 신기능을 보인 환자에 비해 높은 빈도를 보였으나, 방사능 분포의 이상과 임상경과 간의 관계는 분명하지 않았다. 국소방사능 증가 소견이 있었던 환자는 6명이었으며, 국소방사능 증가는 국소적 배설기능 장애에 의한 것으로 추정되었으나, 정맥혈 정체와 같은 다른 원인도 생각해 볼 수 있으므로, 정확한 원인을 알기 위해서는 추가적인 연구가 필요할 것으로 생각된다. 결론: Tc-99m MAG3 SPECT 스캔은 용이하게 시행할 수 있으며, 평면영상보다 많은 경우에 추가적인 국소 이상을 검출할 수 있다. 앞으로 이러한 이상소견의 임상적 의의에 대한 연구가 더 필요하겠다.

References

- 1) Tarkington MA, Fildes RD, Levin K, Ziessman H, Harkness B, Gibbons MD. High resolution single photon emission computerized tomography (SPECT) ^{99m}Tc-dimercapto-succinic acid renal imaging: a state of the art technique. J Urol 1990;144:598-600.
- 2) Joseph DB, Young DW, Jordon SP. Renal cortical scintigraphy and single photon emission computerized tomography (SPECT) in the assessment of renal defects in children. J Urol 1990;144:595-7.
- 3) Yeo EE, Miller JH. The role of SPECT imaging in pediatric renal transplants. Clin Nucl Med 1994;19:1045-8.
- 4) O'Malley JP, Ziessman HA, Chantarapitak N. Tc-99m MAG3 as an alternative to Tc-99m DTPA and I-131 hippuran for renal transplant evaluation. Clin Nucl Med 1993;18:22-9.
- 5) Russell CD, Thorstad BL, Stutzman ME, Yester MV, Fowler D, Dubovsky EV. The kidney: imaging with Tc-99m mercaptoacetyltriglycine, a technetium-labeled analog of iodohippurate. Radiology 1989;172:427-30.
- 6) Laguna R, Silva F, Orduna E, Conway JJ, Weiss S, Calderon C. Technetium-99m-MAG3 in early identification of pyelonephritis in children. J Nucl Med 1998;39:1254-7.
- 7) Neubauer N, Johnson L, Lemmers M, Petri B, Stevens J. MAG3 renal transplant tomography SEPCT with a non-SPECT agent. Clin Nucl Med 1996;21:11-4.
- 8) Neubauer NJ, Johnson LJ, Lemmers MJ, Haas BB, Jarboe GL, Stevens JS. Renal transplant nuclear tomography using Tc-99m MAG3. Clin Nucl Med 1996;21:851-4.
- 9) Bubeck B, Brandau W, Weber E, Kalble T, Parekh N, Georgi P. Pharmacokinetics of technetium-99m-MAG3 in humans. J Nucl Med 1990;31:1285-93.
- 10) Fritzberg AR, Kasina S, Eshima D, Johnson DL. Synthesis and biological evaluation of technetium-99m MAG3 as a hippuran replacement. J Nucl Med 1986;27:111-6.
- 11) Striker G, Striker LJ, D'Agati V. The renal biopsy. 3rd ed., Philadelphia: W.B. Saunder Company; 1997. p. 242-57.
- 12) Zeon SK, Kim JS, Kim HC. Angiographic analysis of renal artery and vein in 85 candidates of renal transplant donor. J Korean Radiol Soc 1990;26:179-85.