

Control of clonorchiasis by repeated praziquantel treatment and low diagnostic efficacy of sonography

Sung-Tae HONG*¹⁾, Kisung YOON¹⁾, Mejeong LEE¹⁾, Min SEO¹⁾, Min-Ho CHOI¹⁾,
Jung Suk SIM⁴⁾, Byung Ihn CHOI²⁾, Chong Ku YUN³⁾ and Soon-Hyung LEE¹⁾

*Departments of Parasitology and Institute of Endemic Diseases¹⁾, Radiology²⁾, and Pediatrics³⁾,
Seoul National University College of Medicine, Seoul 110-799, and Department of Radiology⁴⁾,
Puchon Sejong Hospital, Puchon 422-232, Korea*

Abstract: In Korea, *Clonorchis sinensis* infection is still highly prevalent because case detection in the field is difficult and the detected cases used to be incompletely cured due to treatment failure. The present study tried to control clonorchiasis in an endemic village by repeated treatments with praziquantel every 6 months and to evaluate sonography as a diagnostic measure. By stool examinations, the egg positive rate in the endemic village was 22.7%, but it decreased to 19.6% at 6 months, 15.1% at 12 months, 12.2% at 18 months, 6.3% at 24 months, 11.4% at 30 months, and 6.3% at 42 months after the beginning of repeated praziquantel administration. The sonography showed 61 (49.6%) positive cases of 123 screened residents; among egg-positives the sonography positive rate was 52.2% and among egg-negatives it was still 49%. The rate among cured cases was 64.3% after 6 months, 50.0% after 12 months, 50.0% after 18 months, and 66.7% after 24 months. In a non-endemic village, 64 residents were found egg-negative by fecal examination, but 20 (31.3%) of them were positive by sonography. The present findings indicate that control of clonorchiasis in an endemic village by repeated praziquantel treatment for 42 months is still insufficient and sonography is of little value for diagnosis of clonorchiasis.

Key words: *Clonorchis sinensis*, fecal examination, sonography, repeated praziquantel treatment

INTRODUCTION

Clonorchis sinensis is known to be prevalent in China, East Russia, Korea, Taiwan, and Vietnam, and it is estimated that about 15 million people are infected (Rim, 1986; Li et al., 1997). According to national surveys, the

overall egg-positive rate of *C. sinensis* in Korea was 4.6% in 1971, 1.8% in 1976, 2.6% in 1981, 2.7% in 1986, 2.2% in 1992, and 1.4% in 1997 (Ministry of Health and Welfare, 1997). Despite the fact that treatment of positive cases has been free of charge, clonorchiasis is still prevalent along rivers throughout the country. The sixth national survey revealed that in 1997 there were at least 626,000 cases of clonorchiasis in Korea and that this disease is the country's most prevalent parasitic infection (Ministry of Health and Welfare, 1997).

During infection by the fluke, the bile duct is severely dilated and the ductal wall is

• Received 23 October 1998, accepted after revision 24 November 1998.

• This study was supported by a grant No. 01-97-062 from Seoul National University Hospital research fund (1997).

* Corresponding author (e-mail: hst@plaza.snu.ac.kr)

thickened due to mucosal hyperplasia and periductal fibrosis (Lee *et al.*, 1978; Chen *et al.*, 1994). As the infection becomes chronic and the number of infected fluke increases, pathological changes in the duct become worse and in certain occasions complications develop (Rim, 1990; Chen *et al.*, 1994). Especially widening of the duct and thickening of the wall, which can be visualized by sonography, are known to be partially irreversible (Lee *et al.*, 1987).

For the control of clonorchiasis, diagnosis is important, and for this, fecal examination is the preferred standard method. Other supplementary diagnostic methods have been applied, including intradermal test, ELISA, immunoblotting, sonography, CT scan, and cholangiography (Lim *et al.*, 1989; Rim, 1990; Chen *et al.*, 1994), but all have their limitations with regard to sensitivity, specificity, or applicability. None surpasses fecal examination, so this is the most commonly used method. In the field, however, fecal examination is becoming more and more difficult since people are tending to cooperate less. At present, clonorchiasis is incidentally diagnosed during sonographic scanning of the abdomen for routine check or for other purposes. Sonographic picture of diffuse dilatation of the small intrahepatic bile ducts with no or minimal dilatation of the large intrahepatic and extrahepatic bile ducts is regarded as the pathognomonic finding of clonorchiasis (Lim *et al.*, 1989; Hong *et al.*, 1994). In diagnosis of clonorchiasis, however, the sensitivity and specificity of sonography have not yet been accurately determined.

It is expected that continuous and repeated treatment should be excellent for mass control of clonorchiasis but no data have proven it. In the present study, we tried to control clonorchiasis by repeated praziquantel treatment with 6 months interval and to evaluate the efficacy of sonography for diagnosis of clonorchiasis in the field before and after treatment.

MATERIALS AND METHODS

Areas chosen for the study

A village in Koesan-gun, Chungchongbuk-do

was chosen as an endemic focus of clonorchiasis. For comparison, a village in Pyongchang-gun, Kangwon-do, was chosen as a non-endemic focus. The study ran from July 1994 to January 1998. Residents of the Koesan-gun village underwent fecal examination and sonography every six months, and egg positive cases were treated with praziquantel (Distocide® , Shinpoong Pharmaceutical Co., Korea) 25 mg/kg, three times in a day.

Fecal examination

One specimen of feces was collected from the residents of the villages and examined once by cellophane thick smear (CTS) technique. To roughly estimate the intensity of infection, the number of *C. sinensis* eggs on a smear was counted. Residents of the endemic village were reexamined randomly every six months.

Sonography

A sonography scanner (Logic 500, GE, Milwaukee, USA) was rented from the Samsung GE Medical System, Seoul, Korea and set up in the villages. The subjected residents were scanned with a 3.5 MHz transducer by an experienced radiologist. As previously mentioned (Lim *et al.*, 1989; Hong *et al.*, 1994), visualization of the intrahepatic bile duct was regarded as positive. The sonography was done every 6 months at the 2 villages and some of treated cases were reexamined.

RESULTS

Fecal examination and egg-positive rate during the follow-up period

In July 1994, at the beginning of the study, the positive rate of *C. sinensis* eggs in the endemic village in Koesan-gun was 22.7%. All of the detected egg positive cases were treated with praziquantel and also educated for clonorchiasis. All of the residents in the village were subjected for fecal examination repeatedly every six months but actually some of them were randomly missed. The egg positive rate decreased to 19.6% in January 1995, 15.1% in July 1995, 12.2% in January 1996,

6.3% in July 1996, 11.4% in January 1997, and 6.3% in January 1998 (Table 1). In all of the positive cases, EPG (number of eggs per gram of feces) counted as less than 200. In the non-endemic village in Pyongchang-gun, 64 subjects were examined but none was positive for *C. sinensis* eggs (Table 2).

Sonography

As presented in Figure 1, the sonography which showed the peripheral intrahepatic ducts was regarded as positive. On this basis, 61 (49.6%) of 123 residents, who were included more than once by both fecal examination and sonography in Koesan-gun village, were sonography-positive. Of the 123 residents, 23 were egg-positive and 100 were egg-negative. Twelve of 23 egg-positive cases (sensitivity, 52.2%) were sonography-positive and 51 of 100 egg-negative cases (specificity, 51%) were sonography-negative (Table 3).

In the non-endemic village in Pyongchang-gun, 20 of 64 subjects examined (31.3%) were sonography-positive (Table 2). This result of false-positive sonography reflects the frequency of non-specific visualization of intrahepatic bile ducts in a rural area of Korea.

Table 1. Egg positive rates during selective chemotherapy every six months in an endemic village in Koesan-gun, Korea

Date of exam.	No. of exam.	No. (%) of positive
Jul. 1994	44	10 (22.7)
Jan. 1995	51	10 (19.6)
Jul. 1995	86	13 (15.1)
Jan. 1996	82	10 (12.2)
Jul. 1996	32	2 (6.3)
Jan. 1997	79	9 (11.4)
Jan. 1998	79	5 (6.3)

Table 2. Findings of fecal examination and sonography for diagnosis of clonorchiasis in a non-endemic village in Pyongchang-gun, Korea

Methods of exam.	No. of exam.	No. (%) of positive findings
Fecal examination	64	0 (0.0)
Sonography	64	20 (31.3)

Table 3. Number of clonorchiasis cases by fecal examination and sonography in an endemic village in Koesan-gun

No. of cases by fecal exam.	No. of cases by sonography		
	Positive	Negative	Total
Egg positive	12	11	23
Egg negative	49	51	100
Total	61	62	123

Table 4. Number of clonorchiasis cases found by sonography among egg-negative converters in an endemic village in Koesan-gun

Months after cure	No. of cases examined	No. (%) of sonography-positive
6	14	9 (64.3)
12	12	6 (50.0)
18	6	3 (50.0)
24	3	2 (66.7)

Table 4 shows changes in sonographic findings among cured clonorchiasis subjects by treatment. After 6 months of cure, nine of 14 (64.3%) were positive; half were still positive after 12 or 18 months, and two-thirds were positive after 24 months. Twenty of 35 subjects (57.1%) remained sonography-positive after being cured by praziquantel.

DISCUSSION

Since freshwater fish is the vehicle of human infection, endemic areas of clonorchiasis are scattered along rivers or reservoirs throughout the country. In Korea, the endemic areas are found along the middle or lower reaches of major rivers but the disease is rare in the upper reaches, where the snail intermediate host of *C. sinensis* is absent (Seo *et al.*, 1981). The endemic focus of the present study, a village in Koesan-gun, is in the middle reaches of the Hangang (River) and the non-endemic focus, a village in Pyongchang-gun, is in the upper reaches of this same river. In Koesan-gun, the egg positive rate was initially 22.7% and at the end of the follow-up period was 6.3%, which is still far higher than 1.4% recorded for the whole country in 1997

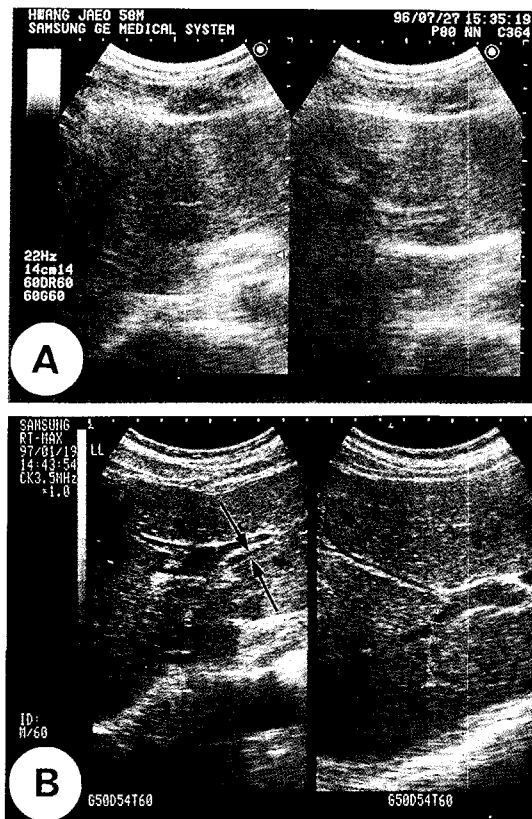


Fig. 1. Sonographic images of the liver. **A.** A normal resident with negative findings. **B.** An infected resident showing the intrahepatic bile duct (arrows).

(Ministry of Health and Welfare, 1997). Even though the intensity of infection was less than EPG 200, the present result is unsatisfactory and this control method is inefficient. This may be because such field work is labor intensive, and residents involved in the study are extremely reluctant to change their eating habits. Due to this habit, most of those who have been cured are reinfected and this is mainly why the control of clonorchiasis in Korea is inefficient. In addition, treatment failure due to incomplete or inadequate administration of praziquantel may partly be involved in this low efficiency.

Detectability of *C. sinensis* eggs by fecal examination of one CTS smear was shown by Chai *et al.* (1982) to be 44.7%, though this detection rate differs according to the intensity of infection of the subjects involved. If the intensity is low, the detection rate is substan-

tially reduced. Because of the introduction of praziquantel, most clonorchiasis cases in Korea now involve light infection, and diagnosis can thus be problematic (Ministry of Health and Welfare, 1997). In the present study, all egg positive cases in the endemic village were lightly infected, and this should be borne in mind. In the lightly infected group, the sensitivity of ELISA diagnosis is also known to be low (Hong, 1988).

Lim *et al.* (1989) recorded that the diagnosis of clonorchiasis by sonography was efficient by verifying diffuse dilatation of the intrahepatic bile ducts or thickening of the ductal wall during abdominal sonographic scanning. In the present study, sonographic diagnosis was less sensitive and also less specific than fecal examination. Its sensitivity was 52.2% and specificity was 51%.

In the endemic village in Koesan-gun, a total of 123 residents were scanned more than once, and in 61 (49.6%) the result was positive; only 12 (19.7%) of these, however, were found egg-positive and 49 (80.3%) were egg-negative. This low sensitivity and specificity of sonographic scanning may be an outcome of the light intensity of infection among the population examined; heavier infection might have resulted in higher sensitivity and specificity. Cases in which the result of sonography was false-negative might include light infection of one or two worms, and detection of these cases by any kind of method even including fecal examination is hard. In addition, most of egg positive residents who had fatty liver were found false-negative due to the increased background echogenicity from the fatty tissue.

The sonography also showed a false-positive result in 49 cases, which might have been due to visualization of the normal bile ducts, cured but scarred ducts or bile duct pathology resulting from other diseases. This high false-positive rate was partly contributed by slender residents. The sonographs of slender ones were so well visualized that the small normal intrahepatic bile ducts could be easily identified to have been regarded as false-positive. Even in the non-endemic village in Pyongchang-gun, the intrahepatic bile ducts were visualized in 31.3% of the 64 scanned

residents. The present frequency of sonographic visualization of the ducts indicates that the criteria for sonographic diagnosis of clonorchiasis should be amended (Lim *et al.*, 1989). Any sonographic feature which can specify mucosal hyperplasia would be necessary for the diagnosis.

Sonographic follow-up data of cured cases did not reveal decreased positivity after praziquantel treatment. Six to 24 months later, sonography still visualized dilated bile ducts in egg negative converters (cured cases). The sonographic positive rate was 52.2% before treatment but 64.3%, 50%, 50%, and 66.7% among cured cases 6, 12, 18, and 24 months after treatment, respectively. Total 20 of 35 cured cases (57.1%) were sonographic positive. This result demonstrates that for the differentiation of cured clonorchiasis, sonography is less useful. An animal experiment suggested the possibility of residual positive sonographic findings after treatment (Hong *et al.*, 1994). Since abdominal sonography reflects not the worm but pathological changes in the bile duct (Lim *et al.*, 1989) and the changes were found pathologically irreversible even after cure by praziquantel treatment (Lee *et al.*, 1987), the sonographic differentiation has been expected hard. The present study confirmed that the sonographic finding of infected bile ducts remained for more than two years after treatment.

ACKNOWLEDGEMENT

We thank student members of the Songchon Medical Association and Medical Frontier Club (MFC), Seoul National University College of Medicine, for their help in the field.

REFERENCES

- Chai JY, Yang YT, Lee SH, Seo BS (1982) The detectability of helminth eggs from feces by cellophane thick smear technique. *Korean J Parasitol* **20**(1): 14-20.
- Chen M, Lu Y, Hua X, Mott KE (1994) Progress in assessment of morbidity due to *Clonorchis sinensis* infection: a review of recent literature. *Trop Dis Bull* **91**: R7-R67.
- Hong ST (1988) Changes of anti-*Clonorchis sinensis* IgG antibody in serum after praziquantel treatment in human clonorchiasis. *Korean J Parasitol* **26**(1): 1-8.
- Hong ST, Park KH, Seo M, Choi BI, Chai JY, Lee SH (1994) Correlation of sonographic findings with histopathological changes of the bile ducts in rabbits infected with *Clonorchis sinensis*. *Korean J Parasitol* **32**(4): 223-230.
- Lee SH, Hong ST, Kim CS, Sohn WM, Chai JY, Lee YS (1987) Histopathological changes of the liver after praziquantel treatment in *Clonorchis sinensis* infected rabbits. *Korean J Parasitol* **25**(2): 110-122.
- Lee SH, Shim TS, Lee SM, Chi JG (1978) Studies on pathological changes of the liver in albino rats infected with *Clonorchis sinensis*. *Korean J Parasitol* **16**(2): 148-155.
- Li BZ, Wang YY, Zhao YY, Zhao YN (1997) *Clonorchis sinensis* and clonorchiasis. Shenyang Publ Co., Shenyang, China.
- Lim JH, Ko YT, Lee DH, Kim SY (1989) Clonorchiasis: Sonographic findings in 59 proved cases. *Am J Roentgenol* **152**: 761-764.
- Ministry of Health and Welfare and Korea Association of Health (1997) Prevalence of intestinal parasitic infections in Korea — The Sixth Report. Seoul, Korea.
- Rim HJ (1986) The current pathobiology and chemotherapy of clonorchiasis. *Korean J Parasitol* **24**(suppl): 5-141.
- Rim HJ (1990) Clonorchiasis in Korea. *Korean J Parasitol* **28**(suppl): 63-78.
- Seo BS, Lee SH, Cho SY, *et al.* (1981) An epidemiological study on clonorchiasis and metagonimiasis in riverside area in Korea. *Korean J Parasitol* **19**(2): 137-150.

초록=

반복 집단 치료에 의한 간흡충증의 관리 및 진단에서 초음파검사의 저효용성

홍성태¹⁾, 윤기성¹⁾, 이미정¹⁾, 서민¹⁾, 최민호¹⁾, 심정석⁴⁾, 최병인²⁾, 윤종구³⁾, 이순형¹⁾

서울대학교 의과대학 기생충학교실 및 감염병연구소¹⁾, 방사선과학교실²⁾, 소아과학교실³⁾
및 부천세종병원 방사선과⁴⁾

간흡충은 현재 국내에서 가장 총란양성률이 높은 인체기생충으로 우수한 구충효과를 보이는 국산 프라지관텔이 사용되고 있음에도 여전히 유행도가 높아 관리대책이 필요하다. 이 연구는 간흡충이 유행하는 한 마을에서 총란양성자를 6개월 간격으로 반복 검사 및 투약하면서 관리효과를 파악하고 간흡충증의 진단에서 복부초음파검사의 유용성을 검토하였다. 충북 괴산군의 한 마을에서 총란양성률이 처음 22.7%이었으나, 치료를 반복하면서 6개월 후에 19.6%, 12개월 후에 15.1%, 18개월 후에 12.2%, 24개월 후에 6.3%, 30개월 후에 11.4%, 42개월 후에 6.3%를 나타내었다. 한 번 이상 초음파 검사와 검변에 참여한 피검사자 총 123명 중에서 61명 (49.6%) 이 간내 담관이 관찰되어 양성소견을 보였으나, 이들 중에서 총란양성률은 18.7% (23/123)이었다. 총란양성자 중에서 52.5%, 총란음성자 중에서 49%가 초음파 양성소견을 보여 총란양성 여부와 초음파 양성소견은 관련성이 없었다. 또한 치료 후에 초음파로 검사한 결과 치료 후 6개월 64.3%, 12개월 50%, 18개월 50%, 24개월 66.7%의 초음파 양성소견을 보였다. 비유행지에서 주민 64명의 총란음성자를 대상으로 초음파로 검사한 결과 20 (31.3%)명이 양성으로 관찰되었다. 이 연구의 결과에 의하면 6개월 간격으로 총란양성자를 3년 6개월간 지속적으로 투약하여도 간흡충증의 집단관리가 충분하지 못하며, 초음파검사는 유용성이 낮은 진단법임을 확인하였다.

[기생충학잡지 36(4): 249-254, 1998년 12월]