

## Presurgical Naso-Alveolar Molding Appliance for Unilateral Cleft Lip and Palate

Seung-Hak Baek<sup>1)</sup>, Won-Sik Yang<sup>2)</sup>, Sukwha Kim<sup>3)</sup>

The goals of this study were to present presurgical naso-alveolar molding (PNAM) appliance in unilateral cleft lip and palate treatment and to evaluate the effects of PNAME appliance on alveolar molding. Samples were consisted of 4 unilateral cleft lip and palate infants (3 males and 1 female, mean age=23.2 days after birth) who were treated with PNAME appliances in Department of Orthodontics, Seoul National University Dental Hospital. Average alveolar cleft gap between the greater and lesser segment was 8.27 mm and average duration of alveolar molding treatment was 9.7 weeks. These patients' models were obtained at initial visit (T1) and after successful alveolar molding (T2). Seven linear and five angular variables were measured by using photometry and digital caliper. All statistical analyses were performed by SPSS win ver. 7.5 program. Paired t-test was used to compare the mean values.

1. The posterior part of alveolar segments are the stable structures during alveolar molding treatment period in infants.
2. Forward growth of the greater segment may be hindered by the action of alveolar molding.
3. The closure of cleft gap during alveolar molding were usually due to inward and backward bending of the anterior part of the greater segment and outward bending of the whole lesser segment.

**Key Words** : Unilateral cleft lip and palate, Presurgical naso-alveolar molding appliance

Although there were a lot of advances in the field of cleft surgery<sup>4,13,19,20,22,23,28,34,35)</sup>, surgical repair alone can not solve the multiple problems encountered in patients with cleft lip and palate. If there are large amount of cleft gap and soft tissue flap from the surface of the maxilla, the surgically repaired lip and palate heals under maximum tension and eventually forms scar tissue<sup>2,38)</sup>. The excessive scar tissue functions as the most powerful and uncontrolled molding force that may haphazardly results in collapse of

the alveolar segments<sup>8)</sup>. So the presurgical molding guidance of alveolar segments is necessary to prevent such problems.

The concept of modern presurgical infant orthopedics (PSIO) started with the work of McNeil<sup>21)</sup>. He constructed plates from a series of modified plaster models in which the displacement of the palatal cleft segment was gradually reduced. By using successive plates, he could gradually close alveolar and hard palatal cleft gap. But he went so far as to claim - without having examined serial casts to support his statement - that the "stimulating growth" plate would eliminate almost all palatal clefts prior to palatal surgery. He even believed that alveolar and palatal surgery could be avoided completely, implying that a soft tissue and even a bony continuity could be

<sup>1)</sup> Full-time clinical instructor, Department of Orthodontics, College of Dentistry, Seoul National University

<sup>2)</sup> Professor, Department of Orthodontics, College of Dentistry, Seoul National University

<sup>3)</sup> Associate Professor, Department of Plastic Surgery, College of Medicine, Seoul National University

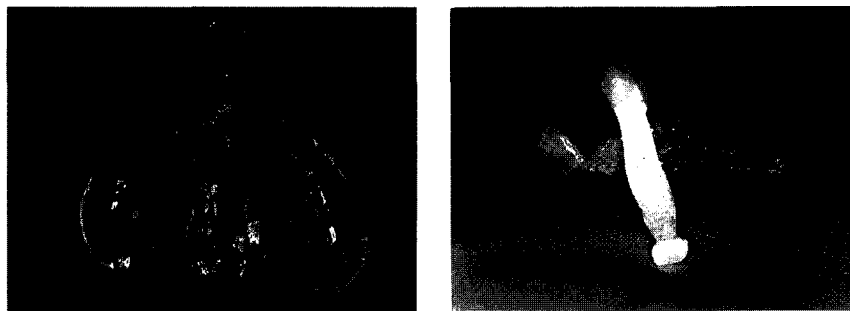


Fig. 1. The nasoalveolar molding plate with nasal stent for unilateral cleft lip and palate.

achieved. He also stated that his technique could eliminate the need for future orthodontic treatment.

But McNeil's exaggerated claims damaged the credibility of his technique<sup>11)</sup> and controversy has surrounded the subject ever since. Pruzansky<sup>27)</sup> and Berkowitz<sup>3)</sup> believed that spontaneous retropositioning of the premaxilla followed lip repair, obviating the need for intervention with infant orthopedic devices.

Despite the controversy in the literature<sup>29,31,32)</sup>, the presurgical infant orthopedics continues to be widely used<sup>1,10)</sup>. And many variations in PSIO techniques have evolved during the last 40 years<sup>6,12,14,25,30)</sup>.

PSIO techniques have several advantages as follows:

1. would establish normal tongue position, aiding speech development
2. aid in feeding
3. help surgeon in uniting the lip and closing the floor of the nose
4. be a psychological help to the parents
5. stimulate palatal bone growth
6. reduce middle ear infections
7. prevent the collapse of palatal segments, thereby reducing the need for future complex orthodontic treatment.

But the traditional PSIO techniques and skin paradigm have several problems. They are molding only alveolar segments and do not consider about nonsurgical lengthening of short columella of patients with cleft lip and palate. And deformity of the nasal tip cartilage remained uncorrected or was made worse in these techniques. So a new combined technique and

paradigm for nasal and alveolar molding is necessary. The nasal cartilage molding paradigm takes advantage of the high degree of plasticity and the lack of elasticity in neonatal cartilage in the newborn infant. This fact is due to the increased levels of maternal estrogen and hyaluronic acid of cartilage in neonate immediately after birth<sup>9,15)</sup>. Active cartilage molding therapy is most successful during first 2 to 3 months after birth because the period of plasticity is slowly lost. This naso-alveolar molding is currently employed in managing infants with unilateral and bilateral cleft lip, alveolus, and palate before operation<sup>16,17,18,26,35)</sup>.

Now Department of Orthodontics, Seoul National University Dental Hospital uses the naso-alveolar molding technique which has been currently developed by the Cleft Palate team of the Institute of Reconstructive Plastic Surgery at NYU Medical Center<sup>5,8)</sup>. And it has a positive influence on the outcome of the primary nasal, labial, and alveolar repair.

There are a few papers about presurgical infant orthopedics of cleft lip and palate because of measuring limitations and difficulties in gathering infantile cleft cases. So the goals of this study were 1) to present presurgical naso-alveolar molding (PNAM) appliance in unilateral cleft lip and palate treatment and 2) to evaluate the effects of PNAM appliance on alveolar molding.

The presurgical naso-alveolar molding (PNAM) appliance

The goals of the PNAM appliance therapy in unilateral cleft lip and palate are (1) to align the alveolar

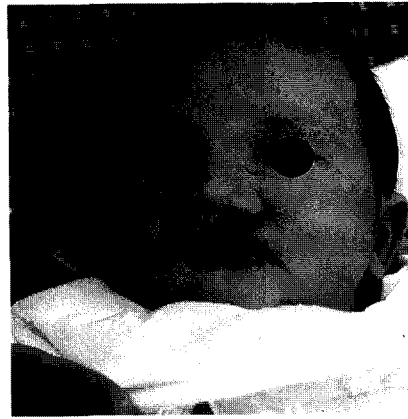
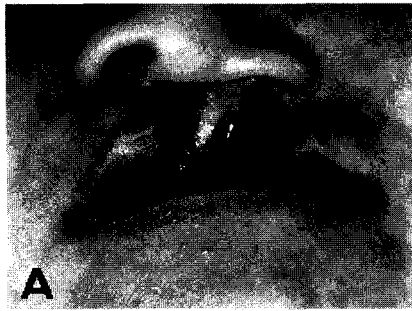

Fig. 2. The unilateral cleft lip and palate, and nose.

A : In the unilateral cleft, the ipsilateral lower nasal cartilage is depressed and concave, and separated from the contralateral nasal cartilage located high in the nasal tip. Note the difference of vertical position of ala base between right and left ala. There are wide nostril with low apex, increased alar rim length and deficient columella in the cleft side. And deviation of nostril septum shifts base of nose to the noncleft side.

B : Initial facial and intraoral photo

segments and achieve closure of the alveolar gap, and (2) to correct the malposition of the nasal cartilages in the affected side, as well as (3) to idealize the position of the philtrum and columella.

The presurgical naso-alveolar molding (PNAM) appliance is composed of alveolar molding plate and asal stent (Fig. 1).

The alveolar molding plate is made of a hard clear acrylic resin which cover the palate and the alveolar processes. But it does not extend into the nasal cavity and soft palate area. By gradual addition of soft pink acrylic resin and removal of hard acrylic resin, the alveolar segments are gently pressed to grow and mold into the desired shape and position.

The nasal stent is built from the labial vestibular flange of the acrylic alveolar molding plate and extended into nostril when the alveolar segments are nearly approximated. It resembles the swan neck. It provides support and gives shapes to the dome and alar cartilages of the nose. Through gradual modifications of the nasal stent the shapes of the nostrils and alar rims are carefully molded to the normal configuration.

This patient is 3 week-old male baby and has complete unilateral cleft lip and palate of left side. In

unilateral cleft, the ipsilateral affected lower lateral nasal cartilage is depressed and concave, and separated from the contralateral nasal cartilage. This results in depression and displacement of the nasal tip to the cleft side and is associated with overhang of the ipsilateral nostril apex. The columella and nasal septum are inclined over the cleft with the base deviated toward the noncleft side. In addition, the orbicularis oris muscle in the lateral lip element contracts into a bulge with some fibers running along the cleft margin toward the nasal tip(Fig. 2).

After the clinical examination of cleft infant, an impression of the intraoral cleft defect was made using an elastomeric material in an acrylic individual tray (Fig. 3-A). The alveolar molding plate is constructed on the maxillary study model from clear orthodontic hard acrylic resin(Fig. 3-B,C). The alveolar molding plate is delivered and modified at weekly intervals to gradually approximate the alveolar segments(Fig. 4-A,B). This is achieved through the selective removal of acrylic from the region into which one desires the alveolar bone to grow. At the same time, soft resin is added to line the plate in the region from which one desires the bone to be moved. The nasal changes are

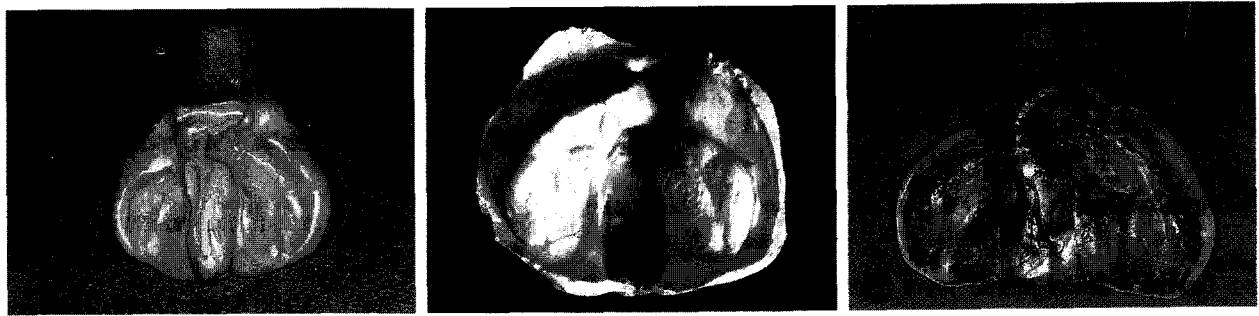

Fig. 3. A : Impression with acrylic individual tray, B : Working model, C : Initial alveolar molding plate

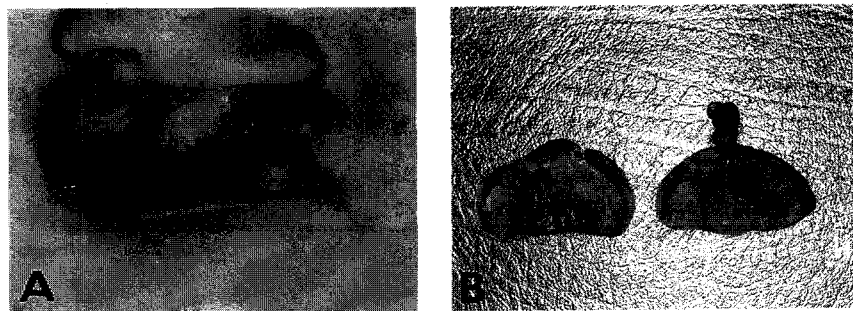


Fig. 4. A : The unilateral alveolar molding plate in place  
 B : Weekly modifications of the unilateral alveolar molding plate gradually correct alveolar arch asymmetry while closing the alveolar cleft gap.

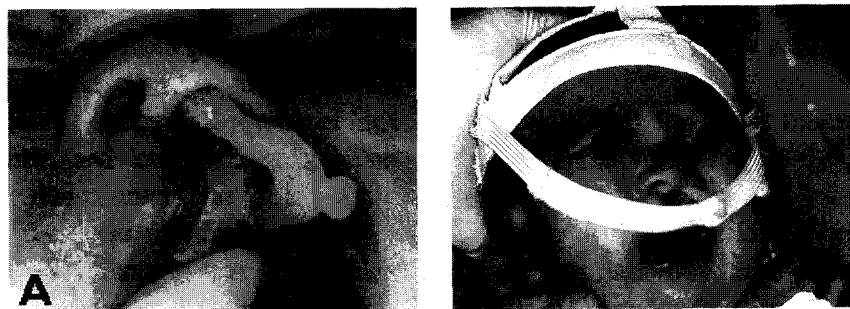


Fig. 5. A : The unilateral alveolar molding plate with nasal stent in place. Note the action of the nasal stent to correct nasal cartilage from while the oral portion of the molding plate corrects the alveolar deformity.  
 B : The appliance is maintained against the palate by using head cap and elastic band, and by taping applied to the prolabium.

achieved by the use of a nasal stent. The nasal stent advance the lateral alar cartilages into the nasal tip and provide stretch to the columellar skin. The medio-lateral position of the nasal stent is adjusted as it lifts the nasal tip. The shape of the nostrils and alar rims

is carefully molded to resemble the normal configuration of these structures through modifications gradually made to the nasal stent(Fig. 5-A).

The effectiveness of this appliance is enhanced by using head cap and elastic band, and by taping the left

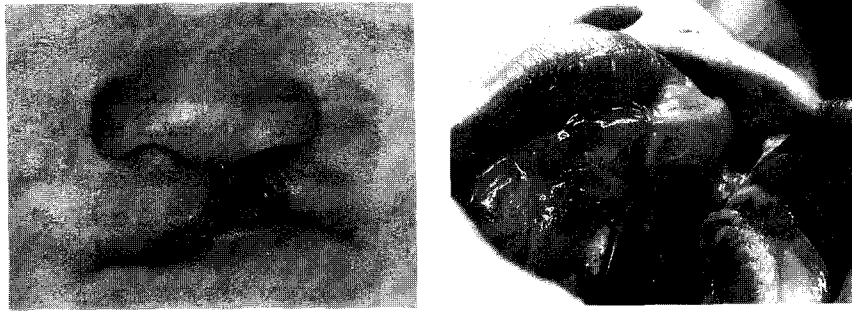


Fig. 6. Pre-op. facial and intraoral photo : Repositioning of the alveolar segments, lip, and nose was achieved.

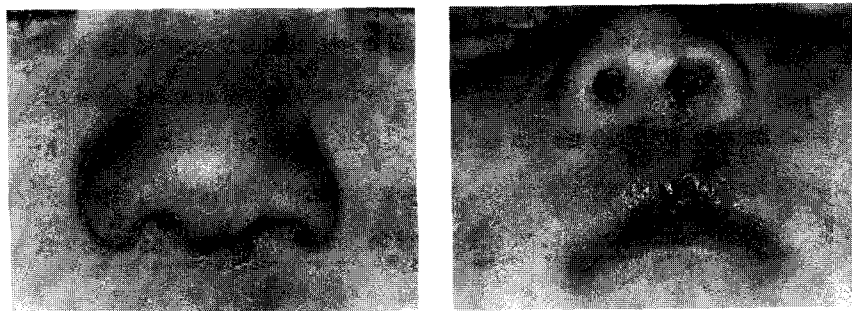

Fig. 7. Post-op. 10 days facial and intraoral photo : Good lip and nose repair.

Presurgical naso-alveolar molding appliance helps optimal surgical restoration

and right upper lip segments together between clinical visits(Fig. 5-B). The combined action of the naso-alveolar molding plate and nonsurgical approximation of lip segments with tape results in a controlled correction of the alveolar, nasal cartilage and soft tissue deformity.

After 12 weeks at the conclusion of nasal and alveolar molding, the nasal cartilages, columella, philtrum, and alveolar processes were aligned to permit surgical restoration of normal anatomic relationships (Fig. 6). The primary lip-nose repair is performed at age 4 months(Fig. 7). Gingivoperiosteoplasty<sup>24)</sup> to close the alveolar cleft can be performed at the same time. This allows one surgical procedure to address the defects of the nasolabial complex in coordination with correction of the alveolar deformity. But in this patient we did not perform gingivoperiosteoplasty because of slight end to end relationship between upper and lower anterior alveolar ridge.

## MATERIALS AND METHODS

Samples were consisted of 4 unilateral cleft lip and palate infants (3 males and 1 female) who were treated with PNAM appliances in Department of Orthodontics, Seoul National University Dental Hospital. Their age at initial visit ranged from 10 days to 47 days after birth (mean age : 23.2 days after birth). Average alveolar cleft gap between the greater and the lesser segment was 8.27 mm (Table 3) and average duration of alveolar molding treatment was 9.7 weeks. These patients' models were obtained at initial visit (T1) and after successful alveolar molding (T2) (Fig. 8). But you should not over-retract maxillary segments or you will make anterior edge bite or cross bite iatrogenically.

Table 1 summarizes the reference points and lines. Twelve variables were described in Table 2 and the data were derived by one to one scale using photometry and digital caliper. The authors underwent preliminary statistic study on the effect of PNAM in alveolar

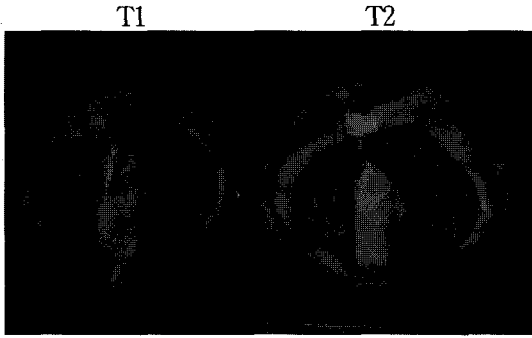


Fig. 8. Patients' models were obtained at initial visit (T1) and after successful alveolar molding (T2)

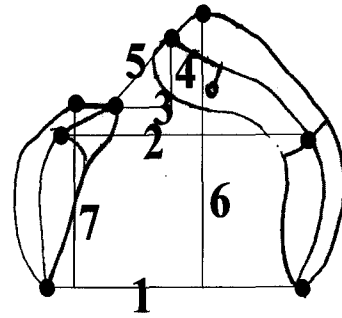


Fig. 10. Linear measurement variables

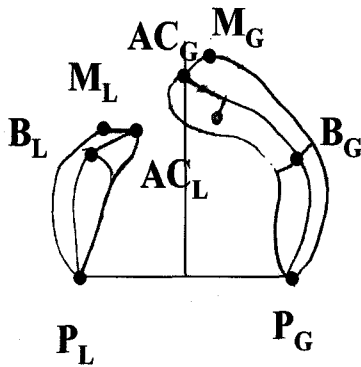


Fig. 9. Reference points and lines

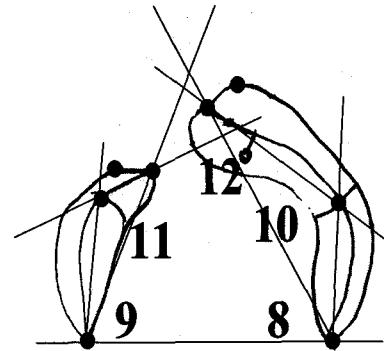


Fig. 11. Angular measurement variables

molding. All statistical analyses were performed by SPSS win ver. 7.5 program. Paired t-test was used to compare the mean values (Table 3).

**RESULTS**

There were no statistically significant differences in  $P_G-P_L$  and  $B_G-B_L$  between T1 and T2 (Table 3). But the amount of alveolar cleft gap was significantly reduced in the anteroposterior distance and the shortest distance in  $AC_G-AC_L$  rather than the transverse distance in  $AC_G-AC_L$  after treatment (Table 3). There were no statistically significant differences in the longitudinal length of  $M_L-P_L$  and  $M_G-P_G$  between T1 and T2 (Table 3).

The value of  $AC_L-B_L-P_L$  was unchanged during treatment but the value of  $AC_G-B_G-P_G$  decreased significantly after treatment. Although there was no statistically significant difference in the value of  $(AC_L-P_L)-(P_G-P_L)$  between T1 and T2, this variable was increased after alveolar molding. And the post-treatment value of  $(AC_G-P_G)-(P_G-P_L)$  was decreased slightly without statistically significant difference between T1 and T2. The value of  $(B_G-AC_G)-(B_L-AC_L)$  was slightly increased after treatment

**DISCUSSION**

There were no statistically significant differences in  $P_G-P_L$  and  $B_G-B_L$  between T1 and T2 (Table 3). It

Table 1. Reference points and lines

1. $P_G$	: Postgingivale in the greater segment. It is the most posterior point of alveolar crest in the greater segment
2. $P_L$	: Postgingivale in the lesser segment. It is the most posterior point of alveolar crest in the lesser segment
3. $AC_G$	: The most anterior point of the alveolar crest in the greater segment.
4. $AC_L$	: The most anterior point of the alveolar crest in the lesser segment.
5. $B_G$	: Buccal frenum point of the alveolar crest in the greater segment
6. $B_L$	: Buccal frenum point of the alveolar crest in the lesser segment
7. $M_G$	: The most anterior point of the greater segment.
8. $M_L$	: The most anterior point of the lesser segment.
9. $P_G$ - $P_L$ line	: Horizontal reference line
10. Sagittal line	: The perpendicular line to the $P_G$ - $P_L$ line. It crossed midpoint between $P_G$ in the greater segment and $P_L$ in the lesser segment

Table 2. Variables

Linear measurement	
1. $P_G - P_L$	: The distance between P in the greater segment - P in the lesser segment
2. $B_G - B_L$	: The distance between B in the greater segment - B in the lesser segment
3. trans. $AC_G - AC_L$	: The transverse distance between AC in the greater segment - AC in the lesser segment
4. A-P. $AC_G - AC_L$	: The anteroposterior distance between AC in the greater segment - AC in the lesser segment
5. dis. $AC_G - AC_L$	: The shortest distance between AC in the greater segment - AC in the lesser segment
6. $M_G - P_G$	: Longitudinal length of the greater segment from $P_G$ - $P_L$ .
7. $M_L - P_L$	: Longitudinal length of the lesser segment from $P_G$ - $P_L$ .
Angular measurement	
8. $(AC_G-P_G)-(P_G-P_L)$	: The angle between $AC_G$ - $P_G$ and $P_G$ - $P_L$ in the greater segment
9. $(AC_L-P_L)-(P_G-P_L)$	: The angle between $AC_L$ - $P_L$ and $P_G$ - $P_L$ in the lesser segment
10. $AC_G - B_G - P_G$	: The angle between $AC_G$ , $B_G$ , and $P_G$ in the greater segment
11. $AC_L - B_L - P_L$	: The angle between $AC_L$ , $B_L$ , and $P_L$ in the lesser segment
12. $(B_G - AC_G) - (B_L - AC_L)$	: The angle between $B_G - AC_G$ in the greater segment and $B_L - AC_L$ in the lesser segment

means that the posterior parts of alveolar segments are the stable structures during alveolar molding treatment period in infants.

The normal palatal arch form is determined by the resultant of the compressive forces of the orbicularis oris - buccinator - superior constrictor pharyngeal muscle ring which are counteracted by the protrusive and expansive forces of the tongue. Because of the lateral pulls of the cleft lip musculatures which are coupled with the pushing forces of the tongue fitting within the cleft space, the greater and the lesser alveolar segments are distorted to the lateral side. So

the authors thought that the reduction of the horizontal distance in  $AC_G-AC_L$  was more difficult than reduction of the longitudinal distance and the shortest distance in  $AC_G-AC_L$  after treatment (Table 3).

Although there was no statistically significant difference in  $M_L-P_L$  between T1 and T2, it showed that the longitudinal length of the lesser segment was slightly increased in the anterior direction.

There must be occurred same amount of anterior growth in the greater segment. On the contrary there was slight reduction in  $M_G-P_G$  after treatment. It means that forward growth of the greater segment was

**Table 3.** Effect of presurgical naso-alveolar molding appliance

measurements	pretreatment(T1) (mean $\pm$ sd)	posttreatment(T2) (mean $\pm$ sd)	significance
P <sub>G</sub> -P <sub>L</sub>	34.59 $\pm$ 2.36	34.34 $\pm$ 2.02	n.s.
B <sub>G</sub> -B <sub>L</sub>	31.14 $\pm$ 1.51	31.72 $\pm$ 2.19	n.s.
trans. AC <sub>G</sub> -AC <sub>L</sub>	5.80 $\pm$ 3.04	4.05 $\pm$ 2.92	n.s.
A-P AC <sub>G</sub> -AC <sub>L</sub>	6.02 $\pm$ 1.12	1.88 $\pm$ 1.25	*
dis. AC <sub>G</sub> -AC <sub>L</sub>	8.27 $\pm$ 2.94	4.57 $\pm$ 2.65	*
M <sub>G</sub> -P <sub>G</sub>	28.39 $\pm$ 0.84	27.67 $\pm$ 3.42	n.s.
M <sub>L</sub> -P <sub>L</sub>	19.9 $\pm$ 0.51	22.55 $\pm$ 2.51	n.s.
(AC <sub>G</sub> -P <sub>G</sub> )-(P <sub>G</sub> -P <sub>L</sub> )	54.68 $\pm$ 4.39	47.23 $\pm$ 4.29	n.s.
(AC <sub>L</sub> -P <sub>L</sub> )-(P <sub>G</sub> -P <sub>L</sub> )	62.83 $\pm$ 2.32	71.55 $\pm$ 8.64	n.s.
AC <sub>G</sub> -B <sub>G</sub> -P <sub>G</sub>	120.18 $\pm$ 7.24	109.05 $\pm$ 10.12	*
AC <sub>L</sub> -B <sub>L</sub> -P <sub>L</sub>	136.78 $\pm$ 16.39	136.63 $\pm$ 7.54	n.s.
(B <sub>G</sub> -AC <sub>G</sub> )-(B <sub>L</sub> -AC <sub>L</sub> )	116.68 $\pm$ 8.38	124.05 $\pm$ 9.59	n.s.

\* P &lt; 0.05

hindered by the action of alveolar molding.

The greater segment showed significant inward and backward bending in anterior part (AC<sub>G</sub>-B<sub>G</sub>-P<sub>G</sub>) and slight backward bending in whole part ((AC<sub>G</sub>-P<sub>G</sub>)-(P<sub>G</sub>-P<sub>L</sub>)) after treatment. The morphology of anterior part of the lesser segment (AC<sub>L</sub>-B<sub>L</sub>-P<sub>L</sub>) was not changed during treatment but the outward bending of the whole part of the lesser segment ((AC<sub>L</sub>-P<sub>L</sub>)-(P<sub>G</sub>-P<sub>L</sub>)) was occurred after treatment. Anterior angle ((B<sub>G</sub>-AC<sub>G</sub>)-(B<sub>L</sub>-AC<sub>L</sub>)) was slightly increased after treatment due to bending of the anterior part of the greater segment.

The advantages of PNAM therapy in unilateral cleft lip and palate are as follows: (1) it guides the alveolar segments into normal position before surgery and allows the surgeon to create a tension-free lip closure with minimal freeing of soft tissue from the surface of the maxilla and optimal conditions for the least scar formation, and (2) it repositions the columella from an oblique position into an upright and more midline orientation, and this results in improved nasal tip projection and alar cartilage symmetry, and (3) it enable gingivoperiosteoplasty at the time of primary lip repair and eliminate the need for secondary alveolar bone graft<sup>33,36,37</sup>. These are powerful incentives to adopt the presurgical naso-alveolar molding appliance. The

surgeons and the orthodontists must have worked together in the presurgical and surgical treatment modalities, which have significantly improved the overall outcome in patients with cleft lip and palate.

## CONCLUSION

In consideration of the linear and angular measurement between pre- and post-alveolar molding therapy, the effects of PNAM appliance on alveolar molding can be summarized as follows.

1. The posterior part of alveolar segments are the stable structures during alveolar molding treatment period in infants.
2. Forward growth of the greater segment was hindered by the action of alveolar molding.
3. The closure of cleft gap during alveolar molding were usually due to inward and backward bending of the anterior part of the greater segment and outward bending of the whole lesser segment.

Therefore this appliance can be applied to many cleft infant with satisfactory results before cheiloplasty. But sample size used in this study was so small that further study will be needed.



## REFERENCES

1. Asher-McDade, C., and Shaw, W.C. : Current cleft lip and palate management in the United Kingdom, *Br. J. Plast. Surg.* 43 : 318-321, 1990
2. Bardach, J. et al : Lip pressure changes following lip repair in infants with unilateral clefts of the lip and palate, *Plast. Reconstr. Surg.* 74 : 476-481, 1984
3. Berkowitz, S. : Cleft lip and palate - perspectives in management, Singular publishing group, Inc. p 115-164, 1996
4. Boo-Chai, K. : Primary repair of the unilateral cleft lip nose in the Oriental : A 20 year follow-up. *Plast. Reconstr. Surg.* 80 : 185-194, 1987
5. Cutting, C.B. Grayson, B.H., Brecht, L., Santiago, P., Wood, R. et al : Presurgical columella elongation and primary retrograde nasal reconstruction in one-stage bilateral cleft lip and nose repair. *Plast. Reconstr. Surg.* 101 : 630-639, 1998
6. Gnoinski, W.M. : Infant orthopedics and later orthodontic monitoring for unilateral cleft lip and palate patients in Zurich. In J. Bardach and H. L. Morris (eds), *Multidisciplinary management of Cleft lip and palate.* Philadelphia, Saunders, p 578-585, 1990.
7. Grayson, B.H., Cutting, C.B. and Wood, R. : Preoperative columella lengthening in bilateral cleft lip and palate. *Plast. Reconstr. Surg.* 92 : 1422-1423, 1993
8. Grayson, B.H., Santiago, P.E. : Presurgical orthopedics for cleft lip and palate. In S.J. Aston, R.W. Beasley, and C.H.M. Thorne, *Grabb and Smith's Plastic surgery*, 5th edition, Lippincott-Raven Publishers, Philadelphia, p 237-244, 1997
9. Hardingham, T.E. and Muir, H. : The specific interaction of hyaluronic acid with cartilage proteoglycans. *Biochem. Biophys. Acta.* 279 : 401-405, 1972
10. Hotz, M. : 22 years of experience in Cleft palate management and its consequences for treatment planning. In B. Kejrer et al. (eds), *Long-term treatment in Cleft lip and palate.* Huber, Bern, p 208, 1981.
11. Huddart, A.G. : Presurgical orthopedic treatment in unilateral Cleft lip and palate. In J. Bardach and H.L. Morris(eds), *Multidisciplinary management of Cleft lip and palate.* Philadelphia, Saunders, p 574-577, 1990.
12. Huebener, D. V. and Liu, J.R. : Advances in management of cleft lip and palate. *Clin. Plast. Surg.* 20 : 723-732, 1993
13. Johanson, B. and Ohlsson, A. : Bone grafting and dental orthopedics in primary and secondary cases of Cleft lip and palate. *Acta Chir. Scand.* 122 : 112, 1961
14. Latham R.A. : Orthopedic advancement of the cleft maxillary segment : A preliminary report. *Cleft Palate J* 17 : 227-233, 1980
15. Matsuo, K., Hirose, T., and Tonomo, T. et al : Nonsurgical correction of congenital auricular deformities in the early neonate : A preliminary report. *Plast. Reconstr. Surg.* 73 : 38-51, 1984
16. Matsuo, K., Hirose, T., Otagiri, T., et al : Repair of cleft lip with nonsurgical correction of nasal deformity in the early neonatal period. *Plast. Reconstr. Surg.* 83 : 25-31, 1989
17. Matsuo, K., Yoshimura, Y., and Sakakibara, A. : Augmentation of the nostril splint for retaining the corrected contour of the cleft lip nose. *Plast. Reconstr. Surg.* 85 : 182, 1990
18. Matsuo, K., and Hirose, T. : Preoperative nonsurgical overcorrection of cleft lip nasal deformity. *Br. J. Plast. Surg.* 44 : 5-11, 1991
19. McComb, H.K. : Primary correction of the unilateral cleft lip nasal deformity : A 10 year review. *Plast. Reconstr. Surg.* 75 : 791-799, 1985
20. McComb, H.K. and Coghlan, B.A. : Primary repair of the unilateral cleft lip nose : Completion of a longitudinal study, *Cleft palate Craniofac. J.* 33 : 23-30, 1996
21. McNeil, C.K. : Orthodontic procedures in the treatment of congenital cleft palate. *Dent. Record* 70 : 126, 1950
22. Millard, D.R. : Refinements in rotation-advancement cleft lip technique. *Plast. Reconstr. Surg.* 33 : 26, 1964
23. Millard, D.R. : *Cleft Craft. The evolution of its surgery. Bilateral and rare deformities.* Vol II. Boston : Little, Brown, 1977
24. Millard, D.R. and Latham, R.A. : Improved primary surgical and dental treatment of clefts. *Plast. Reconstr. Surg.* 86 : 856-871, 1990
25. Monroe, C.W., Griffith, B.H., and Rosenstein, S.W. : The correction and preservation of arch form in complete clefts of the palate and alveolar ridge. *Plast. Reconstr. Surg.* 41 : 108-112, 1968
26. Nakajima, T., and Yoshimura, Y. : Augmentation of the nostril splint for retaining the corrected contour of the cleft lip nose, *Plast. Reconstr. Surg.* 85 : 182-186, 1990
27. Pruzansky, S. : Pre-surgical orthopedics and bone grafting for infants with cleft lip and palate : A dissent. *Cleft palate Craniofac. J.* 1 : 164, 1964
28. Randall, P. : A lip adhesion operation in cleft lip surgery. *Plast. Reconstr. Surg.* 35 : 371, 1965
29. Robertson, N.R.E. : Facial form of patients with cleft lip and palate. The long term influence of presurgical oral orthopedics. *Br. Dent. J.* 155 : 59-61, 1983
30. Rosenstein, S.W. and Jacobson B.N. : Early maxillary

- orthopedics : sequence of events. Cleft palate J 4 : 197-204, 1967
31. Ross, R.B. : Treatment variables affecting facial growth in complete unilateral cleft lip and palate. Cleft palate Craniofac. J. 24 : 5-77, 1987
32. Ross, R.B. and MacNamara, M.C. : Effect of presurgical infant orthopedics on facial esthetics in complete bilateral cleft lip and palate. Cleft palate Craniofac. J. 31 : 68-73, 1994
33. Santiago, P.E., Grayson, B.H., Cutting, C.B., Gianoutsos, M.P. Brecht, L.E. et al : Reduced need for alveolar bone grafting by presurgical orthopedics and primary gingivoperiosteoplasty. Cleft Palate Craniofac J, 35 : 77-80, 1998
34. Sayler, K.E. : Primary correction of the unilateral cleft lip nose : A 15 year experience. Plast. Reconstr. Surg. 77 : 558, 1986
35. Sugihara, T., Yoshida, T., Igawa, H.H., et al : Primary correction of the unilateral cleft lip nose. Cleft Palate Craniofac. J. 30 : 231-236, 1993
36. Wood, R., Grayson, B.H. and Cutting, C.B. : Gingivoperiosteoplasty and growth of the midface. Surg. Forum 16 : 229, 1993
37. Wood, R., Grayson, B.H., and Cutting, C.B. : Gingivoperiosteoplasty and midfacial growth. Cleft Palate Craniofac. J. 34 : 17-20, 1997
38. Yang, W.S., Baek, S.H. : A study on the extracellular matrix in the artificially created cleft lip wound healing of rabbit fetuses. Korea J Orthod 28 : 1-16, 1998

## 국문초록

# 편측성 순구개열 신생아 환자의 술전 비치조 정형장치

서울대학교 치과대학 교정학교실\* · 서울대학교 의과대학 성형외과학교실\*\*

백승학 · 양원식\* · 김석화\*\*

본 연구의 목적은 1) 편측성 순구개열 신생아 환자에 대한 술전 비치조 정형장치(PNAM) 치료를 소개하고, 2) 이 장치의 치조골 정형 효과를 평가하는 것이다. 서울대학교병원 교정과에 내원하여 PNAM장치를 사용하여 치료받은 4명의 편측성 순구개열 호나자(남자 3명, 여자 1명, 평균 초진연령 : 23.2일)을 대상으로 하였으며, 치조골에서 대분절과 소분절 파열부간의 평균 거리는 8.27mm였고 치조골 정형치료의 평균 기간은 9.7주였다. 초진시 (T1)와 성공적인 치조골 정형술이 이루어진 시기(T2)에 이들 환자의 인상을 채득하여 모형을 제작한 후, 사진촬영과 digital caliper를 사용하여 7개의 길이항목과 5개의 각도항목을 측정하였다. SPSS win. ver 7.5 프로그램을 사용하여 통계처리하였고, 평균치의 차이를 비교하기 위하여 paired t-test를 사용하였다.

1. 신생아의 치조골 후방부는 치조골 정형술을 시행하는 동안 안정된 구조물이었다.
2. 치조골 정형술에 의하여 대분절의 전방 성장이 억제되었다.
3. 치조골 정형술에 의한 파열부의 폐쇄는 주로 대분절 전방부의 내측과 후방 굴곡 및 소분절 전체의 외측 굴곡에 의한 것이었다.

주요 단어 : 편측성 순구개열, 비치조 정형장치