

□ 증 레 □

성인 당뇨병 남자에서 발생한 Streptococcus agalactiae 폐렴 1예

순천향대학교 의과대학 내과학교실

박춘식 · 이지윤 · 우준희

= Abstract =

A Case of Streptococcus Agalactiae Pneumonia In An Adult Diabetic Man

Choonsik Park, M.D., Jee Yun Lee, M.D. and JunHee Woo, M.D.

Department of Internal Medicine, Soonchunhyang University College of Medicine, Seoul, Korea

B군 연쇄상구균(group B streptococcus or Streptococcus agalactiae)은 신생아 뇌막염과 균혈증의 원인균으로 알려져 있고, 우리나라에서는 현재까지 23예의 신생아 B군 연쇄상구균 감염 임상 증례가 보고되었다.

그러나 성인에서의 B군 연쇄상구균 분리 동정에 대한 분석은 보고되었으나, 폐렴 증례는 아직 보고된 바 없고, S. agalactiae의 penicillin에 대한 최소억제농도가 대표적 연쇄상구균인 S. pyogenes 보다 높고 동물실험 및 시험관검사에서 penicillin과 aminoglycoside을 병합사용할 경우 상승작용이 관찰되었기 때문에, 치료제로 penicillin 또는 cephalosporin 을 aminoglycoside와 병합투여하여야 하는 특징을 지니고 있다.

저자들은 74세 남자 당뇨 환자에서 B군 연쇄상구균에 의한 폐렴과 패혈증이 발생한 증례를 치험하여 보고하고자 한다.

Key Words: S. agalactiae pneumonia, Bacteremia, Adult

INTRODUCTION

Despite significant advances in obstetric and pediatric health care, Streptococcus agalactiae (Lancefield group B β -hemolytic Streptococcus, GBS) remains one of the most prevalent and devastating pathogens in peripartum women and their newborn infants¹⁻⁶. It may cause urinary tract infection, chorioamnionitis and endometritis,

bacteremia, and cesarean wound infection in the peripartum period^{7,8}. It was Pasteur who first identified microbes in the blood and lorchia of septic women. After that, in 1938 the isolation of S.agalactiae from three mortally ill women was reported, thereby implicating it as another cause of puerperal sepsis⁶. S. agalactiae is now one of the most common causes of neonatal sepsis and meningitis in the United States. However, in Korea there have been only twenty-three cases of neo-

natal meningitis and/or sepsis due to group B β -hemolytic streptococcus reported¹⁻³⁾.

Recent studies have noted other serious infections in adults, including bacteremia, pneumonia, cellulitis, osteomyelitis, meningitis, and endocarditis^{7,9,10)}.

In Korean adults no case of pneumonia due to *S. agalactiae* has been reported till now. As minimal inhibitory concentration of penicillin was reported to be higher for *S. agalactiae* than for *S. pyogenes*, minimal inhibitory concentration of penicillin for *S. agalactiae* should be tested. Herein we describe the course of a case of *S. agalactiae* pneumonia and bacteremia in a 74-year-old diabetic man, and we review the literatures.

CASE REPORT

A 74-year-old man was admitted to the hospital because of fever and pain in the right lower chest.

There was a 20-year history of hypertension and adult-onset diabetes mellitus, which was managed with sulfonylurea p.o. taken daily. And approximately 20 years ago he was managed under the diagnosis of encephalitis elsewhere. The patient had been well in other respects until seven days before entry, when he experienced the onset of fever and discomfort in the right lower chest that were accompanied with voiding difficulties.

On physical examination the patient was an obese man who appeared acutely-ill. No rash or lymphadenopathy was found. The head and neck were normal. The lungs were clear except crackles at both bases, and the heart was normal. Abdominal examination revealed slightly decreased bowel sounds; there was mild epigastric tenderness, without spasm or rebound tenderness. The liver and spleen were not felt. Rectal examination disclosed that the prostate gland was enlarged. There was no peripheral edema, clubbing, or

cyanois. Neurologic examination was negative.

The hematocrit was 42.2 percent: The white-cell count was 21,800, with 81% neutrophils, 11% lymphocytes, 3% monocytes, 5% band forms. The platelet count was 259,000 and the erythrocyte sedimentation rate 9mm/hr. The urea nitrogen was 18.2mg per 100ml, the creatinine 1.0mg per 100ml and the glucose 183mg per 100ml at fasting, 262mg per 100ml at 2hr postprandial, the sodium was 133 mEq per liter, the potassium 4.3mEq per liter, the chloride 114 mEq per liter. The total bilirubin 0.8mg per 100ml, the calcium 8.3mg per 100ml, the phosphorus 2.1mg per 100ml, and the protein 5.9g (the albumin 2.5g and the globulin 2.4g) per 100ml.

The amylase was 65 U per liter, the serum aspartate aminotransferase (ASAT, previously known as GOT) was 19.2 U per liter, the serum alanine aminotransferase (ALAT, GPT) 17.1 U per liter, the alkaline phosphatase 112 U per liter. The urine gave a + test for glucose; the sediment was normal. The results of tests for rheumatoid factor, venereal disease research laboratory, antibody to nuclear antigen, and widal test were negative.

X-ray films of the chest showed an increase in hazy pneumonic infiltration in the right lung base with the right costophrenic angle blunted (Fig 1).

The heart appeared hypertensive and mediastinum, soft tissues appeared normal. A roentgenogram of the abdomen obtained with the patient supine and upright showed mild peritoneal irritation and lumbar spondylosis. An electrocardiogram showed a normal rhythm at a rate of 84, with premature atrial contractions.

Cefuroxime, tobramycin were administered by vein, and cultures of three blood samples obtained at admission grew *S. agalactiae* sensitive to penicillin, ampicillin, oxacillin, cephalothin, resistant to gentamicin, tetracyclin. The patient was managed with antibiotics for ten days, he made an uneven recovery and was discharged to his home.

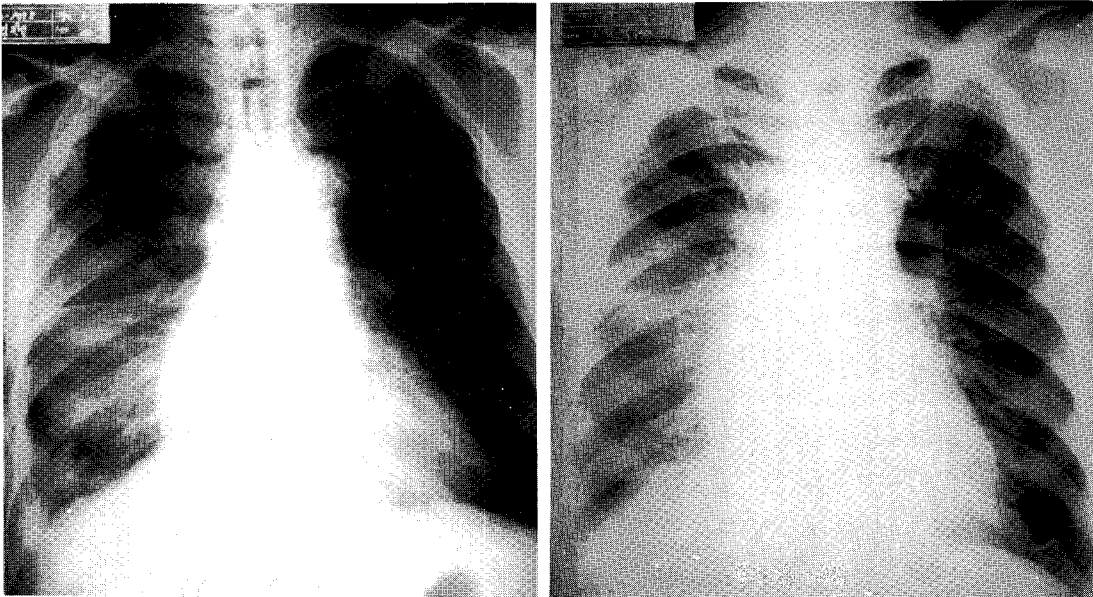


Fig 1. Photographs of X-ray films of the chest taken on admission (left) which showed an increase in haziness of right lower lung and just before discharge (right) revealed the improvement of the lesion.

DISCUSSION

S. agalactiae is now a well recognized cause of neonatal sepsis and meningitis^{7,8)}. Very rare were clinical adult cases of *S. agalactiae* infection in Korea^{2,4)}, although group B streptococcal infections in adults are being increasingly reported in occidental countries in the English literature. The spectrum of infection in adults has included urinary tract infection, postpartum infection, chorioamnionitis, endometritis, bacteremia, pneumonia, endocarditis, septic arthritis, and skin and wound infection^{4,6,11)}.

Previous reports of group B streptococcal infections in adults have alluded to a bimodal age distribution of infected patients: a young, previously healthy female population in which group B streptococcal infection occurred in association with obstetrical or gynecologic manipulations, and an older population in which this infection complicated

preexisting illnesses. The importance of the female, both as a reservoir and a susceptible population for serious group B streptococcal infections has also been stressed in earlier reports. However, Bayer et al. reported both sexes were evenly affected, suggesting that the male may be equally susceptible and may also harbor this organism in the urogenital flora^{9,10)}.

Lancefield provided some important clues to the pathogenicity of *S. agalactiae* by characterizing it extensively and demonstrating that it differs from *S. pyogenes* and other β -hemolytic streptococci by a group B-specific carbohydrate antigen on the cell wall. This antigen is recognized in commercial serologic tests. And most *S. agalactiae* strains feature a type-specific polysaccharide antigen that encapsulates these organisms. The five major capsule serotypes of GBS are Ia, Ib, Ic, II, and III. The serotype III causes most cases of early-onset meningitis and nearly all late-onset cases^{4,6)}. We did not test the serotypes.

In a recent study *S. agalactiae* was the most common β -hemolytic isolate in stool. Other surveys have documented urethral infection in men as well as pharyngeal colonization in adults. The pulmonary infections were the most frequently identified source of bacteremia and occurred in an older age group than other pneumonia, but were the second most common in the series of Bayer et al, and the isolation of *S. agalactiae* from sputum and other respiratory tract sources was less common than was its isolation from wounds or urine. In our case the primary source of bacteremia was probably the respiratory route because smears of the sputum showed polymorphonuclear leukocytes with gram-positive cocci in chain. A previous report focused on *S. agalactiae* pneumonia noted this to be a severe infection with a high incidence of mortality, generally occurring in the elderly. Isolation of *S. agalactiae* from the sputum appears to have greater clinical significance than its isolation from other sources and should prompt a careful evaluation. The urinary tract was a frequent source of *S. agalactiae*; this supports the importance of genitourinary reservoirs for the organism in men as well as women. Cutaneous lesions, such as wounds and ulcers, especially on the lower extremities, were the most common site of isolation. In other surveys such sites are uncommon as a source of bacteremia.

The frequent association of diabetes mellitus and group B streptococcal infection has been commonly noted. The type of diabetes was most often adult-onset, noninsulin dependent, although brittle, insulin dependent diabetes has also been observed¹³. Our case also had underlying diabetes. Although the presence of severe diabetic peripheral vascular disease in their adults with group B streptococcal infection was emphasized, the relationship of group B streptococcal infections to diabetes mellitus remains unexplained, but it seems

that more than a causal association exists.

S. agalactiae are facultative gram-positive diplococci that are grown easily on a variety of bacteriologic media. Isolated colonies are 3-4mm in diameter and grayish white in color when cultivated on sheep blood agar. The flat, somewhat mucoid colonies are surrounded by a narrow zone of β -hemolysis. The serologic differentiation is based on the capillary precipitin reaction between the group-specific carbohydrate antigen in the cell wall and hyperimmune antisera that is prepared by immunization of rabbits with formalin-killed whole cells⁴.

Culture of *S. agalactiae* on laboratory media from uncontaminated samples of body fluid including blood, urine, and CSF is the most accurate method for detecting the organism as a colonizer or pathogen. Serologic tests based on several immunologic techniques are available. These can be applied to CSF, urine, or blood samples. The latex particle agglutination assay (LPA) is more sensitive but less specific than counter-immunoelectrophoresis or an enzyme-linked immunosorbent assay, and in our case the LPA was used for serologic tests (Wellcome Diagnostics, Burrough, England).

S. agalactiae is a β -lactam-sensitive microbe, and penicillin is the drug of choice for treatment. But as minimal inhibitory concentration (MIC) of penicillin was reported to be higher for GBS (*S. agalactiae*) than for GAS (*S. pyogenes*)¹⁵, MIC of penicillin for *S. agalactiae* should be tested. Since penicillin or ampicillin acts synergistically with aminoglycosides in vitro and in experimental models of endocarditis, invasive *S. agalactiae* infections are usually treated with such combination¹⁶.

In the penicillin-allergic adult, a cephalosporin such as cefazolin or, in the case of prior anaphylaxis, clindamycin or vancomycin may be employed. Chloramphenicol or rifampicin may have a bacteriostatic effect that impedes bacterial killing

by other antibiotics. Therefore, these agents should not be used in combination with penicillin or ampicillin. Ceftriaxone, cefotaxime, cefuroxime have good CNS penetration, and their minimal bactericidal concentrations for group B streptococcus are comparable to those of penicillin and ampicillin. Since their efficacy is no greater, they should be reserved as alternative therapies for invasive *S. agalactiae* disease.

There are two kinds of preventive measure: one is chemoprophylaxis utilizing ampicillin and the other is immunoprevention using hyperimmune globulin or type specific polysaccharide vaccine¹⁷⁾.

In summary our case showed community acquired pneumonia and bacteremia due to *S. agalactiae* with diabetes mellitus in a Korean adult man. Respiratory tract was a characteristic source, and recovered with antibiotic management despite a high incidence of mortality.

REFERENCES

- 1) Ahn HJ, Lim JY, Oh SH, Seol IJ, Moon ST, Lee H : Clinical study of group B streptococcal infection in infants less than two months of age. *J Korean Pediatr Assoc* **35**:17, 1992
- 2) Choi YS, Chong Y, Lee SY : A study on the infection due to group B, C and G β -hemolytic streptococci. *Korean J Path* **15**:91, 1981
- 3) Sim JG, Kim SW, Hong YJ, Ahn DH, Sohn KC : Four cases of neonatal group B streptococcal sepsis/meningitis. *J Korean Pediatr Assoc* **35**:275, 1992
- 4) Chang Y, Lee K, Kwon OH, Nahm CH, Murai T, Inazumi Y: Trend of isolation and serotypes of group B streptococci in Korea. *Yonsei Med J* **34**:78, 1993
- 5) Lerner PI, Gopalakrishna KV, Wolinsky E, McHenry MC, Tan JS, Rosenthal M : Group B streptococcus (*S. agalactiae*) bacteremia in adults : Analysis of 32 cases and review of the literature. *Medicine (Baltimore)* **56**:457, 1977
- 6) Haft RF, Kasper DL : Group B streptococcus infection in mother and child. *Hosp Practice* **26**(No. 12, Dec 15):111, 1991
- 7) Gallagher PG, Watanakunakorn C : Group B streptococcal bacteremia in a community teaching hospital. *Am J Med* **78**:795, 1985
- 8) Dunne DA, Quagliarello V : Group B streptococcal meningitis in adults. *Medicine (Baltimore)* **72**:1, 1993
- 9) Bayer AS, Chow AW, Anthony BF, Guze LB : Serious infections in adults due to group B streptococci : Clinical and serotypic characterization. *Am J Med* **61**:498, 1976
- 10) Verghese A, Mireault K, Arbeit RD : Group B streptococcal bacteremia in men. *Rev Infect Dis* **8**:912, 1986
- 11) Eykyn SJ, Young SEJ, Cookson BD : Increased community-acquired septicaemic infection with group B streptococci in adults. *Lancet* **338**:446, 1991
- 12) Verghese A, Berk SL, Boelen LJ, Smith JK : Group B streptococcal pneumonia in the elderly. *Arch Intern Med* **142**:1642, 1982
- 13) Casey JI, Maturio S, Albin J, Edberg SC : Comparison of carriage rates of group B streptococci in diabetic and nondiabetic persons. *Am J Epidemiol* **116**:704, 1982
- 14) Edwards MS, Baker CJ : Chapter 180. Streptococcus agalactiae (Group B Streptococcus). In Mandell GL et al(eds) *Principles and practice of Infectious Diseases*, 3rd ed, p1554 New York, Churchill Livingstone, 1990
- 15) Anthony BF, Concepcion NF : Group B streptococcus in a general hospital. *J Infect Dis* **132**:561, 1975
- 16) Facklam RR, Washington II JA : Chapter 29. Streptococcus and related catalase-negative gram-positive cocc : In Balows A et al(eds)

Manual of Clinical Microbiology, 5th ed, p 238,
Washington DC. American Society for Micro-
biology 1991

17) Baker CJ, Rench MA, Kasper DL : Response

to type III polysaccharide in women whose
infants have had invasive group B strepto-
coccal infection. N Engl J Med **322**:1857, 1990